

**The American Academy of Otolaryngology—
Head and Neck Surgery Foundation
(AAO-HNSF) Presents. . .**



**Chapter 10: How to Read A
Sinus CT Scan**

Daiichi Pharmaceutical Corporation, marketers and distributors of FLOXIN® Otic (ofloxacin otic) solution 0.3%, provided an educational grant for this book to be updated and distributed. The authors and editor had sole responsibility for the subject matter and editorial content.

Copyright Notice - All materials in this eBook are copyrighted by The American Academy of Otolaryngology—Head and Neck Surgery Foundation, One Prince Street, Alexandria, VA 22314-3357, and are strictly prohibited to be used for any purpose without prior express written authorization from The American Academy of Otolaryngology—Head and Neck Surgery Foundation. All Rights Reserved.

Print: First Edition 2001, Second Edition 2004

eBook Format: Second Edition, 2004

ISBN 978-1-56772-093-8



American Academy of Otolaryngology—Head and Neck Surgery Foundation
Working for the Best Ear, Nose, and Throat Care

One Prince Street | Alexandria, VA 22314-3357 | 1-703-836-4444 | Fax: 1-703-684-4288

© 2005 AAO-HNS

Chapter 10: How to Read A Sinus CT Scan

Editor: Mark K. Wax, MD. Authors: J. Gregory Staffel, MD; James C. Denneny III, MD; David E. Eibling, MD; Jonas T. Johnson, MD; Margaret A. Kenna, MD; Karen T. Pitman, MD; Clark A. Rosen, MD; Scott W. Thompson, MD; and Members of the Core Otolaryngology Education Faculty of the American Academy of Otolaryngology—Head and Neck Surgery Foundation

Dr. Gregory Staffel first authored this short introduction to otolaryngology for medical students at the University of Texas School for the Health Sciences in San Antonio in 1996. Written in conversational style, peppered with hints for learning (such as "read an hour a day"), and short enough to digest in one or two evenings, the book was a "hit" with medical students.

Dr. Staffel graciously donated his book to the American Academy of Otolaryngology—Head and Neck Surgery Foundation to be used as a basis for this primer. It has been revised, edited and is now in the second printing. This edition has undergone an extensive review, revision and updating. We believe that you, the reader, will find this book enjoyable and informative. We anticipate that it will whet your appetite for further learning in the discipline that we love and have found most intriguing. It should start your journey into otolaryngology, the field of Head and Neck Surgery.

Enjoy!

Mark K. Wax, MD

Editor: Primary Care Otolaryngology and Chair: AAO-HNSF Core Otolaryngology Education Faculty



Chapter Number 10: How to Read A CT Sinus Scan

The standard radiographic study for evaluation of sinus disease is the sinus CT scan performed in the **coronal plane** without intravenous contrast. As in other radiographic studies, a few principles go a long way.

- The 1st thing you look at is the **name**.
- The 2nd thing you look at is the **date**.
- The 3rd thing you look at is the **orientation—right versus left**.

The convention of designating sides for head and neck CT scans varies from institution to institution. You **can't assume** that if the film is positioned so you can read the name, that right is right and left is left. You must see an *R* or an *L*.

There are **4 radiographic densities: air, fat, water, and bone**.

Remember this very basic principle: When 2 structures of the same radiographic density are adjacent, the border between them is obscured. For example, if you can't see the right heart border on a **posterior-anterior (PA)** chest x-ray, the lung next to the heart (right middle lobe) has the same density (water density) as the heart. Likewise, pus or fluid in the sinus has the same density as thickening of the sinus mucosa.

The relative density of bone and other structures can be manipulated by the radiologist during viewing of the scan and printed, typically as either bone window (demonstrates clear bone detail) or soft tissue window (bones too bright, soft tissue easily visualized).



Chapter Number 10: How to Read A CT Sinus Scan

When you view CT scans, you must look at more than one image. If you don't know what a structure is, follow it through adjacent slices and you will usually be able to easily identify the anatomic structure that you are viewing.

Using a **systematic** way to review any imaging study in sequence is critical to avoid missing subtle abnormalities. Although the novice viewer routinely examines the maxillary sinuses first, you should systematically evaluate the orbits, orbital walls, **maxillary alveolus**, nasal septum, and sinuses. Remember that the ethmoid sinuses lie between the orbits, the maxillary sinus below the orbits, frontal above, and sphenoid behind. **You should carefully study every x-ray, MRI, or CT scan that you encounter**, so you can learn to recognize common anatomic variants and distinguish them from true pathology.

Here are 3 common anatomic variants encountered on coronal CT scans of the sinuses. See figures 10.1 to 10.3.

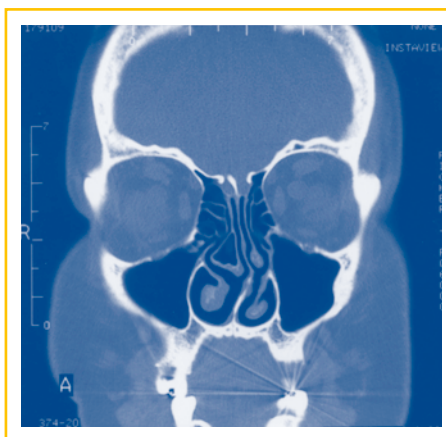


Figure 10.1.

CT scan of patient with deviated nasal septum and an ethmoid air cell within the middle turbinate. The surgical correction of nasal obstruction in this patient would require partial middle turbinectomy as well as correction of the deviated nasal septum.



Chapter Number 10: How to Read A CT Sinus Scan

1. Deviated nasal septum
2. Asymmetry of sinuses, including size, shape, presence of septas, etc.
3. An air cell within the middle turbinate (**concha bullosa**)

Abnormalities include fluid, mucosal thickening, bony fractures, cysts, and tumors. Look for these in figures 10.1 to 10.3.

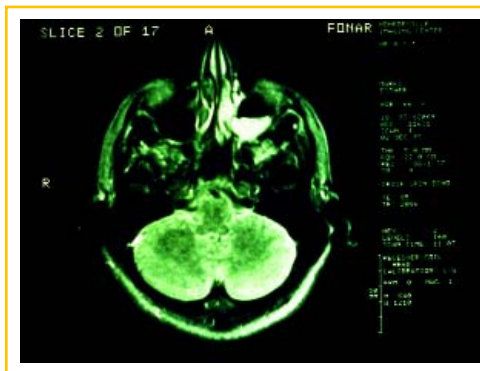


Figure 10.2.

Axial MRI scan of a patient with an air fluid level in his left maxillary sinus. A coronal CT scan is the preferred study for the evaluation of sinusitis; however, disease can also be readily seen on axial CT scans, often obtained for other reasons.



Chapter Number 10: How to Read A CT Sinus Scan

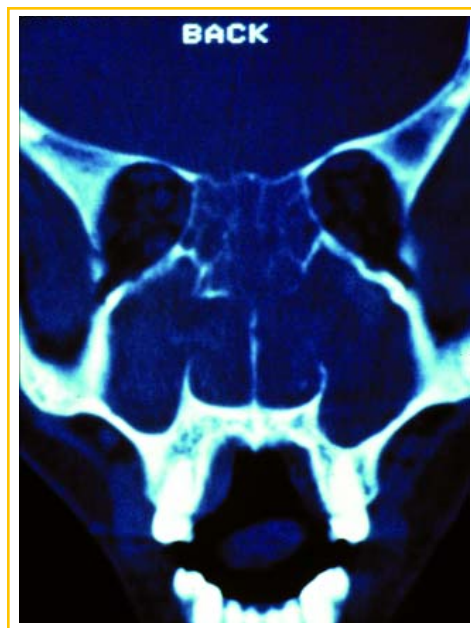

Figure 10.3.
Pansinusitis with polyps,
mucosal edema (or fluid-fill-
ing nose), ethmoid sinus,
and maxillary sinuses.

The Osteomeatal Complex:

The most significant area to examine in a patient with sinus complaints is the **osteomeatal complex (OMC)**. Coronal CT scans are used in the evaluation of sinus disease because they are best for visualizing the OMC. (However, axial CT scans are better for evaluation of the frontal sinuses). The OMC is the region through which the maxillary sinus drains in the nose. Edema obstructing the OMC will frequently lead to chronic maxillary sinusitis. This edema can be minimal, and is usually associated with clouding of the anterior ethmoid sinuses. The most



Chapter Number 10: How to Read A CT Sinus Scan

anterior ethmoid sinus—the **agger nasi cell**—is frequently clouded. Edema in this sinus may be associated with obstruction of the nasal frontal duct, which isn't well visualized on a CT scan, and results in frontal sinusitis.

In most instances, sinusitis is manifested by loss of aeration of multiple sinuses, usually involving both sides. This is water density, which may be swelling of the mucosa or polyps, fluid, or pus. Clouding of a single sinus (unilateral disease) is unusual and suggests an unusual cause, such as a tumor.

A sinus CT scan is not the first step in the evaluation of a patient with chronic sinusitis. Moreover, it is not necessary in the evaluation of all patients since the history and physical, particularly nasal endoscopy, will often identify the source of the pathology. Medical therapy, consisting of antibiotics, decongestants and topical steroids can be initiated based on clinical criteria. Should the patient fail this, or experience multiple episodes of sinusitis, then a sinus CT is essential for determining if there is an anatomic cause for the problem. If surgical intervention is being considered, then the CT scan provides valuable information, that is essential to the pre-operative plan.

It should be noted that all patients with nasal polyposis have chronic sinusitis, typically involving all sinuses. Unilateral nasal polyposis associated with unilateral sinusitis suggests tumor (most commonly, **inverted papilloma**, a benign growth caused by human papilloma virus [HPV]).

Mucosal thickening of the sinuses, particularly, the ethmoid sinuses, persists 6-8 weeks following a URI. Each of



Chapter Number 10: How to Read A CT Sinus Scan

us can expect to suffer 3 or 4 URIs per year, so random sinus CT scans performed on a population will demonstrate a high incidence of mucosal thickening. As a result, it's important that the CT scan be obtained after a patient has been maximally treated, and the disease is at its nadir or most improved state. On a CT scan it's impossible to differentiate between sinus clouding due to a common cold or due to bacterial sinusitis.

Remember: The best way to learn to look at any x-ray or imaging study is to carefully and systematically examine as many as possible.

Questions, Section #10

1. The 1st thing you should look at on any x-ray or CT scan is _____

2. The 2nd thing you should look at on any x-ray is _____

3. The 3rd thing you should look at on any x-ray (and especially on a CT scan) is _____

4. The 4 radiographic densities are _____
, _____
, _____,
and _____
5. When 2 structures of the same radiographic density are adjacent to each other, the border between them becomes _____



Chapter Number 10: How to Read A CT Sinus Scan

6. CT scans are typically printed in 1 of 2 densities, _____
density and _____
density.
7. CT scans are typically obtained in the coronal plane
because this view best demonstrates the _____
8. Common anatomic variants encountered on coronal CT
scans include _____
, _____
, _____
9. The key area that must be visualized on a sinus CT scan
is the _____

10. The best way to learn to look at an x-ray or other imaging
study is to carefully examine _____
in a systematic fashion.

Answers

1. The name
2. The date
3. Identification of right and left side
4. air, fat, water, bone
5. obscured
6. bone, soft tissue
7. osteomeatal complex (OMC)
8. Asymmetries of sinuses, deviated septum, concha bullosa



Chapter Number 10: How to Read A CT Sinus Scan

9. Osteomeatal complex (OMC)
10. As many as possible

More educational opportunities from the AAO-HNSF

The American Academy of Otolaryngology—Head and Neck Surgery Foundation offers many programs designed to keep you up-to-date without leaving your practice. Most activities offer Category 1 AMA/PRA credits. The Academy/Foundation also serves as a primary resource for otolaryngology/head and neck surgery activities and events, and serves as an online clearinghouse for patient education and specialty information.

Visit the Academy's website, <http://www.entnet.org> to learn more about these programs.

