

**The American Academy of Otolaryngology—
Head and Neck Surgery Foundation
(AAO-HNSF) Presents. . .**



Chapter 13: Salivary Gland Disease

Daiichi Pharmaceutical Corporation, marketers and distributors of FLOXIN® Otic (ofloxacin otic) solution 0.3%, provided an educational grant for this book to be updated and distributed. The authors and editor had sole responsibility for the subject matter and editorial content.

Copyright Notice - All materials in this eBook are copyrighted by The American Academy of Otolaryngology—Head and Neck Surgery Foundation, One Prince Street, Alexandria, VA 22314-3357, and are strictly prohibited to be used for any purpose without prior express written authorization from The American Academy of Otolaryngology—Head and Neck Surgery Foundation. All Rights Reserved.

Print: First Edition 2001, Second Edition 2004

eBook Format: Second Edition, 2005

ISBN 978-1-56772-093-8



American Academy of Otolaryngology—Head and Neck Surgery Foundation
Working for the Best Ear, Nose, and Throat Care
One Prince Street | Alexandria, VA 22314-3357 | 1-703-836-4444 | Fax: 1-703-684-4288

© 2005 AAO-HNS

Chapter 13: Salivary Gland Disease

Editor: Mark K. Wax, MD. Authors: J. Gregory Staffel, MD; James C. Denneny III, MD; David E. Eibling, MD; Jonas T. Johnson, MD; Margaret A. Kenna, MD; Karen T. Pitman, MD; Clark A. Rosen, MD; Scott W. Thompson, MD; and Members of the Core Otolaryngology Education Faculty of the American Academy of Otolaryngology—Head and Neck Surgery Foundation

Dr. Gregory Staffel first authored this short introduction to otolaryngology for medical students at the University of Texas School for the Health Sciences in San Antonio in 1996. Written in conversational style, peppered with hints for learning (such as "read an hour a day"), and short enough to digest in one or two evenings, the book was a "hit" with medical students.

Dr. Staffel graciously donated his book to the American Academy of Otolaryngology—Head and Neck Surgery Foundation to be used as a basis for this primer. It has been revised, edited and is now in the second printing. This edition has undergone an extensive review, revision and updating. We believe that you, the reader, will find this book enjoyable and informative. We anticipate that it will whet your appetite for further learning in the discipline that we love and have found most intriguing. It should start your journey into otolaryngology, the field of Head and Neck Surgery.

Enjoy!

Mark K. Wax, MD

Editor: Primary Care Otolaryngology and Chair: AAO-HNSF Core Otolaryngology Education Faculty



Chapter Number 13: Salivary Gland Disease

A discussion of salivary glands should consider both **the major (parotid, submandibular, and sublingual) glands** as well as the minor salivary glands. It is estimated that normal individuals have **750-1000 minor salivary glands located submucosally** from the lips to the trachea.

First, consider bilateral salivary gland enlargement. Viral infection, mumps, and human immunodeficiency virus (HIV) are the most common causes. In addition, patients with autoimmune disorders may have salivary dysfunction (dry mouth), dry eyes, and arthritis. (A cluster syndrome known as Sjögren's disease is frequently associated with parotid enlargement.) Diagnosis is based not only on history and physical, but also on **serologic studies (SSA and SSB)**.

Bacterial parotitis is almost always caused by *Staphylococcus aureus* and presents with all the classic signs and symptoms of infection, which include **tumor (swelling), dolor (pain), calor (heat), and rubor (redness)**. Often, pus can be expressed from **Stensen's duct**. A potential cause is a salivary stone, although frequently the etiology is dehydration. Patients with bacterial parotitis generally do well when treated with hydration and high-dose intravenous antibiotics. Local applications of heat and **sialagogues** such as lemon drops are ancillary measures. Occasionally, they will need to be drained surgically.



Chapter Number 13: Salivary Gland Disease

Salivary gland stones (sialolithiasis) most commonly occur in the submandibular duct. They are usually, although not always, **radio-opaque**. They can occasionally be palpated, usually at the orifice of the duct adjacent to the **lingual frenulum**. When present, they can cause obstruction leading to **stasis with possible secondary bacterial infection**. Treatment is removal of the stone. The duct must be incised because the stone can't be milked out distally. Some institutions are investigating treatment with lithotripsy.

Masses often present in the salivary glands and need to be evaluated by an otolaryngologist. We often perform fine needle aspiration to

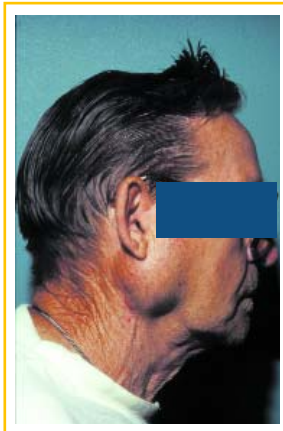


Figure 13.1.

Right parotid mass. Eighty-five percent of parotid neoplasms are benign, pleomorphic adenomas. However, 15% are malignant. Excisional biopsy requires superficial parotidectomy and facial nerve dissection. Open incisional biopsy is to be avoided except in unusual circumstances.

determine whether a malignancy is present. In general, any lump in front or below the ear must be considered a parotid mass until proven otherwise. The parotid gland has a large amount of lymphoid tissue, to which the lymphatics



Chapter Number 13: Salivary Gland Disease

on the side of the head drain. The most common metastatic lesion to the parotid gland is squamous cell carcinoma, generally a metastasis from a cancer of the skin on the side of the head. Malignant melanoma on the ear or scalp also metastasizes to the lymph nodes in the parotid. There are a variety of diagnostic studies that can be performed. Physical exam, radiographic imaging, and fine needle aspiration are adequate for diagnosing 95% of parotid masses. However, surgical removal with superficial parotidectomy remains the final diagnostic step of choice. Parotid masses are usually resected with a superficial parotidectomy for 2 reasons: First, it is quite easy to damage the facial nerve unless it is traced out from its origin throughout its entire course in the gland. Second, the most common kinds of salivary tumors tend to recur, and this procedure allows the surgeon to get a good margin of tissue around the tumor and achieve a decreased recurrence rate. It is important that masses in this region not be **enucleated** because injudicious excision can result in both facial nerve injury and recurrent tumor.

A Few Basic Principles about Salivary Gland Tumors:

The larger the salivary gland, the less likely the tumor is to be malignant. Thus, a mass in the parotid has only a 15% chance of being a malignant tumor, but a mass in the sublingual gland has a 75% chance of being a malignant tumor. Masses in the submandibular gland have about a



Chapter Number 13: Salivary Gland Disease

50/50 chance of being malignant. The most common benign tumor of the salivary glands is a **pleomorphic adenoma (mixed tumor)**. The most common malignant tumors are **adenoid cystic carcinoma** and **mucoepidermoid carcinoma**. Adenoid cystic carcinoma has a strong propensity to invade nerves and track along them. This is obviously significant because the 7th nerve tracks right through the parotid gland. The lingual and hypoglossal nerves are very near the submandibular gland.

Questions, Section #13

1. The 4 classic signs and symptoms of an infection are _____, _____, _____, and _____.
2. Bacterial parotitis is most commonly caused by _____.
3. A lump in front of or below the ear is to be considered a _____ until proven otherwise.
4. The most common tumor in the parotid gland is benign and is a _____.
5. The treatment of tumors of the parotid gland includes _____ with complete dissection of the facial nerve.



Chapter Number 13: Salivary Gland Disease

Answers

1. Pain (Dolor), Swelling (Tumor), Redness (Rubor), Heat (Calor)
2. S. Aureus
3. Parotid Mass
4. Pleomorphic Adenoma
5. Superficial Parotidectomy

More educational opportunities from the AAO-HNSF

The American Academy of Otolaryngology—Head and Neck Surgery Foundation offers many programs designed to keep you up-to-date without leaving your practice. Most activities offer Category 1 AMA/PRA credits. The Academy/Foundation also serves as a primary resource for otolaryngology/head and neck surgery activities and events, and serves as an online clearinghouse for patient education and specialty information.

Visit the Academy's website, <http://www.entnet.org> to learn more about these programs.

