

**The American Academy of Otolaryngology—  
Head and Neck Surgery Foundation  
(AAO-HNSF) Presents. . .**



## **Chapter 4: ENT Emergencies**

**Daiichi Pharmaceutical Corporation**, marketers and distributors of FLOXIN® Otic (ofloxacin otic) solution 0.3%, provided an educational grant for this book to be updated and distributed. The authors and editor had sole responsibility for the subject matter and editorial content.

**Copyright Notice** - All materials in this eBook are copyrighted by The American Academy of Otolaryngology—Head and Neck Surgery Foundation, One Prince Street, Alexandria, VA 22314-3357, and are strictly prohibited to be used for any purpose without prior express written authorization from The American Academy of Otolaryngology—Head and Neck Surgery Foundation. All Rights Reserved.

Print: First Edition 2001, Second Edition 2004

eBook Format: Second Edition, 2005

ISBN 978-1-56772-093-8



American Academy of Otolaryngology—Head and Neck Surgery Foundation  
*Working for the Best Ear, Nose, and Throat Care*

One Prince Street | Alexandria, VA 22314-3357 | 1-703-836-4444 | Fax: 1-703-684-4288

© 2005 AAO-HNS

## Chapter 4: ENT Emergencies

**Editor: Mark K. Wax, MD. Authors: J. Gregory Staffel, MD; James C. Denny III, MD; David E. Eibling, MD; Jonas T. Johnson, MD; Margaret A. Kenna, MD; Karen T. Pitman, MD; Clark A. Rosen, MD; Scott W. Thompson, MD; and Members of the Core Otolaryngology Education Faculty of the American Academy of Otolaryngology—Head and Neck Surgery Foundation**

---

Dr. Gregory Staffel first authored this short introduction to otolaryngology for medical students at the University of Texas School for the Health Sciences in San Antonio in 1996. Written in conversational style, peppered with hints for learning (such as "read an hour a day"), and short enough to digest in one or two evenings, the book was a "hit" with medical students.

Dr. Staffel graciously donated his book to the American Academy of Otolaryngology—Head and Neck Surgery Foundation to be used as a basis for this primer. It has been revised, edited and is now in the second printing. This edition has undergone an extensive review, revision and updating. We believe that you, the reader, will find this book enjoyable and informative. We anticipate that it will whet your appetite for further learning in the discipline that we love and have found most intriguing. It should start your journey into otolaryngology, the field of Head and Neck Surgery.

Enjoy!

Mark K. Wax, MD

Editor: Primary Care Otolaryngology and Chair: AAO-HNSF Core Otolaryngology Education Faculty



## Chapter Number 4: ENT Emergencies

### Airway:

**Airway emergencies** are uncommon, but devastating when they do happen. Whether the patient lives or dies—or worse, lives for years in a coma—depends on the ability of those caring for him or her to **recognize, access, and manage** the airway. ENT physicians are experts in airway management, but often not nearby when needed. The advanced trauma life support (ATLS) course you probably have taken or will take emphasizes management of airway emergencies. Predicting when difficulty will occur and being able to manage the difficult airway without it becoming an emergency is an even more valuable skill. Later, this chapter will list 3 types of airway difficulties that you might encounter.

A good rule of thumb about a **tracheotomy** is if you think about it, you probably should do it. It's easier to revise a scar on the neck than to bring the dead back to life.

If you need an immediate surgical airway, then a **cricothyrotomy** is the preferred procedure if you aren't an experienced surgeon. It is easier and less bloody. Please remember the airway is best found in the neck by **palpation**, not inspection. Take a moment and palpate your own **cricothyroid membrane**, immediately below your **thyroid cartilage**. To do an emergency **cricothyrotomy** you need only a knife. Feel the space, cut down and stick your finger in the hole, feel, and cut again, and again until you are in the airway. Don't worry



## Chapter Number 4: ENT Emergencies

about bleeding. Place an **endotracheal tube** in the hole (again, by feel). Be sure not to push it past the **carina**. By this time, you will be shaking like a leaf—it's OK to let someone else squeeze the bag. Pressure with a dressing will address most bleeding. Occasionally, you might need to use some sutures to stop the bleeding.

Cholena Atresia is a congenital disorder where the nasal cholena is accluded by soft tissue, bone, or a combination of both. When unilateral it presents with unilateral mucopurulent discharge. When bilateral, the neonate is unable to breathe. Since newborns are obligate nasal breathers, establishing an airway is an acute otolaryngologic emergency. This can be done in the operating room.

### **Difficult Intubations:**

**Anatomic characteristics of the upper airway** in some patients can result in difficult **laryngeal exposure**. Patients with **macroglossia** or **congenital micrognathia**, such as **Pierre Robin syndrome**, are examples. More commonly encountered is the young, muscular, overweight man with a short neck. Anesthesiologists are trained to recognize and manage the airway in these patients, but everyone caring for them must be aware of the potential difficulty. The need for a surgical airway in these patients often represents a failure of recognition and planning.



**Chapter Number 4: ENT Emergencies****Ludwig's Angina and Deep Neck Infections:**

**Ludwig's angina** is an infection in the floor of the mouth that causes the tongue to be pushed up and back, eventually obstructing the patient's airway. Treatment requires **incision and drainage of the abscess**. The most common cause of this

abscess is infection in the teeth. The mylohyoid line on the inner aspect of the body of the **mandible** descends **on a slant** such that the tips of the roots of the **2nd and 3rd molars** are behind and below this line.

Therefore, if these teeth are abscessed, the pus will go into the **sub-mandibular space** and may spread to the **parapharyngeal space**. These patients present with unilateral neck swelling, redness, pain, and fever. Usually, the infected tooth isn't painful. Treatment is incision and drainage over the submandibular swelling. Antibiotic coverage should include **oral cavity anaerobes**. If, however, the tooth roots are above the mylohyoid line, as they are from the

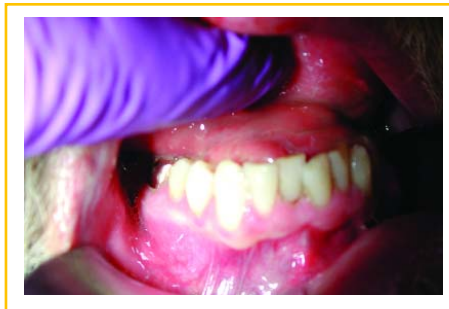

Figure 4.1.

This photograph depicts a gentleman with severe Ludwig's angina. Notice the swollen floor of the mouth and the arched protruding tongue obstructing the airway.



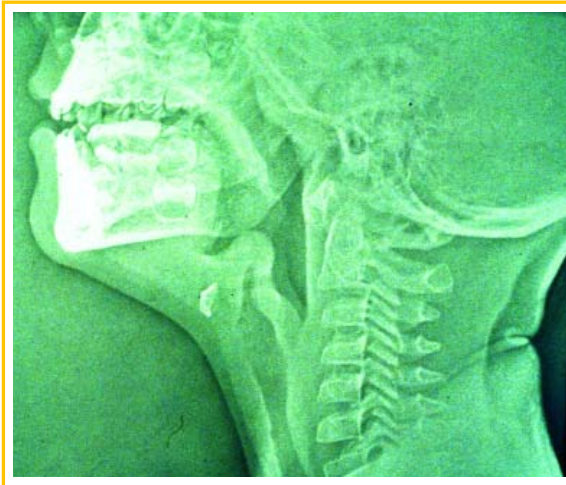**Chapter Number 4: ENT Emergencies**

**1st molar** forward, the infection will enter the **sublingual space**. This is above and in front of the mylohyoid and will cause the tongue to be pushed up and back, as previously noted. These patients usually will require tracheotomy, as the infection can progress quite rapidly, producing airway obstruction. The firm tongue swelling prevents standard laryngeal exposure with a **laryngoscope blade**, so **intubation** should not be attempted. Even if there is no airway obstruction on presentation, it may develop after you operate and drain the pus. This results because there is often **postoperative** swelling, which can be worse than the swelling on initial presentation.

**Acute Supraglottic Swelling:**

See chapter 17, Pediatric Otolaryngology.

This can occur as a result of infections (**epiglottitis**). It was once common in children, but is now rare because of the widespread utilization of vaccination against



**Figure 4.2.**

Lateral neck, soft tissue x-ray of a child with acute epiglottitis. Note the lack of definition of the epiglottis, often referred to as a "thumb sign."



## Chapter Number 4: ENT Emergencies

***Haemophilus influenzae***. Early recognition of the constellation of noisy breathing, high fever, drooling, and the characteristic posture, sitting upright with the jaw thrust forward, may be lifesaving. Epiglottic or supraglottic edema prevents swallowing. Relaxation and an upright position keeps the airway open. These children must not be examined until after the airway is secured.

**Angioneurotic edema**, either familial or due to a **functional or quantitative deficiency of C1-esterase inhibitor**, can also result in dramatic swelling of the tongue, pharyngeal tissues, and the supraglottic airway. Swelling can progress rapidly, and oral intubation may quickly become impossible, urgently requiring a surgical airway.

### ***Peritonsillar Abscess:***

This is a collection of purulence in the space between the tonsil and the pharyngeal constrictor. Typically, the patient will have had an untreated sore throat for several days which has now gotten worse on one side. The hallmark signs of peritonsillar abscess are fullness of the anterior tonsillar pillar, uvular deviation away from the side of the abscess a “hot potato” voice and in some patients trismus (difficulty opening the jaws). Treatment includes drainage or aspiration, adequate pain control and antibiotics. Tonsillectomy may be indicated depending on the patients past history.



**Chapter Number 4: ENT Emergencies****Foreign Bodies:**

Foreign bodies can present as airway emergencies. Usually, however, by the time the patient gets to the emergency room, the foreign body in the airway has been expelled (often by the **Heimlich maneuver**) or else the patient is no longer able to be resuscitated. Foreign bodies in the **pharynx** or **laryngeal inlet** can often be extracted by **Magill forceps** after laryngeal exposure with a standard laryngoscope.

The patient will usually vomit, so

**suction is mandatory. Bronchial foreign bodies** will require operative **bronchoscopy** for removal. Occasionally a tracheotomy will be required, such as for a patient who has aspirated a partial denture with imbedded hooks.

Children often aspirate peanuts, small toys, etc., into their bronchi. Occasionally these patients present as airway emergencies, although they more typically present with **unexplained cough or pneumonia**. Chevalier Jackson, the famous **bronchoscopist**, has noted, "All that wheezes is not asthma"—in other words, always remember to think of foreign body aspiration when a pediatric patient presents

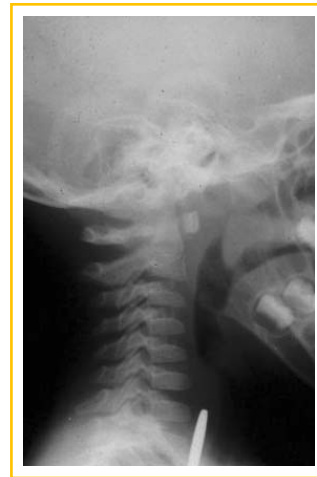

Figure 4.3.

A coin is seen here trapped in the patient's esophagus.



**Chapter Number 4: ENT Emergencies**

with unexplained cough or pneumonia. If a **ball-valve obstruction** results, **hyperinflation of the obstructed lobe or segment** can occur. This is easier to visualize on **inspiration-expiration films**.

**Mucormycosis:**

This is a **fungal infection** occurring in **immunocompromised** hosts. Typically it appears in patients receiving bone marrow transplantation or chemotherapy. It is a devastating disease, with a significant associated mortality. *Mucor* is a ubiquitous fungus that can become **invasive** in susceptible patients, classically diabetics with **poor glucose regulation** who became **acidotic**. If there is any other **system failure** (e.g., **renal failure**), mortality goes up significantly. The fungus grows in the blood vessels, causing **thrombosis** and **distal ischemia** and ultimately, tissue necrosis. This also leads to an **acid environment** in which the fungus thrives. The primary symptom is facial pain, and physical exam shows **black turbinates** due to **necrosis of the mucosa**. Diagnosis is made by **biopsy**. **Acutely branching nonseptate hyphae** are seen microscopically. Usually the infection starts in the sinuses but rapidly spreads to the **nose, eye, and palate**, and up the **optic nerve** to the **brain**.

Treatment is immediate correction of the **acidosis** and **metabolic stabilization** to the point where **general anesthesia** will be safely tolerated (usually for patients in



**Chapter Number 4: ENT Emergencies**

**diabetic ketoacidosis [DKA]** who need several hours for rehydration, etc.). Then, wide **debridement**, usually consisting of a **medial maxillectomy** but often extending to a **radical maxillectomy** and **orbital exenteration** (removal of the eye and part of the hard palate) or even beyond.

**Amphotericin B** is the drug of choice. Many patients have renal failure, which precludes adequate dosing. Newer **lyso-somal forms** of amphotericin B have been shown to salvage these patients by permitting higher doses of drugs. If the underlying immunologic problem can't be arrested, survival is unlikely. In patients who are neutropenic, unless the white blood cell count improves, there is no chance for survival.

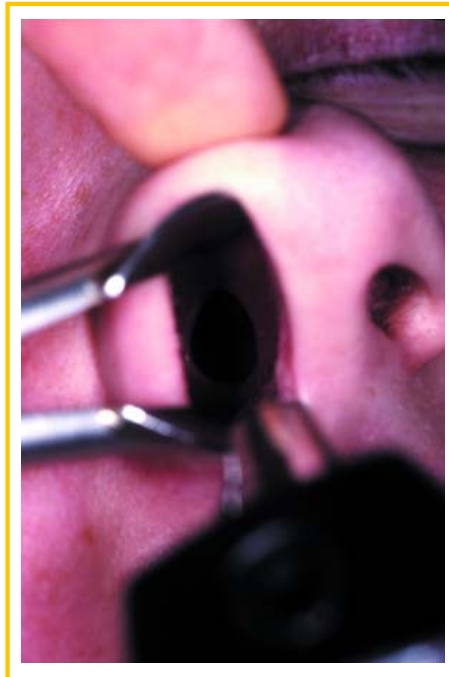


Figure 4.4.

Septal perforation may be secondary to trauma, cocaine (or even Afrin) abuse, or prior surgery. Epistaxis commonly accompanies this condition and may be problematic.



## Chapter Number 4: ENT Emergencies

### Acute Frontal or Sphenoid Sinusitis, and Cavernous Sinus Thrombosis:

See chapter 9, Rhinology, Nasal Obstruction and Sinusitis.

### Epistaxis:

**Epistaxis** is common and occurs in all people at some time. If the condition is severe or persistent, these people become patients. The most common bleed is from the anterior part of the septum. This area has many blood vessels and is called **Kiesselbach's plexus**. In children, these nosebleeds should be treated with **oxymetazoline or phenylephrine** nose spray and digital **pressure for 5-10 minutes**. It is important for patients to look at the clock while applying the pressure: Just 30 seconds can seem like an hour in such a situation, and they may release the pressure too soon (which allows new blood to wash out the clot that was forming). The most common initiating event for these kinds of nosebleeds is **digital trauma** from a fingernail. Trim children's fingernails, and adults should be reminded to refrain. (These patients can even pick their nose during their sleep.) Another consideration may be an **occult bleeding disorder**; therefore, **adequate coagulation parameters** should be studied if the patient continues to have problems.



**Chapter Number 4: ENT Emergencies**

**Recurrent nosebleeds in a teenager** can be especially problematic. **Cocaine abuse** is always a possibility and must be considered. Very often in these cases, there will actually be a **perforation in the nasal septum**. Bleeding from the back of the nose in an adolescent male is considered to be a **juvenile nasopharyngeal angiofibroma** until proven otherwise. These patients also frequently have nasal obstruction. Diagnosis is made by physical examination with **nasal endoscopy**.

Some adult patients, often with HTN and **arthritis** (for which they are taking **aspirin**), have frequent nosebleeds. Whenever they present to the emergency room, they have a **significant elevation of blood pressure**, which isn't helped by the excitement of seeing a brisk nosebleed. Treatment for these patients is **topical vasoconstriction** (oxymetazoline, phenylephrine). This almost always stops the bleeding. When the oxymetazoline-soaked pledgets are removed, a small red spot, which represents the source of the bleeding, can often be seen on the septum. Often, if such a bleeding source is seen, it can be **cauterized** with either **electric cautery** or **chemical cauterization with silver nitrate**. Nasal endoscopes permit identification of the bleeding site, even if it isn't immediately seen on the anterior septum. These patients should also be treated with medication to lower their blood pressure. The **diastolic pressure** has to be reduced



## Chapter Number 4: ENT Emergencies

**below 90 mm Hg.** Many patients can then go home, using oxymetazoline for a few days. Furthermore, methylcellulose coated with antibiotic ointment can be placed into the nose to **prevent further trauma and allow the mucosal surfaces to heal.** This is usually left in place for 3-5 days. Sometimes the bleeding can't be completely stopped, and **packing** is then used as a **pressure method** of stopping the bleeding.

If the bleeding is coming from the **posterior aspect of the nose**, then a posterior pack may need to be placed. An alternative is to place any one of various commercially available balloons to stop the nosebleed. Patients who undergo anterior packing on one side may go home; however, if **bilateral nasal packing** is used or a posterior pack is placed, patients will need to be admitted to the hospital and carefully watched, because they can suffer from **hypoventilation** and **oxygen desaturation.** In general, the packing is left in place for 3-5 days and removed. During this time prophylactic oral or parenteral antibiotics should be administered to keep the smell down and decrease the infectious complications. If the patient rebleeds, the packing is replaced and **arterial ligation, endoscopic cautery, or embolization can be considered.**

As always, these patients should be worked up for **bleeding disorders.** A patient with a severe nosebleed can develop hypovolemia, or significant anemia, if fluid is



## Chapter Number 4: ENT Emergencies

being replaced. These conditions necessitate **increased cardiac output**, which can lead to ischemia or **infarction of the heart** itself.

### **Necrotizing Otitis Externa:**

**"Malignant" otitis externa** is an old name for what should more appropriately be called **necrotizing otitis externa**. This is a **severe infection of the external auditory canal**, which is usually caused by ***Pseudomonas* organisms**. This infection spreads to the **temporal bone** and as such is really an **osteomyelitis** of the temporal bone. This can extend readily to the base of the skull, leading to fatal complications if it isn't adequately treated. This disease **occurs most commonly in diabetics**, and any patient with otitis externa should be asked about the possibility of diabetes. It can be caused by irrigating wax from the ears of diabetic patients. Usually these patients are elderly, and they present with **pain on the infected side and granulation tissue at the area of the bony cartilaginous junction in the external auditory canal**. To diagnose an actual infection in the bone (which is the sine qua non of this disease), a **computed tomography (CT)** scan of the bone, with bone windows, is obtained. A **technetium bone scan** will also demonstrate a "hot spot," but is too sensitive to discriminate between severe otitis externa and true osteomyelitis.



## Chapter Number 4: ENT Emergencies

The standard therapy is **daily debridement of the external auditory canal, antipseudomonal ear drops**, and intravenous antipseudomonal antibiotics. **Quinolones** are the drugs of choice because they are active against Pseudomonas organisms.

### Sudden Sensorineural Hearing Loss:

Sudden sensorineural hearing loss may occur for a variety of reasons, and most often the reason is unclear, but these patients recover their hearing much better if they are given high dose steroids (60 mg. of prednisone) tapered over about 3 weeks. The earlier the treatment starts, the better the prognosis, therefore **start the steroids immediately**, even if they can't be seen by an otolaryngologist for a day or so. Some evidence suggests that antivirals may also help slightly, so the patients are also given famcyclovir 500 mg. three times per day for 10 days. Recovery of some form can be expected in 2 out of 3 patients.



## Chapter Number 4: ENT Emergencies

### Questions, Section #4

1. Abscessed teeth can rupture through the medial mandibular cortex into the sublingual space. This can cause the tongue to be pushed up and back. The biggest danger in this is loss of \_\_\_\_\_
2. The easiest way to ensure that the airway isn't lost in this situation is to perform a \_\_\_\_\_
3. Immunocompromised patients, especially diabetics, can get a devastating fungal infection of the sinuses called \_\_\_\_\_
4. When a frontal sinus air fluid level is seen on an x-ray, there is danger that the infection can readily spread through the veins that traverse the foramina of Brechet in the posterior wall and spread into the \_\_\_\_\_
5. Necrotizing otitis externa is a *Pseudomonas* infection of the \_\_\_\_\_, which can lead to fatal complications.
6. Often, \_\_\_\_\_ tissue is seen at the junction of the bony-cartilaginous junction in the external auditory canal in patients with necrotizing otitis externa.
7. The most common cause of a nosebleed in children is injury to vessels in \_\_\_\_\_
8. A posterior nosebleed in an adolescent male is considered to be a \_\_\_\_\_ until proven otherwise.



**Chapter Number 4: ENT Emergencies**

9. Two topical vasoconstrictors often used in the nose are \_\_\_\_\_ and \_\_\_\_\_
10. In deciding between conflicting responsibilities, \_\_\_\_\_ should always be your first priority.

Answers

1. Airway
2. Tracheotomy
3. Mucormycosis
4. Meninges
5. Skull Base or Temporal Bone
6. Granulation
7. Kiesselbach's Plexus
8. Juvenile Nasopharyngeal Angiofibroma
9. Oxymetazoline, Phenylephrine
10. The care of the patient



## More educational opportunities from the AAO-HNSF

The American Academy of Otolaryngology—Head and Neck Surgery Foundation offers many programs designed to keep you up-to-date without leaving your practice. Most activities offer Category 1 AMA/PRA credits. The Academy/Foundation also serves as a primary resource for otolaryngology/head and neck surgery activities and events, and serves as an online clearinghouse for patient education and specialty information.

Visit the Academy's website, <http://www.entnet.org> to learn more about these programs.

