

# Resident Manual of Trauma to the Face, Head, and Neck

First Edition



AMERICAN ACADEMY OF  
OTOLARYNGOLOGY-  
HEAD AND NECK SURGERY

F O U N D A T I O N

©2012 All materials in this eBook are copyrighted by the American Academy of Otolaryngology—Head and Neck Surgery Foundation, 1650 Diagonal Road, Alexandria, VA 22314-2857, and are strictly prohibited to be used for any purpose without prior express written authorizations from the American Academy of Otolaryngology—Head and Neck Surgery Foundation. All rights reserved.

For more information, visit our website at [www.entnet.org](http://www.entnet.org).

eBook Format: First Edition 2012.

ISBN: 978-0-615-64912-2

# Contents

<b>Preface</b> .....	16
<b>Acknowledgments</b> .....	18
<b>Resident Trauma Manual Authors</b> .....	19
<b>Chapter 1: Patient Assessment</b> .....	21
<b>I. Diagnostic Evaluations</b> .....	21
A. Full-Body Trauma Assessment .....	21
B. History .....	22
C. Head and Neck Examination.....	24
1. Upper Third .....	24
2. Middle Third.....	24
3. Lower Third.....	26
4. Otoscopy.....	26
5. Neurologic Examination.....	27
D. Infection Control .....	27
E. Imaging Studies.....	27
F. Laboratory Tests .....	28
G. Digital Photographs.....	28
<b>II. References</b> .....	28
<b>Chapter 2: General Principles in Treating Facial, Head, and Neck Trauma</b> .....	30
<b>I. Special Mechanisms of Injury</b> .....	30
A. Gunshot Wounds.....	30
1. Ballistic Sequences.....	30
2. Main Factors Affecting Projectile Strike.....	30
B. Blast Injuries.....	32
1. Mechanisms for Causing and Types of Blast Injury .....	32
<b>II. Traumatic Brain Injuries</b> .....	34
A. Closed Head Injuries.....	34
1. Classification by Presenting Signs and Symptoms .....	34
2. Classification by CT Findings.....	34
3. Classification by Anatomy .....	34
4. Initial Assessment .....	34
B. Penetrating Head Injury .....	35
C. Cautionary Notes on the Acute Management of Patients with Head Injury .....	35

<b>III. Principles of Soft Tissue Wound Management</b>	36
A. Initial Wound Management	36
1. Cleansing	36
2. Debridement	36
3. Passive Drains	36
4. IV Antibiotics and Tetanus Toxoid	36
5. Inspection and Documentation	36
B. Primary versus Delayed Closure	36
C. Laceration Care after Repair	36
1. Closing Clean Wounds Primarily	36
2. Avoiding Additional Incisions	37
3. Reconstructing the Facial Framework Early	37
D. Bite Wounds	37
<b>IV. Principles of Plating</b>	38
A. Reconstructive Goals	38
B. Technical Objectives	38
1. Stability at Each Fracture Site	38
2. Three-Point Fixation of Mobile Segments	38
3. Bone Fragment Contact	38
C. Plating Systems	38
1. Metal Plating	39
2. Resorbable Plating	39
<b>V. References and Resources</b>	39

### **Chapter 3: Upper Facial Trauma**

<b>I. Frontal Sinus and Anterior Skull Base Trauma</b>	41
A. Introduction	41
B. Classification	42
C. Presentation	43
1. Anterior Wall Fractures	43
2. Posterior Wall Fractures	43
3. Frontonasal Duct Fractures	44
4. Corner Fractures	44
5. Through-and-Through Fractures	44
D. Management	45
1. Anterior Wall Fractures	45
2. Posterior Wall Fractures	46
3. Frontonasal Duct Fractures	47
4. Through-and-Through Fractures	48
<b>II. Naso-orbital-ethmoid Fractures</b>	51
A. Anatomic Structures of the NOE Complex	52
B. Indications of Injury to the NOE Complex Structures	53



1. Symptoms (Subjective).....	53
2. Signs (Objective).....	53
C. Classification of Medial Canthal Tendon Injuries.....	57
D. Lacrimal System Injuries.....	57
1. Primary Jones Dye Test.....	58
2. Secondary Jones Dye Test.....	58
E. Isolated Orbital Fractures.....	59
F. Diagnostic Evaluations.....	59
1. Full-Body Trauma Assessment.....	59
2. Head and Neck Examination.....	59
3. Ophthalmological Evaluation.....	59
4. Inspection of the Nasal Interior.....	60
5. Interpupillary and Intercanthal Distance Measurements.....	60
6. Imaging Studies.....	60
7. Forced Duction Testing.....	60
8. Plain Radiographs of the Face.....	61
9. Digital Photographs.....	61
G. Surgical Management.....	62
1. Indications for Surgery.....	62
2. Timing of Surgical Procedures.....	62
3. Surgical Exposure Options.....	62
4. Reconstructive Options.....	66
H. Prevention and Management of Complications.....	69
1. Indications for Antibiotics.....	69
2. CSF Leaks.....	69
3. Corneal Injuries.....	69
4. Lower Lid Abnormalities.....	70
5. Persistent Telecanthus.....	70
6. Failure to Correct Medial Orbital Tissue Entrapment.....	70
7. Persistent Diplopia.....	71
8. Anosmia.....	71
9. Frontoethmoid Sinusitis.....	71
<b>III. Summary and Conclusion.....</b>	<b>72</b>
A. Frontal Sinus and Anterior Skull Base Trauma.....	72
B. NOE Fractures.....	72
<b>IV. References.....</b>	<b>73</b>
<b>V. Recommended Reading.....</b>	<b>73</b>

<b>Chapter 4: Midfacial Trauma</b> .....	74
<b>I. Maxillary and Orbital (and Zygomatic) Fractures</b> .....	74
A. Dental Terminology.....	74
1. Maxillae and Mandible.....	74
B. Midfacial Anatomy.....	75
1. Strong Areas of the Facial Bone .....	76
2. Maxillae.....	76
3. Nasal Bones .....	77
4. Orbits .....	77
C. Midfacial Fractures.....	78
1. Le Fort Series of Fractures .....	78
2. Zygomatic Fractures .....	80
3. Orbital Fractures .....	80
D. Diagnosis of Midfacial Trauma.....	80
1. Assessment of Vision .....	80
2. Assessment of Other Nerves .....	81
3. Le Fort Fractures .....	81
4. CT Scan .....	81
E. Considerations for Repair of Midfacial Trauma .....	81
1. Orbital Fractures .....	81
2. Zygomatic Fractures .....	82
3. Maxillary Fractures.....	82
F. Approaches to Repairing Midfacial Trauma .....	82
1. Orbital Fractures .....	82
2. Zygomatic Fractures .....	86
3. Maxillary Fractures.....	87
G. Fracture Reduction and Repair .....	87
1. Zygomatic Fractures .....	87
2. Maxillary and Extended Maxillary Fractures .....	88
3. Blowout Fractures of the Orbits.....	89
H. Complications.....	89
1. Inadequate Reduction .....	89
2. Imprecise Reconstruction of the Orbit.....	89
3. Globe Malposition .....	89
4. Eyelid Malpositions .....	90
5. Reduced Vision and Blindness.....	90
6. Scars and Hair Loss .....	90
7. Nonunion .....	90
8. Dental Injury .....	90
9. Cerebrospinal Fluid Leaks.....	90
<b>II. Nasal Bone Fractures</b> .....	91
A. Introduction.....	91

B. Review of Anatomy .....	91
1. Bony: Paired Nasal Bones .....	91
2. Cartilaginous.....	91
3. Neurovascular.....	92
4. Conformational .....	92
5. Orientational Terminology .....	92
C. Evaluation and Diagnosis.....	93
1. History of Trauma .....	93
2. Nasal Deformity, Causally Related to Occasion of Trauma .....	93
3. Simple Lateral Deviation.....	93
4. Complex Deviation (“Twisted Nose”) .....	93
5. Splaying/Widening of Nose .....	94
6. Widening of Nasal Root, or Telecanthus .....	94
7. Nasal Function Alteration, Causally Related to Occasion of Trauma .....	94
8. Examination.....	94
9. Radiographic Studies, Including CT .....	94
10. Photography.....	95
D. Management.....	95
1. Closed Reduction.....	95
2. Open Reduction .....	96
E. General Considerations.....	97
1. Internal Fixation .....	97
2. Nasal Packing .....	97
3. Lacerations of the Nasal Skin .....	97
4. Septal Hematomas .....	97
5. Lacerations of the Nasal Lining .....	97
6. Perioperative Antibiotics .....	97
7. Splints .....	97
8. Rest, Elevation, Ice, and Anodynes.....	98
9. Postreduction Photos.....	98
F. Complications.....	98
G. Summary.....	99
<b>III. References .....</b>	<b>99</b>

## **Chapter 5: Mandibular Trauma**

<b>I. Mandibular Bone, Muscle, and TMJ Anatomy .....</b>	<b>100</b>
A. Mandibular Bone.....	100
B. Mandibular Muscle.....	100
C. Temporomandibular Joint.....	101

<b>II. Indications of the Presence of Mandibular Fracture</b>	101
A. Symptoms (Subjective)	101
B. Signs (Objective)	101
1. Deformity	101
2. Pain	102
3. Tooth and Bone Fragment Hypermobility	102
4. Bleeding, Hematoma, and Swelling	102
5. Crepitus	102
6. Restricted Function	102
7. Sensory Disturbances	102
<b>III. Classification of Mandibular Fractures</b>	102
A. Condyle Fractures	104
1. Condylar Head or Intracapsular Fractures	105
2. Condylar Neck and Subcondylar Fractures	105
B. Fractures of the Mandibular Angle	106
C. Fractures of the Mandibular Body	106
D. Fractures of the Symphysis and Parasymphysis	106
E. Fractures of the Ramus	107
F. Fractures of the Coronoid	107
G. Alveolar (Dentoalveolar) Fractures	107
H. Edentulous Fractures	108
1. Closed Reduction	108
2. Open Reduction	108
<b>IV. Diagnostic Evaluations</b>	108
A. Full-Body Trauma Assessment	108
B. Trauma History	108
C. Head and Neck Examination	110
D. Oral Examination	110
E. Occlusal Evaluation	110
1. Angle Class I Occlusion	110
2. Angle Class II Occlusion	111
3. Angle Class III Occlusion	111
4. Maximum Intercuspatation	111
5. Wear Facets	111
6. Overjet and Overbite	112
7. Skeletal Malocclusion	112
8. Dental Malocclusion	112
9. Mesial	112
10. Distal	112
11. Crossbite	112
12. Centric Occlusion and Centric Relation	112
13. Vertical Dimension of Occlusion	112
14. Identification of Adult and Pediatric Teeth	113

F. Imaging Studies.....	113
1. Mandible Series.....	113
2. Panorex.....	113
3. CT Scan.....	114
4. MRI Scan.....	114
5. Occlusal View.....	114
6. Periapical Radiographs.....	114
<b>V. Surgical Management .....</b>	<b>115</b>
A. Indications for Surgery .....	115
1. Indications for Closed Reduction.....	115
2. Contraindications to Closed Reduction .....	116
3. Indications for Open Reduction .....	116
B. Timing of Surgical Procedures.....	116
C. Surgical Exposure Options .....	116
1. Closed Reduction.....	118
2. Open Reduction .....	120
3. Osteosynthesis.....	122
4. Surgical Treatment .....	123
<b>VI. Prevention and Management of Complications.....</b>	<b>126</b>
A. Infection Prevention .....	126
B. Teeth in Line of Fracture.....	126
C. Delayed Union and Nonunion .....	126
D. Malunion.....	127
E. TMJ Ankylosis.....	127
F. Trigeminal (Fifth) Nerve Injury.....	127
G. Facial (Seventh) Nerve Injury .....	127
H. Fixation Failure.....	128
<b>VII. Pediatric Mandibular Fractures.....</b>	<b>128</b>
A. Pediatric Dental and Skeletal Anatomy .....	128
B. Frequency of Pediatric Mandibular Fractures.....	129
C. Management of Pediatric Mandibular Fractures.....	129
1. Imaging Pediatric Mandibular Fractures.....	129
2. Treating Pediatric Mandibular Fractures.....	130
3. Treating Pediatric Condylar Fractures .....	131
4. Treating Pediatric Body and Angle Fractures.....	132
5. Treating Pediatric Dentoalveolar Fractures.....	132
<b>VIII. References.....</b>	<b>132</b>
<b>Chapter 6: Temporal Bone Trauma .....</b>	<b>140</b>
<b>I. Anatomic Structures of the Temporal Bone .....</b>	<b>141</b>
A. Components and Important Relationships of the Temporal Bone.....	141

B. Facial Nerve Characteristics .....	142
<b>II. Indications of Temporal Bone Injury .....</b>	<b>143</b>
A. Subjective Symptoms .....	143
B. Objective Signs.....	143
1. Hearing Loss.....	143
2. Hemotympanum .....	143
3. Otorrhea.....	143
4. Imbalance .....	144
5. Facial Nerve Dysfunction (Paralysis or Paresis) .....	144
6. Auricular Ecchymosis, Lacerations, and Hematomas ....	144
<b>III. Classification of Temporal Bone Fractures .....</b>	<b>144</b>
A. Longitudinal versus Transverse Classification.....	144
1. Longitudinal injuries .....	145
2. Transverse Fractures .....	146
B. Otic Capsule-Sparing versus Otic Capsule-Involving Classification.....	146
<b>IV. Diagnostic Evaluations .....</b>	<b>147</b>
A. Full-Body Trauma Assessment .....	147
B. Head and Neck Examination.....	147
C. Hearing Evaluation .....	147
1. Weber Exam.....	147
2. Rinne Testing.....	148
3. Combined Weber, Rinne, and Audiogram Testing .....	148
D. Vestibular Evaluation .....	148
E. Facial Nerve Evaluation .....	149
1. Sunderland Classification of Nerve Injury .....	150
2. Evaluating Facial Paralysis and Paresis.....	150
3. Evaluation with Electromyography and Electroneuronography .....	151
F. Evaluation of Cerebrospinal Fluid Leaks .....	153
1. Diagnostic Tests.....	153
G. Imaging Studies.....	153
<b>V. Surgical Management .....</b>	<b>155</b>
A. Indications for Surgery .....	155
B. Timing of Surgical Procedures.....	155
C. Surgical Exposure Options .....	155
1. General Requirements for Surgery of the Temporal Bone.....	155
2. Primary Surgical Objectives and Indications in Temporal Bone Fractures .....	155
3. Surgical Approaches for Accessing Injuries .....	156
D. Reconstructive Options.....	158

1. Tympanic Membrane Repair.....	158
2. Ossicular Reconstruction.....	158
3. Facial Nerve Repair.....	159
<b>VI. Prevention and Management of Complications.....</b>	<b>159</b>
A. Indications for Antibiotics.....	159
B. Hearing Loss.....	160
C. Facial Nerve Injury.....	160
D. CSF Leaks.....	161
E. Cholesteatoma and External Auditory Canal Injury.....	161
F. Late Meningocele and/or Encephalocele Development.....	162
G. Late Meningitis.....	162
<b>VII. Summary.....</b>	<b>162</b>
<b>VIII. References and Suggested Readings.....</b>	<b>163</b>
<b>Chapter 7: Penetrating and Blunt Neck Trauma.....</b>	<b>164</b>
<b>I. Penetrating Neck Trauma.....</b>	<b>164</b>
A. Introduction.....	164
B. Projectiles, Ballistics, and Mechanisms of Injury.....	164
1. The Most Lethal Missiles.....	165
2. Temporary and Permanent Bullet Cavities.....	165
3. Historical Categorization, Types, and Treatment of Penetrating Neck Wounds.....	165
4. Historical Treatment of Penetrating Neck Wounds.....	166
C. Emergency Room Management.....	166
1. Initial Orderly Assessment.....	166
D. Anatomy.....	167
1. Vital Structures in the Neck.....	167
2. Skeletal Anatomy.....	167
3. Muscular Landmarks.....	167
4. Neck Zones.....	168
5. Vascular Injuries.....	170
E. Diagnostic Evaluation and Surgical Treatment.....	170
1. Selective Neck Exploration.....	170
2. Mandatory Neck Exploration.....	171
3. Computed Tomographic Angiography.....	171
4. Evaluation of Aerodigestive Tract Injuries.....	172
F. Conclusion.....	173
<b>II. Blunt Neck Trauma.....</b>	<b>173</b>
A. Introduction.....	173
B. Presenting Signs and Symptoms.....	173
1. Initial Diagnostic Airway Evaluation.....	173
2. Hemodynamic Instability or Signs of Vascular Injury.....	174

3. Hemodynamically Stable Patients Showing Risk Factors .....	174
4. Cervical Spine Injury Assessment .....	174
C. Conclusion .....	174
<b>III. References .....</b>	<b>175</b>
<b>Chapter 8: Laryngeal Trauma .....</b>	<b>177</b>
<b>I. Physical Examination .....</b>	<b>177</b>
A. Symptoms of Laryngeal Trauma (Subjective) .....	177
B. Signs of Laryngeal Trauma (Objective) .....	178
<b>II. Diagnosis, Imaging Studies, and Laboratory Assessment .....</b>	<b>178</b>
A. Airway Evaluation .....	178
B. Trauma Evaluation .....	178
C. Radiologic Evaluation .....	178
<b>III. Surgical Decision-Making Principles .....</b>	<b>179</b>
A. Group 1 .....	179
1. Evaluation .....	179
2. Management .....	179
B. Group 2 .....	180
1. Evaluation .....	180
2. Management .....	180
C. Group 3 .....	180
1. Evaluation .....	180
2. Management .....	180
D. Group 4 .....	180
1. Evaluation .....	180
2. Management .....	180
E. Group 5 .....	180
1. Evaluation .....	180
2. Management .....	181
<b>IV. Informed Consent .....</b>	<b>181</b>
<b>V. Perioperative Care .....</b>	<b>181</b>
A. Airway Observation .....	181
B. Adjunctive Measures .....	181
C. Speech Therapy .....	182
<b>VI. Operative Management by Location .....</b>	<b>182</b>
A. Inhalation Injury .....	182
B. Endolaryngeal Tears .....	182
C. Endolaryngeal Edema .....	183
D. Endolaryngeal Hematomas .....	183
E. Recurrent Laryngeal Nerve Injury .....	183
F. Laryngeal Fractures .....	184



G. Cricotracheal (Laryngotracheal) Separation .....	185
H. Emergency Airway Management .....	185
I. Selection of Airway Stents and Tracheotomy Tubes .....	186
1. Airway Stents.....	186
2. Tracheotomy Tubes .....	186
<b>VII. Summary</b> .....	186
<b>VIII. References</b> .....	187
<b>Chapter 9: Soft Tissue Injuries of the Face, Head, and Neck</b> .....	188
<b>I. Physical Examination</b> .....	188
A. Perform Complete Head and Neck Exam at Presentation....	189
1. Eyes .....	189
2. Ears.....	189
3. Nose .....	189
4. Mouth.....	189
5. Neck .....	189
6. Scalp.....	189
7. Cranial Nerves .....	190
<b>II. Diagnosis, Imaging Studies, and Laboratory Assessment</b> ....	190
A. Diagnosis .....	190
B. Imaging Studies.....	190
1. Plain Film Radiographs .....	190
2. Computed Tomography (CT) .....	190
3. Magnetic Resonance Imaging and Ultrasonography.....	191
C. Laboratory Assessment .....	191
1. Complete Blood Count .....	191
2. Chemistries .....	191
3. Toxicology.....	191
<b>III. Surgical Decision-Making Principles</b> .....	191
A. Timing of Wound Repair .....	191
1. Primary Closure.....	191
2. Delayed Primary Closure .....	191
3. Closure by Secondary Intent.....	192
4. Adjunctive Therapies.....	192
5. Post-Healing.....	192
B. Anesthesia Considerations .....	192
1. Localized Tissue Injuries .....	192
2. Extensive Injuries .....	193
C. Irrigation and Debridement .....	193
1. Microdebridement .....	194
2. Macrodebridement .....	194

D.	Fundamentals of Wound Closure .....	194
1.	Prepare Wound .....	194
2.	Close Tissues .....	194
3.	Avoid Undertaking Local Flaps in the "Primary" Setting .....	196
<b>IV.</b>	<b>Informed Consent</b> .....	196
<b>V.</b>	<b>Operative Management by Location</b> .....	197
A.	Scalp.....	197
B.	Forehead.....	197
C.	Auricle .....	198
1.	Superficial Lacerations .....	198
2.	Cartilage Lacerations .....	198
3.	Approximation of the Helix and Antihelix .....	199
4.	Lacerations Involving the Free Edges of the Pinna .....	199
5.	Hematomas and Seromas .....	199
6.	Perichondrial Coaptation to the Cartilage Framework ....	199
7.	Segmental Avulsion of the Pinna .....	199
8.	Cartilage Banking.....	200
9.	Total and Near-Total Auricular Avulsion.....	200
D.	Periorbita.....	200
1.	Ophthalmology Consultation .....	200
2.	Irrigation.....	200
3.	Delayed Closure in Operating Room .....	200
4.	Lid Laceration.....	200
5.	Posterior Lamella Lacerations .....	200
6.	Anterior Lamella Lacerations.....	201
7.	Lacrimal Canalicular Injury.....	201
8.	Canthal Injuries .....	201
9.	Closure at the Lid Margin .....	201
10.	Lid Margin and Proximal Anterior Lamella Sutures .....	201
11.	Superior Lid Lacerations.....	201
12.	Visible Orbital Fat .....	201
E.	Nose .....	202
1.	Nasal Soft Tissue Injuries .....	202
2.	Extensive Nasal Vestibule Injuries.....	202
3.	Septal Hematomas.....	202
4.	Severe Septal Mucosal Lacerations or Hematomas ....	203
5.	Extensive Soft Tissue Undermining .....	203
F.	Lips .....	203
1.	Wound Examination.....	203
2.	Wound Closure .....	203
3.	Reapproximation of Landmarks .....	203
G.	Cheeks .....	204

H. Chin .....	204
I. Neck .....	204
<b>VI. Perioperative Care .....</b>	<b>204</b>
A. Antibiotic Prophylaxis .....	204
1. Uncontaminated Wounds <24 Hours Mature .....	204
2. Contaminated Wounds or Wounds >24 Hours Mature.....	204
3. Oronasal Wounds (i.e., through-and-through lip lacerations).....	205
4. Ear or Nasal Cartilage Involvement.....	205
5. Animal Bites.....	205
6. Human Bites.....	206
B. Pros and Cons of Topical Antibiotics.....	206
1. Neomycin.....	206
2. Bacitracin .....	206
3. Mupirocin (e.g., Bactroban®).....	207
C. Tetanus Prophylaxis .....	207
D. Post-Repair Directives .....	207
1. Moisturization .....	207
2. Daily Debridement .....	207
3. Dressings .....	208
4. Bathing.....	208
5. Antibiotics .....	208
6. Nutrition.....	208
7. Head Elevation.....	208
8. Patient and Caretaker Instructions.....	208
9. Suture Removal .....	208
10. Hypertrophic Scarring and Hyperemia .....	208
<b>VII. Special Circumstances .....</b>	<b>209</b>
A. Abrasions.....	209
B. Avulsion Injuries .....	209
C. Facial Nerve Injuries.....	209
D. Bite Injuries.....	209
1. Animal Bites.....	210
2. Human Bites.....	210
E. Burn Injuries.....	211
1. Facial Subsites .....	212
<b>VIII. Conclusion .....</b>	<b>213</b>
<b>IX. References.....</b>	<b>213</b>

<b>Chapter 10: Foreign Bodies and Caustic Ingestion</b> .....	214
<b>I. Anatomy</b> .....	214
A. Upper Airway.....	214
B. Lower Airway .....	214
1. Right Main Bronchus .....	215
2. Left Main Bronchus .....	215
C. Alimentary Tract .....	215
1. Hypopharynx .....	215
2. Esophagus.....	215
3. Stomach .....	215
<b>II. Foreign Bodies</b> .....	215
A. Primary Survey .....	216
B. Patient History.....	216
1. Phases of Aspiration .....	216
2. Symptoms.....	216
3. Information Gathering.....	217
C. Physical Evaluation .....	217
1. General .....	217
2. Head, Eyes, Ears, Nose, and Throat.....	217
3. Pulmonary.....	217
4. Abdomen .....	218
5. Fiberoptic Exam.....	218
D. Imaging.....	218
1. Aspiration .....	218
2. Ingestion.....	220
E. Management.....	220
1. Special Considerations .....	220
2. Endoscopy .....	220
3. Controversies in Management: Flexible versus Rigid Endoscopy .....	222
4. Postoperative Management.....	223
F. Prevention and Management of Complications .....	223
1. Indications for Antibiotics .....	223
2. Pulmonary.....	224
3. Esophageal .....	224
<b>III. Caustic Ingestion</b> .....	224
A. Categories of Caustic Materials .....	225
1. Acids (pH <7).....	225
2. Alkali (pH >7).....	225
3. Bleach (pH ~7).....	225
B. Primary Survey .....	226
C. Patient History.....	226
1. Age and Amount Ingested .....	226
2. Agent Ingested .....	226

3. Timing of Ingestion.....	226
D. Symptoms.....	226
E. Physical Exam.....	227
1. General.....	227
2. HEENT.....	227
3. Pulmonary.....	227
4. Abdomen.....	227
F. Preoperative Management.....	227
1. Limit Fluid Intake.....	227
2. Avoid Neutralizing Agents.....	227
3. Apply Conservative Measures.....	227
4. Place Nasogastric Feeding Tubes under Supervision....	227
5. Use Imaging.....	228
6. Consider Endoscopy.....	228
G. Postoperative Management.....	230
1. Pharmacologic Therapy.....	230
2. Alimentation.....	230
3. Further Workup.....	230
H. Complications.....	230
1. Esophageal Perforation.....	230
2. Esophageal Strictures.....	231
3. Esophageal Carcinoma.....	231
<b>IV. Conclusion.....</b>	<b>231</b>
<b>V. References.....</b>	<b>232</b>
<b>Chapter 11: Outcomes and Controversies.....</b>	<b>233</b>
<b>I. Outcomes.....</b>	<b>233</b>
A. Factors Affecting the Clinical Outcome.....	233
B. Main Factors under Physician Control.....	233
C. Case Management and Coordination.....	233
D. Clinical Indicators and Best Practices.....	234
<b>II. Controversies.....</b>	<b>234</b>
A. Closed versus Open Reduction of Nasal Fractures.....	234
1. Local Anesthesia versus Deeper Anesthesia.....	234
2. Outpatient versus Inpatient Closed Reduction.....	234
B. Immediate Primary versus Delayed Closure of Contaminated Soft Tissue Wounds.....	235
1. Risk of Infection.....	235
2. Cost Considerations.....	235
3. Use of Metal Alloy or Resorbable Fixation Plates.....	235
<b>III. Final Considerations.....</b>	<b>235</b>
<b>Conclusion.....</b>	<b>237</b>
<b>AAO-HNS Committee on Trauma.....</b>	<b>238</b>

## Preface

The surgical care of trauma to the face, head, and neck that is an integral part of the modern practice of otolaryngology–head and neck surgery has its origins in the early formation of the specialty over 100 years ago. Initially a combined specialty of eye, ear, nose, and throat (EENT), these early practitioners began to understand the inter-relationships between neurological, osseous, and vascular pathology due to traumatic injuries. It also was very helpful to be able to treat eye as well as facial and neck trauma at that time.

Over the past century technological advances have revolutionized the diagnosis and treatment of trauma to the face, head, and neck—angiography, operating microscope, sophisticated bone drills, endoscopy, safer anesthesia, engineered instrumentation, and reconstructive materials, to name a few. As a resident physician in this specialty, you are aided in the care of trauma patients by these advances, for which we owe a great deal to our colleagues who have preceded us. Additionally, it has only been in the last 30–40 years that the separation of ophthalmology and otolaryngology has become complete, although there remains a strong tradition of clinical collegiality.

As with other surgical disciplines, significant advances in facial, head, and neck trauma care have occurred as a result of military conflict, where large numbers of combat-wounded patients require ingenuity, inspiration, and clinical experimentation to devise better ways to repair and reconstruct severe wounds. In good part, many of these same advances can be applied to the treatment of other, more civilian pathologies, including the conduct of head and neck oncologic surgery, facial plastic and reconstructive surgery, and otologic surgery. We are indebted to a great many otolaryngologists, such as Dr. John Conley's skills from World War II, who brought such surgical advances from previous wars back to our discipline to better care for patients in the civilian population. Many of the authors of this manual have served in Iraq and/or Afghanistan in a combat surgeon role, and their experiences are being passed on to you.

So why develop a manual for resident physicians on the urgent and emergent care of traumatic injuries to the face, head, and neck? Usually the first responders to an academic medical center emergency department for evaluation of trauma patients with face, head, and neck injuries will be the otolaryngology–head and neck surgery residents. Because there is often a need for urgent evaluation and treatment—bleeding and

airway obstruction—there is often little time for the resident to peruse a reference or comprehensive textbook on such trauma. Thus, a simple, concise, and easily accessible source of diagnostic and therapeutic guidelines for the examining/treating resident was felt to be an important tool, both educationally and clinically.

This reference guide for residents was developed by a task force of the American Academy of Otolaryngology—Head and Neck Surgery (AAO-HNS) Committee on Trauma. AAO-HNS recently established this standing committee to support the continued tradition of otolaryngology-head and neck surgery in the care of trauma patients. An electronic, Portable Document Format (PDF), suitable for downloading to a smart phone, was chosen for this manual to facilitate its practical use by the resident physician in the emergency department and preoperative area.

It should be used as a quick-reference tool in the evaluation of a trauma patient and in the planning of the surgical repair and/or reconstruction. This manual supplements, but does not replace, more comprehensive bodies of literature in the field. Use this manual well and often in the care of your patients.

**G. Richard Holt, MD, MSE, MPH, MABE**

*Editor and Chair*

*Task Force on Resident Trauma Manual*

**Joseph A. Brennan, MD, Colonel, MC, USAF**

*Chair*

*AAO-HNS Committee on Trauma*

## Acknowledgments

This quick reference guide for resident physicians in trauma management reflects the efforts of many individuals in the American Academy of Otolaryngology—Head and Neck Surgery and a special task force of the AAO-HNS Committee on Trauma.

The editors would like to thank all of the authors who generously gave their time and expertise to compose excellent chapters for this Resident Manual in the face of busy clinical and academic responsibilities and under a very narrow timeframe of production. These authors, experts in the care of patients who have sustained trauma to the face, head, and neck, have produced practical chapters that will guide resident physicians in their assessment and management of such trauma. The authors have a wide range of clinical expertise in trauma management, gained through community and military experience.

A very special appreciation is extended to Audrey Shively, MSHSE, MCHES, CCMEP, Director, Education, of the AAO-HNS Foundation, for her unwavering efforts on behalf of this project, and her competent and patient management of the mechanics of the Resident Manual's production. Additionally, this manual could not have been produced without the expert copyediting and design of diverse educational chapters into a cohesive, concise, and practical format by Joan O'Callaghan, Director, Communications Collective, of Bethesda, Maryland.

The editors also wish to acknowledge the unwavering support and encouragement from: Rodney P. Lusk, MD, President; David R. Nielsen, MD, Executive Vice President and CEO; Sonya Malekzadeh, MD, Coordinator for Education; and Mary Pat Cornett, CAE, CMP, Senior Director, Education and Meetings, of the AAO-HNS/F. We also appreciate the administrative support of Rudy Anderson as AAO-HNS/F Staff Liaison for the Trauma Committee.

Since it takes a group of dedicated professionals to produce an educational and clinical manual such as this, all have shared in the effort, and each individual's contribution has been outstanding.

**G. Richard Holt, MD, MSE, MPH, MABE**  
*Editor and Chair*  
*Task Force on Resident Trauma Manual*

**Joseph A. Brennan, MD, Colonel, MC, USAF**  
*Chair*  
*AAO-HNS Committee on Trauma*



## Resident Trauma Manual Authors

### **Joseph A. Brennan, MD, Colonel, MC, USAF**

Chair, AAO-HNS Committee on Trauma  
Chief, Department of Surgery  
San Antonio Military Medical Center  
Fort Sam Houston, Texas

### **G. Richard Holt, MD, MSE, MPH, MABE**

Chair, Task Force on Resident Trauma Manual  
Professor Emeritus, Department of Otolaryngology-Head and Neck Surgery  
University of Texas Health Science Center  
San Antonio, Texas

### **Matthew P. Connor, MD, Captain, MC, USAF**

Resident Physician, Department of Otolaryngology-Head and Neck Surgery  
San Antonio Uniformed Services Health Education Consortium  
Fort Sam Houston, Texas

### **Paul J. Donald, MD**

Professor and Vice Chair, Department of Otolaryngology  
University of California-Davis Medical Center  
Sacramento, California

### **Vincent D. Eusterman, MD, DDS**

Director, Otolaryngology-Head and Neck Surgery  
Denver Health Medical Center  
Denver, Colorado

### **David K. Hayes, MD, Colonel, MC, USA**

Chief of Clinical Operations, US Army Southern Regional Medical Command  
San Antonio Military Medical Center  
Fort Sam Houston, Texas

### **Robert M. Kellman, MD**

Professor and Chair, Department of Otolaryngology and Communication Sciences  
State University of New York Upstate Medical Center  
Syracuse, New York

### **John M. Morehead, MD**

Associate Professor and Program Director  
Department of Otolaryngology-Head and Neck Surgery  
University of Texas Health Science Center  
San Antonio, Texas

**Mark D. Packer, MD, Colonel (P), MC, FS, USAF**

Director, DOD Hearing Center of Excellence  
Chief, Neurotology, Cranial Base Surgery  
San Antonio Military Medical Center  
Fort Sam Houston, Texas

**Whitney A. Pafford, MD**

Resident Physician, Division of Otolaryngology  
New York University School of Medicine  
New York, New York

**Mitchell Jay Ramsey, MD, Lt Colonel, MC, USA**

Chief Otology/Neurotology  
Landstuhl Kaiserlautern Army Medical Center  
Germany

**Nathan L. Salinas, MD, Captain, MC, USA**

Chief, Department of Otolaryngology  
Bassett Army Community Hospital  
Ft. Wainwright, Alaska

**Joseph C. Sniezek, MD, Colonel, MC, USA**

Otolaryngology Consultant to the Surgeon General of the Army  
Tripler Army Medical Center  
Honolulu, Hawaii

**Christian L. Stallworth, MD**

Assistant Professor, Facial Plastic and Reconstructive Surgery  
Department of Otolaryngology-Head and Neck Surgery  
University of Texas Health Science Center  
San Antonio, Texas

**Matthew Scott Stevens, MD**

Resident Physician, Department of Otolaryngology-Head and Neck  
Surgery  
University of Texas Health Science Center  
San Antonio, Texas

**Richard W. Thomas, MD, DDS, Major General, MC, USA**

Otolaryngologist-Head and Neck Surgeon  
Commanding General, Western Region Medical Command  
Joint Base Lewis-McChord, Washington

# Chapter I: Patient Assessment

**Matthew P. Connor, MD, Captain, MC, USAF**

**Mark D. Packer, MD, Colonel (P), MC, FS, USAF**

Because the otolaryngologist may not be present during patient arrival in the trauma bay, the patient assessment often begins with a call from a referring physician. Important information to retrieve includes the urgency of the patient's status, mechanism of injury, injury list, medical and demographic information, and, most important, airway status. It is important to review with the trauma team the potential for an unstable airway in any patient with craniofacial or neck trauma. When in doubt, the otolaryngologist should consider himself or herself the definitive airway expert. The importance of an ear, nose, and throat evaluation has been proven to be critical.<sup>1</sup> Otolaryngologists have the airway, endoscopy, and neck exploration skills necessary to take care of the most critically injured patients.

## I. Diagnostic Evaluations

### A. FULL-BODY TRAUMA ASSESSMENT

Trauma patients will often have a wide range of concomitant injuries. These patients require evaluation according to the Advanced Trauma Life Support (ATLS) protocol. This includes the airway, breathing, circulation, neurologic, and bodily assessments. Patients with severe or life-threatening head, chest, abdominal, or orthopedic injuries are challenging. A cursory head and neck exam performed by the trauma team may miss foreign bodies, facial nerve, parotid duct, ocular, inner ear, and basilar skull injuries, which can be time-sensitive matters for diagnosis and intervention. If possible, the otolaryngologist should make every effort to obtain an accurate and complete head and neck exam as soon as possible to mitigate potential threat and damage, and optimize outcomes through timely repair.

The injury severity score (ISS) is accepted as the gold standard for scoring the severity of anatomic injury.<sup>2,3</sup> It is built on an Abbreviated Injury Scale.<sup>3,4</sup> Summation of scores from the three most severe injuries, considering one injury per body region, results in an ISS that correlates with survival and estimates the overall severity of injury for patients with multiple injuries. An ISS of 16 or greater is associated with critical injury.<sup>5</sup> Salinas et al. defined massive facial trauma as any injury to the face involving three or more facial aesthetic units. Using this definition, they found that massive facial trauma was associated with higher ISS,

## CHAPTER 1: Patient Assessment

higher transfusion rates, and an increased risk for eye and brain injuries.<sup>3</sup>

The otolaryngologist must work with the trauma team and consulting services prioritizing management of head and neck injuries in light of known and potential injury to other critical regions of the body to optimize systematic care of all injuries. For example, a patient with facial lacerations may be mistakenly triaged to the facial trauma service for repair, neglecting a mechanism that should prompt further scrutiny to rule out cervical spine or intracranial injury. Communication between teams is critical for optimal management of the polytrauma patient.

### **B. HISTORY**

The history of the injurious event is paramount. The mechanism (blunt versus blast versus penetrating), time, degree of contamination, and events since the injury should be documented.

When secondary to a motor vehicle accident, information related to the status of the windshield, steering column, and airbags should be elicited. Details related to extrication and whether exposure to chemical, fire, smoke, or extreme temperatures were encountered are important. Information related to events preceding the event, such as timing of the last meal or use of medications or substances that might alter mental status and ability to respond coherently, are relevant. The patient's medical history, including medications and tetanus status are also relevant.

For penetrating injuries related to gunshot wounds, information related to the type of firearm, number of shots, and proximity of the victim can predict the extent of damage and the level of threat to internal organs. For stabbing injuries, possession of the weapon and information about the assailant can predict potential damage. When able, the patients should be asked about any new deficits or changes to their hearing, vision, voice, occlusion, or other neurologic deficits, as well as if they have new rhinorrhea or epistaxis. They should specifically be asked about and observed for signs of difficulty breathing, and whether they feel short of breath.

Sometimes patients come from a referring institution, where initial wound washouts, packing, or other interventions have taken place. Operative reports from those encounters are a vital piece of information in these instances. When a patient arrives intubated with an injury pattern concerning for facial nerve injury, every attempt should be

made to identify whether the patient was able to display facial nerve function in the interval between injury and intubation. Confirmation that the patient had normal facial nerve function prior to the injury is extremely helpful in managing such injuries. Details from premorbid photos or history provided from family and friends is often helpful.

The social context should be considered in all trauma patients. Unfortunately, domestic violence produces a large component of facial trauma. These patients must be assured of their security, and their treatment should only be discussed with appropriate persons. When children are involved, it is imperative to enlist the resources of the hospital (social work, childhood protection agencies, etc.) in the care of the patient and include them when planning both treatment and disposition. Over 50 percent of cases of child abuse include injuries to the face.<sup>6</sup>

Personal history from an alert patient provides perspective and insight that may not be available from a second- or third-party interview.

It is important to identify the assault weapon. Knowledge of the ballistics of the penetrating object can help determine the management plan and predict risk of injury.<sup>7-10</sup> Civilian handgun injuries have low-muzzle velocity and have less damaging effects than other projectiles. Military rifles, on the other hand, have high-muzzle velocity and can transmit energy to surrounding tissue. A cavity of up to 30 times the size of the missile may be created and may pulsate over 5 to 10 centimeters.<sup>11</sup> In this kind of injury, it is necessary to examine surrounding structures (trachea, esophagus), even when the bullet wounds are inches away. Some hunting rifles use expanding bullets that can create a large wound cavity. Some may not cause an exit wound, or may fragment with partial projectiles, causing injury far from the primary direct path. Shotguns are typically low-muzzle velocity, but the severity of shotgun wounds will vary, depending on the proximity to the victim. At close range, the entire charge can act like a high-velocity bullet.<sup>12</sup>

From the wars in Iraq and Afghanistan, we have learned that improvised explosive devices (IEDs) can send shrapnel wounds that pepper patients through small and seemingly insignificant entry sites.<sup>1</sup> These small holes, however, can represent high-velocity injury, requiring neck exploration (when symptomatic), imaging such as computed tomography (CT) angiography, and panendoscopy.<sup>1</sup>

## C. HEAD AND NECK EXAMINATION

It is important to perform a systematic and thorough examination. This examination should become routine for the otolaryngologist to overcome assumptions and avoid missing unexpected but significant injury.

Every practitioner caring for a trauma patient is obligated to follow the ATLS protocol.<sup>13</sup> The new ATLS guidelines have instituted a CABDE algorithm to replace the historical ABCDE prioritization. This new algorithm stresses the importance of establishing circulation early. Still, the otolaryngologist will more frequently be consulted as the airway expert. Airway compromise may come from significant swelling as a result of skeletal fracture, from hemorrhage, or even from superficial trauma. Once the status of the airway is secured or confirmed to be safe, the rest of the head and neck exam can proceed. Information obtained from flexible laryngoscopy can prove to be a vital tool in the airway assessment when time and stability permit. The exact order of the head and neck exam may vary, but this Resident Manual will illustrate the anatomic “top-down” approach.

Before beginning this secondary exam, the resident physician should carefully clean the wounds and surrounding skin. This not only decreases the risk for infection but also improves visualization of wounds. Many times the otolaryngologist may find these patients intubated, in a cervical collar, with a nasogastric tube in place, and face covered with dried blood and debris. It is imperative to cleanse the patient, and ask for assistance to remove the cervical collar and maintain inline stabilization to examine the neck, and to examine the hair-bearing scalp and back of head. These wounds may be irrigated with warm saline solution under moderate pressure, and diluted hydrogen peroxide. When there is concern for foreign bodies, it may be helpful to use loupe magnification to remove small debris from the wounds.

### 1. Upper Third

For the upper third of the head:

- Evaluate the forehead for sensation and motor function.
- Examine the bony framework of the frontal sinuses stepoffs.
- Cleanse the entire scalp and skin and examine them for lacerations.

### 2. Middle Third

#### a. Assessment of the Eyes

The eyes require thorough assessment. The pupillary light reflex should be tested. Failure of the pupil to respond may indicate injury to the afferent system (optic nerve) or efferent system (third cranial nerve

and/or ciliary ganglion), or it may indicate a more serious intracranial injury. If abnormalities are discovered, then these findings must be communicated to a neurosurgeon or ophthalmologist.

Gaze or positional nystagmus may indicate an otic capsule violating temporal bone fracture, but could also be associated with intoxication or medication. Chemosis, subconjunctival hemorrhage, and periorbital ecchymosis are signs of orbital injury. Extraocular motility must be examined—both with voluntary gaze when able, and with forced duction testing when not. Forced duction testing will be quite helpful in differentiating true entrapment of orbital structures from neuropraxia and muscle edema and contusion. The globe position should be assessed in the anteroposterior and vertical dimensions. If the patient is alert, visual acuity and visual fields should be tested, and new deficits confirmed with the patient history. Any injury to the orbit that predisposes the patient to corneal exposure and abrasion should be appropriately treated with artificial tears and coverage. Inability to close the eyelid with a risk of drying from suspected facial nerve injury should be covered by a noncompressive shield.

Despite this preliminary workup, it is always recommended to have ophthalmologic evaluation when compromised function is suspected or before any orbital fracture repair, because subtle injuries, such as retinal tears, may be a contraindication to surgery. Additionally, the presence of a hyphema in the anterior chamber may require postponement of the surgical procedure until the eye is cleared by the ophthalmologist.

### ***b. Palpation of the Bony Fragment of the Midface***

Next, the bony framework of the midface is palpated. While zygomatic malposition may be discovered, it also may be obscured by swelling. Nasal fractures may reveal obvious displacement, and crepitus may be palpated with comminuted fractures. If present, a septal hematoma must be drained before it results in necrosis of septal cartilage. Injury to the second division of the trigeminal nerve, V<sub>2</sub>, may result in cheek and nasal numbness. These findings should be recorded in the patient chart by the examining physician.

Signs of nasal-orbital-ethmoid (NOE) fractures include telescoping of the nasal, lacrimal, and ethmoid bones; loss of nasal dorsal height; development of epicanthal folds; and canthal ligament displacement. This displacement can be determined by measuring the horizontal palpebral widths and the intercanthal distance, which should be equal. Evaluation of the lacrimal collecting system usually takes place during surgery with probing of lacrimal punctum and ducts by lacrimal probes.

## CHAPTER 1: Patient Assessment

However, a positive flourescein instillation (Jones) test effectively rules this out. The Jones dye test is carried out either preoperatively or intraoperatively, depending on the condition of the patient. (See Chapter 3, section II, on NOE complex trauma.)

### ***c. Palpation of the Palate and Maxillary Dentition***

The palate and the maxillary dentition are inspected and palpated for instability. Any missing dentition should alert the physician to the possibility of a fracture. Any missing teeth must likewise be accounted for. If this is not possible, the patient needs a chest x-ray to rule out aspiration of any missing teeth. Although rare, rocking of the midface with fingers on the palate and intact incisors connotes the presence of a craniofacial separation (Le Fort III fracture).

### **3. Lower Third**

Patients often do not have premorbid Class 1 occlusion, as defined by Angle.<sup>14</sup> At least 20 percent will have anatomy that deviates from the ideal bite relationship.<sup>14</sup> The only reliable assessment of malocclusion secondary to trauma is misalignment of wear facets. Thus, the occlusion should be evaluated by inspection of wear facets.

New open or crossbite deformities may indicate a fracture. If able, patients should be asked about their occlusion and symptoms of trismus. The oral mucosa should be evaluated for any lacerations or hematomas, with special consideration for the floor of mouth and airway patency. The teeth should again be examined for injury and, when noted, a dental consult should be obtained. Any numbness in the V3 or mental nerve distribution should be documented.

### **4. Otoscopy**

Examination of the ears is a necessary part of the exam that may be overlooked by first responders and not prioritized due to other facial injuries. Ominous indicators of injury in this region include Battle's sign, mastoid echymosis, or a halo sign, a quick indicator of potential cerebrospinal fluid (CSF) leak. The halo sign is manifested by a clear ring extending beyond blood spotting of otorrhea on tissue paper.

Lacerations and hematoma of the pinna are noted and repaired to prevent cartilaginous injury, malformation, and necrosis. When observed, perichondritis generally spares lobule involvement, and should be treated expeditiously. Otoscopy may reveal blood, dirt, or other foreign bodies or material within the external auditory canal that can compromise further examination and necessitates careful removal.



A laceration in the canal or hemotympanum may represent a skull base fracture. When able, these patients should be tested at bedside with a 512-Hertz tuning fork, and should undergo an audiogram as soon as possible. Perforation of the tympanic membrane should be identified, and imploded flaps should be externalized or patched to prevent cholesteatoma formation. Signs and symptoms of facial nerve injury, CSF leak, and otic capsule violation should be further evaluated by high-resolution CT imaging of the temporal bone.

### **5. Neurologic Examination**

Facial nerve function should be tested in each division. If a patient is uncooperative, try eliciting facial grimace with a simple pinch. Any concern for deficit should be appropriately documented and related with the history of the trauma and the injury pattern to assess for facial nerve injury. If the patient can cooperate, perform a thorough evaluation of all cranial nerves. The patient should also be evaluated for possible CSF leakage, otorrhea, and rhinorrhea. Any concern for exposed brain matter should be investigated in the operating room with the neurosurgeon.

### **D. INFECTION CONTROL**

As discussed previously, it is important to thoroughly clean and debride all wounds. Wounds treated within 8 hours of the event and those created surgically are considered “clean” and can be closed primarily. In the face, the window for wound closure can be extended to 24 hours, because the face is a highly vascular area. However, limited data exist regarding precise cutoff points to determine which wounds are too contaminated to safely close. Heavily contaminated or devitalized wounds will benefit from antibiotics. Human bites will require treatment with broad-spectrum agents.<sup>15</sup>

### **E. IMAGING STUDIES**

CT is the workhorse for identifying facial fractures. In massive facial trauma, three-dimensional reconstructions of facial injuries may prove instrumental when planning repair. Imaging may also be helpful to examine for presence of foreign bodies. Glass is easily detected on plain films in wounds deeper than subcutaneous fat.<sup>16</sup> The radiodensity of wood is not visible on plain film, but is detectable on magnetic resonance imaging (MRI). There is also increasing support for using ultrasound to detect radiolucent foreign bodies.<sup>17</sup>

Vascular imaging is recommended for penetrating injuries to Zones I and III of the head and neck, and for fractures of the carotid canal noted

## CHAPTER 1: Patient Assessment

on other CT imaging and associated with neurological deficits. Choice of the appropriate imaging study will be a function of the suspected injuries determined on the primary assessment. MRI imaging may be indicated for brain parenchymal injuries, while enhanced CT scanning may be helpful in ruling out a concomitant stroke in an elderly patient.

### F. LABORATORY TESTS

All patients should have basic blood chemistries, blood counts, coagulation panel, and alcohol and other drug studies when indicated. These tests are especially important in preparation for taking the patient to the operating room.

### G. DIGITAL PHOTOGRAPHS

Finally, with the patient's permission and if the hospital has the capability, digital photographs should be taken and stored in a secure place according to Health Insurance Portability and Accountability Act (HIPAA) regulations. These photographs are invaluable when planning the patient's subsequent secondary reconstruction, if needed, and for teaching and educational purposes. Each hospital facility generally has guidelines and rules for operative photography. Typically, there is a ban on using cell phone photography, so a dedicated patient photography camera should be used.

## II. References

1. Brennan J. Experience of first deployed otolaryngology team in Operation Iraqi Freedom: The changing face of combat injuries. *Otolaryngology-Head and Neck Surgery*. 2006;134:100-105.
2. Baker SP, O'Neill B, Haddon W Jr., Long WB. The injury severity score: A method for describing patients with multiple injuries and evaluating emergency care. *J Trauma*. 1974;14(3):187-196.
3. Salinas NL, Brennan JM, Gibbons MD. Massive facial trauma following improvised explosive device blasts in Operation Iraqi Freedom. *Otolaryngology-Head and Neck Surgery*. 2011;144(5):703-707.
4. Gennarelli T, Wodzonski E. *The Abbreviated Injury Scale—2005*. Des Plaines, IL: Association for the Advancement of Automotive Medicine; 2005.
5. Will MJ, Goksel T, Stone CG, et al. Oral and maxillofacial injuries experienced in support of Operation Iraqi Freedom I and II. *Oral Maxillofac Surg Clin North Am*. 2005;17:331-339.

6. Cairns AM, Mok JY, Welbury RR. Injuries to the head, face, mouth, and neck in physically abused children in a community setting. *Int J Paediatr Dent*. 2005;15:310-318.
7. Hill JD, Hamilton GS. Facial trauma: Soft tissue lacerations and burns. In: Flint et al. *Cummings Otolaryngology: Head and Neck Surgery*. 5th ed. Philadelphia, PA: Mosby Elsevier; 2010: 302-317.
8. Kellman RM. Maxillofacial trauma. In: Flint et al. *Cummings Otolaryngology: Head and Neck Surgery*. 5th ed. Philadelphia, PA: Mosby Elsevier; 2010: 318-341.
9. Horn DB, Maisel RH. Penetrating and blunt trauma to the neck. In: Flint et al. *Cummings Otolaryngology: Head and Neck Surgery*. 5th ed. Philadelphia, PA: Mosby Elsevier; 2010: 1625-1635.
10. Roon A, Christensen N. Penetrating neck trauma: Mandatory versus selective exploration. *J Emerg Med*. 1990;19:391.
11. Fackler M, Bellamy R, Malinowski J. The wound profile: Illustration of the middle-tissue interaction. *J Trauma*. 1998;28:21.
12. Deitch E, Grimes W. Experience with 112 shotgun wounds of the extremities. *J Trauma*. 1994;24:600.
13. Kortbeek JB, Al Turki SA, Ali J, et al. Advanced trauma life support, 8th ed., the evidence for the change. *J Trauma*. 2008;64:1638-1650.
14. Proffit WR, Fields HW Jr, Moray LJ. Prevalence of malocclusion and orthodontic treatment need in the United States: Estimates from the NHANES III survey. *Int J Adult Orthodon Orthognath Surg*. 1998;13(2):97-106.
15. Stefanopoulos PK, Tarantzopoulou AD. Facial bite wounds: Management update. *Int J Oral Maxillofac Surg*. 2005;34:464-472.
16. Orlinsky M, Bright AA. The utility of routine x-rays in all glass-caused wounds. *Am J Emerg Med*. 2006;24:233-246.
17. Blankenship RB, Baker T. Imaging modalities in wounds and superficial skin infections. *Emerg Med Clin North Am*. 2007;25:223-234.

## Chapter 2: General Principles in Treating Facial, Head, and Neck Trauma

David Hayes, MD, Colonel, MC, USA

Understanding the general principles of trauma repair in the face, head, and neck region is very important to achieving optimal outcome for the patient. Foundational is the knowledge of mechanisms of injury, tissue damage, and implications for surgical repair, based on the etiology of the trauma. Concomitant injuries of associated structures, such as the brain, spinal cord, and soft tissues, require a comprehensive knowledge of the anatomy, functional physiology, and potential risks and complications. These general principles will be reinforced in the subsequent sections of this Resident Manual for emphasis.

### I. Special Mechanisms of Injury

#### A. GUNSHOT WOUNDS

##### 1. Ballistic Sequences

Ballistics can be divided into three sequences:

- *Internal ballistics*—What happens between the cartridge being fired and the projectile leaving the muzzle.
- *External ballistics*—The flight of the projectile from the muzzle to the target.
- *Terminal ballistics*—What happens after the target is struck.

##### 2. Main Factors Affecting Projectile Strike

Terminal ballistics determine the wounding capacity of a bullet. The effect of projectile strike depends on three main factors:

- *Kinetic energy* of the projectile [ $KE = \frac{1}{2}(mv^2)$ ].
- *Projectile design*—e.g., composition, shape, jacket, weight distribution.
- *Target tissue* composition and elasticity.

##### a. Kinetic Energy

Low-energy projectiles from handguns or .22-caliber rifles have a muzzle velocity of <2000 feet per second (fps). High-energy projectiles from military assault rifles have a muzzle velocity of >2000 fps. These are jacketed with copper or polymer to hold the projectile together, as the lead begins to melt from heat generated at speeds >2000 fps (Table 2.1).

**Table 2.1. Caliber, Muzzle Velocity, and Energy of Commonly Used Weapons**

Caliber	Muzzle Velocity	Energy (ft-lb)
.32	745	140
.357	1410	540
.38	855	255
.44	1470	1150
.45	1850	390
9 mm	935	345
.243 Winchester	3500	1725
M16 (.223 cal or 5.56 mm)	3650	1185
7.62 Nato rounds	2850	1535
AK47	3770	1735

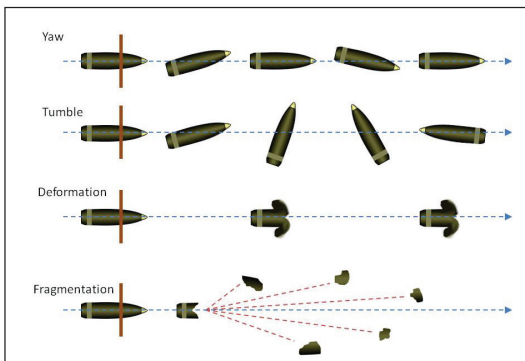
ft-lb = foot-pounds; mm = millimeter.

### **b. Projectile Design**

#### *i. Projectile Characteristics Influencing Energy Transfer*

All projectiles passing through soft tissue create a permanent cavity, or tract, that is generally apparent on initial examination. If a bullet destabilizes upon contact with tissue, it deforms, yaws, tumbles, or fragments, causing greater tissue destruction (Figure 2.1). Thus, exit wounds tend to be larger than entry wounds. Tissue damage is proportional to the energy transferred to the tissues. The energy transfer is influenced by four projectile characteristics:

- *Yaw*—The deviation of the projectile in its longitudinal axis.
- *Tumble*—The forward rotation around the center of mass.
- *Deformation* of the projectile.
- *Fragmentation* of the projectile.



**Figure 2.1**

Four characteristics of projectile missiles.

## CHAPTER 2: General Principles in Treating Facial, Head, and Neck Trauma

### ii. High-Energy Projectiles

High-energy projectiles also create a temporary cavity that may not be apparent on initial exam. The temporary cavity is produced as the energy wave of the projectile displaces surrounding tissue, which rapidly collapses back into place. The higher the energy of the projectile, the larger the temporary cavity created.

A previously held concept suggested tissue that is displaced in this fashion is disrupted and irreversibly damaged. Hunt et al. note that post-injury observation of wounds with a temporary cavity in an animal model demonstrates that the momentary stretch produced does not usually cause cell death or tissue destruction. Although vasospasm or cautery from the heat of the projectile may cause reversible ischemia, they suggest that debridement of high-velocity injuries should be confined to obviously devitalized tissue.

### iii. Multiple Projectiles

Shotguns fired at close range (<40 feet) cause massive tissue destruction from multiple, rapidly destabilized pellets. Embedded wadding may be found in the wound if the shot was within 10–15 feet.

### c. Target Tissue Composition and Elasticity

Tissues of higher density (e.g., muscle or liver) present greater mass to a projectile and absorb more energy from a projectile. Tissues of lower elasticity (e.g., bone or cartilage) resist deformation and will absorb energy until they fracture. The actual destruction of the permanent cavity and stretch caused by the temporary cavity are better tolerated by more elastic tissues, such as the lung, as opposed to a more rigid tissue, like bone.

## B. BLAST INJURIES

### 1. Mechanisms for Causing and Types of Blast injury

Explosions produce seven potential mechanisms for causing physical injury, which vary in degree by type of explosive, proximity of victim to the blast, and additional factors affecting exposure (e.g., body armor, enclosed space):

- Interaction of the blast pressure wave with the body/organs.
- Acoustic energy causing hearing loss.
- Light energy causing blindness.
- Thermal energy causing burns.
- Energized debris/shrapnel.
- Release of toxic gases.
- Psychological effect—*Do not overlook.*

As shown in Table 2.2, blast injuries are commonly grouped into four types. Table 2.2 also presents the mechanisms related to those types of injuries.

**Table 2.2. Types of Blast Injury and Mechanisms for Causing Those Injuries**

Types	Mechanisms for Causing Injury
Primary	Interaction of the blast wave with the body.
Secondary	Debris (shrapnel) accelerated by the blast striking the body.
Tertiary	Physical displacement of the body by the blast wind.
Quaternary	All other effects of exposure to the blast (e.g., psychological or burns).

**a. Primary Blast Injury**

Tissue damage from the blast wave, referred to as primary blast injury, can cause occult trauma to the ocular, aural, pulmonary, cardiovascular, musculoskeletal, and neurologic systems. Awareness of the type of blast and circumstances is key to understanding the pathophysiology and making early diagnoses.

**b. Auditory Blast Injury**

Kerr reported that the tympanic membrane will rupture at overpressures as low as 35 kilopascals (kPa), and half the damaged tympanic membrane will have ruptured by the time the overpressure reaches 104 kPa. However, this correlates poorly with blast injury elsewhere, and is of no use as a predictive marker. Leibovici and colleagues report nearly 650 survivors of explosion exposure, 193 of whom had evidence of blast injury. Three-quarters had isolated eardrum rupture—none subsequently had other blast injuries, whereas nearly 10 percent of cases had pulmonary blast injury with intact tympanic membranes.

**c. External Blast Wave Injury**

Explosions in enclosed spaces, or external blast waves that enter an enclosed space, can dramatically increase the energy, as the reflected blast wave combines with the incident wave to increase the magnitude of the overpressure.

## II. Traumatic Brain Injuries

### A. CLOSED HEAD INJURIES

Classification of severe head injury may be based upon clinical, radiological, or anatomical findings. Mild traumatic brain injury (TBI) is the medical term for concussion, and the terms are often used interchangeably. The term “mild” does not describe the symptoms; rather, it describes the injury sustained. The 2009 Veterans Administration-Department of Defense clinical practice guidelines (CPGs) are currently the highest-rated mild TBI CPG. All patients with a moderate or severe head injury require a head computed tomography (CT) scan.

#### 1. Classification by Presenting Signs and Symptoms

Table 2.3 presents a system of classification by presenting signs and symptoms.

**Table 2.3. Classification by Presenting Signs and Symptoms**

Injury Severity	Glasgow Coma Scale	Loss of Consciousness	Neurological Deficit
Minimal	15	No	No
Mild	14-15	<5 minutes	No
Moderate	9-13	>5 minutes	Yes

#### 2. Classification by CT Findings

The CT classification (Marshall Scale) was developed from the data accumulated from the National Institutes of Health Traumatic Coma Data Bank. It was the first to highlight the poor outcomes associated with the presence of effacement of the basal cisterns and/or midline shift over 5 mm on the initial CT scan.

#### 3. Classification by Anatomy

The anatomical classification of head injuries divides them into (1) focal injuries, including contusions and traumatic hematomas, and (2) diffuse injuries, such as concussion and diffuse axonal injury (DAI). These categories are not mutually exclusive, as a severe underlying DAI may explain poor recovery following a technically perfect evacuation of an acute subdural hematoma.

#### 4. Initial Assessment

The Glasgow Coma Scale score that is most useful in determining the patient’s neurologic prognosis is the score after adequate resuscitation.



Early pupillary changes seen in severe head injury may be related to brainstem hypoperfusion, rather than brainstem compression.

Pupillary inequality after resuscitation mandates a CT scan of the head. A difference of up to 1 mm between pupils is seen in up to 20 percent of the healthy population.

Neurosurgical advice should be sought when:

- There is a positive head CT scan.
- A patient fulfills criteria for CT scanning, but this cannot be done for 24 hours.
- The patient continues to deteriorate irrespective of CT scan findings, or if there is a compound depressed skull fracture, penetrating injury, or cerebrospinal fluid (CSF) leak.

## **B. PENETRATING HEAD INJURY**

Penetrating head injury—displaced skull fractures, evidence of CSF leak or exposed brain—warrants consultation with a neurosurgeon

## **C. CAUTIONARY NOTES ON THE ACUTE MANAGEMENT OF PATIENTS WITH HEAD INJURY**

- *Do not use nasogastric tubes*—A nasogastric tube should not be placed in any patient with a suspected base-of-skull fracture.
- *Avoid hypotonic fluids*—Hypotonic fluids, such as Ringer's or dextrose/saline, should be avoided.
- *Do not use Mannitol*—Using Mannitol to maintain cerebral blood flow remains controversial.
- *Avoid steroids*—Steroids are not recommended in the current management of the head-injured patient.
- *Apply prophylactic anticonvulsants strategically*—Prophylactic anticonvulsants are recommended for acute subdural hematoma, penetrating injuries, cortical contusions, a history of significant alcohol abuse, and epilepsy.
- *Use antibiotics sparingly*—Antibiotics are not recommended, unless a wound overlying a skull fracture or open skull injury is grossly contaminated. In these cases, a broad-spectrum cephalosporin is recommended. Metronidazole should be added if a sinus injury is suspected.
- *Avoid secondary insults*—A critical concept in the management of the head-injured patient is avoidance of further injury from hyperthermia, hypoxia, hypocarbia, hypotension, and hyperglycemia, which are common in the head-injured patient.

### III. Principles of Soft Tissue Wound Management

#### A. INITIAL WOUND MANAGEMENT

##### 1. Cleansing

Manually remove gross contaminants and irrigate wounds copiously with saline (2 liters or more per site), gently massaging the tissues as soon as is practical. Do not use pulse irrigation under pressure.

##### 2. Debridement

Debride frayed, shredded, or burned skin and muscle conservatively in the operating room as soon as practical. The incidence of wound-healing complications from gunshot wounds that traverse the oral cavity is high. This is due to direct inoculation of the tract by the projectile and the presence of devitalized tissue. Early initial debridement of necrotic tissues from severe facial injuries and beginning antibiotic treatment as soon as possible is strongly recommended.

##### 3. Passive Drains

Use passive drains (e.g., Penrose) liberally in contaminated wounds or wounds that communicate with mucosal surfaces.

##### 4. IV Antibiotics and Tetanus Toxoid

Administer IV antibiotics and tetanus toxoid preoperatively.

##### 5. Inspection and Documentation

Inspect to the depth of the wound, and document the extent of the injury (nerve, duct, muscle, cartilage or vessel).

#### B. PRIMARY VERSUS DELAYED CLOSURE

##### 1. Closing Clean Wounds Primarily

Close clean wounds primarily, or as soon as practicable. In the head and neck, there is generally no advantage to delayed closure.

- Definitely treat all wounds within 24 hours whenever possible. Grossly contaminated wounds should be meticulously cleaned, debrided, and irrigated.
- When conditions prevent early closure, dress with saline-soaked gauze changed twice daily.
- Simple lacerations may be closed up to 3 days post-injury.
- Complex lacerations may be closed up to 2 days post-injury.
- Avoid closure under tension. Undermining uninjured skin or mucosa to effect a tensionless closure is acceptable.
- Mucosal closure of deep wounds or wounds that communicate with the neck should be at least two-layer closures and should be water-tight.

- Wound VAC (vacuum-assisted closure) dressings may be applied to water-tight wounds of the face, head, or neck that are not suitable for primary closure to facilitate wound contracture and enhanced closure by secondary-intent healing.

## 2. Avoiding Additional Incisions

Avoid additional incisions until a clear plan for later stages of reconstruction is developed. It is better to line the wounds with saline-dampened gauze changed twice daily and to delay closure for up to 72 hours while a definitive plan is made, rather than to make releasing incisions for local flaps that limit subsequent reconstructive options.

## 3. Reconstructing the Facial Framework Early

Scar contracture, which begins as early as 72 hours after injury, can make definitive soft tissue repair more challenging. According to Futran, enough underlying bone reconstruction should be performed to prevent contracture of the facial soft tissues.

- Temporary bone grafting may be performed in areas with unsatisfactory soft tissue coverage for interim stenting of the surrounding soft tissues.
- Locking reconstruction plate fixation of segmental mandibular defects may be performed until definitive bone reconstruction can be accomplished.
- Flap coverage may be required.

## C. LACERATION CARE AFTER REPAIR

- Keep laceration covered with petroleum jelly.
- Remove sutures in 3–5 days.
- Support skin edges with Steri-Strips™ for 2 weeks.
- Keep abraded lacerations covered with petroleum jelly for 2 weeks.
- Revise in 6–9 months.

## D. BITE WOUNDS

According to Akhtar et al., although bite wounds are likely to be contaminated, primary closure is still recommended for these wounds after thorough irrigation. They suggest that the result will be no worse if an attempt at closure is made, even if the wound eventually becomes infected, when compared with leaving the wound open to heal by second intention.

Broad-spectrum antibiotic administration is warranted and should be directed at a polymicrobial spectrum, including alpha-hemolytic streptococci, *Staphylococcus aureus*, and anaerobes.

## IV. Principles of Plating

### A. RECONSTRUCTIVE GOALS

Reconstructive goals include restoration of function (airway, mastication) and form (occlusion, facial height, and facial projection).

### B. TECHNICAL OBJECTIVES

#### 1. Stability at Each Fracture Site

Stability at each fracture site is essential. Fixation must overcome natural forces acting at the fracture site long enough for the bone to heal.

#### 2. Three-Point Fixation of Mobile Segments

Three-point fixation of mobile segments is optimal for stability and to distribute forces acting on the points of fixation (the screws engaging the bone). Plating systems provide this by using multiple screws, angled plates, locking plates, and multiple plates, or by engaging multiple cortices with one screw.

- If a single plate is used to fix bone fragments, using three screws on either side of the fracture is desirable.
- Bicortical screws add significant stability to a plating system, but risk damage to intervening structures (nerves, blood vessels, tooth roots).
- Locking plates that are not in direct contact with the bone effectively establish two points of fixation at every screw, adding stability. They have the additional advantage of permitting preservation of periosteal attachments to the bone, and the disadvantage of creating a higher profile beneath the covering skin or mucosa.

#### 3. Bone Fragment Contact

Bone fragment contact promotes neo-osteogenesis and bridging at the fracture. Compression plates were developed to enhance bone contact by drawing bone fragments closer together. These plates continue to have useful applications. However, “compressing” bone fragments has not proved more effective than ensuring passive contact and stability at the fracture site through use of locking plates.

### C. PLATING SYSTEMS

Two choices exist for craniofacial plating materials: metal and resorbable plating.

## 1. Metal Plating

Metal plating systems are most commonly titanium alloys with proven biocompatibility and strength. These systems all have generally analogous application, but are not interchangeable among manufacturers. Differences in alloy composition, plate hole sizes, and screw head/driver design prevent mixing systems.

## 2. Resorbable Plating

Bioabsorbable materials are most commonly high-molecular-weight polyalphanhydroxy acids: polylactic acid, polyglycolic acid, and polydioxanone. These systems also have generally analogous application but are not interchangeable.

- Experience is required in both selection and use of resorbable plating systems.
- Resorbable plating systems vary significantly in mechanical strength, handling characteristics, biodegradability, and absorption.
- The majority of absorbable plates currently on the market maintain 60-90 percent of their strength through the 3-month mark.
- Pediatric trauma absorbable systems are well suited for non-load-bearing regions in the upper and middle thirds of the face.

## V. References and Resources

Akhtar N, Smith MJ, McKirdy S, Page RE. Surgical delay in the management of dog bite injuries in children, does it increase the risk of infection? *J Plast Reconstr Aesthet Surg*. 2006;59(1):80-85.

Defense and Veterans Brain Injury Center. Accessed at: <http://www.dvbic.org> or [info@dvbic.org](mailto:info@dvbic.org).

Defense and Veterans Brain Injury Center. Patient Education Materials. Accessed at: <http://www.dvbic.org/Providers/DVBIC-Educational-Materials.aspx>.

Defense Centers of Excellence (DCoE) Clinical Recommendation. Indications and Conditions for Neuroendocrine Dysfunction Screening Post Mild Traumatic Brain Injury Clinical Recommendations. March 2012. Accessed at: [http://www.dcoe.health.mil/Content/Navigation/Documents/DCoE\\_TBI\\_NED\\_Clinical\\_Recommendations.pdf](http://www.dcoe.health.mil/Content/Navigation/Documents/DCoE_TBI_NED_Clinical_Recommendations.pdf).

Defense Centers of Excellence for Psychological Health and Traumatic Brain Injury. Accessed at: <http://www.dcoe.health.mil/ForHealthPros/TBIInformation.aspx>.

## CHAPTER 2: General Principles in Treating Facial, Head, and Neck Trauma

Defense Centers of Excellence for Psychological Health and Traumatic Brain Injury. Neuroendocrine Dysfunction Screening Post Mild TBI Reference Card. February 2012. Accessed at: [http://www.dcoe.health.mil/Content/Navigation/Documents/DCoE\\_TBI\\_NED\\_Reference\\_Card.pdf](http://www.dcoe.health.mil/Content/Navigation/Documents/DCoE_TBI_NED_Reference_Card.pdf).

Futran ND. Maxillofacial trauma reconstruction. *Facial Plastic Surgery Clinics of North America*. May 2009;17(2):239-251.

Garner J, Brett SJ. Mechanisms of injury by explosive devices. *Anesthesiol Clin*. Mar 2007;25(1):147-160. Accessed at: [http://www.mdconsult.com/das/clinicslist/view/331970541-11/issue/20434?ANC\\_HOR=589320&issn=1932-2275](http://www.mdconsult.com/das/clinicslist/view/331970541-11/issue/20434?ANC_HOR=589320&issn=1932-2275).

Gosain AK, Song L, Corrao MA, et al. Biomechanical evaluation of titanium, biodegradable plate and screw, and cyanoacrylate glue fixation systems in craniofacial surgery. *Plast Reconstr Surg*. Mar 1998;101(3):582-591. [Medline]

Grathwohl KW, Venticinque SG, Blackburne LH, Jenkins DH. The evolution of military trauma and critical care medicine: Applications for civilian medical care systems. *Critical Care Medicine*. Jul 2008;36(7)(suppl):S253-S254.

Hollier LH Jr. Facial trauma: General principles of management. *J Craniofac Surg*. Jul 2010;21(4):1051-1053. [Review]

Hunt JP, Weintraub SL, Marr AB. Kinematics of trauma. Chapter 7 in: Moore EE, Feliciano DV, Mattox KL, eds. *Trauma*. 6th ed. New York, NY: McGraw-Hill, 2008. Accessed at: <http://www.accesssurgery.com/content.aspx?aID=152803>.

Kerr AG. Blast injuries to the ear. *Practitioner*. 1978;221:677-682.

Leibovici D, Gofrit ON, Shapira SC. Eardrum perforation in explosion survivors: Is it a marker of pulmonary blast injury? *Ann Emerg Med*. 1999;34(2):168-172.

Murr AH. Maxillofacial trauma. Chapter 8 in: Lalwani AK, ed. *Current Diagnosis and Treatment in Otolaryngology-Head and Neck Surgery*. 2nd ed. New York, NY: McGraw-Hill Medical; 2008.

Ritenour AE, Baskin, TW. Primary blast injury: Update on diagnosis and treatment. *Critical Care Medicine*. Jul 2008;36(7)(suppl):S311-S317. [Review]

## Chapter 3: Upper Facial Trauma

Paul J. Donald, MD

G. Richard Holt, MD, MSE, MPH, MABE

### I. Frontal Sinus and Anterior Skull Base Trauma

#### A. INTRODUCTION

The implementation of the shoulder harness seat belt in motor vehicles has resulted in a much lower incidence of frontal sinus fractures. Because of the thick bone of the anterior wall of the sinus as well as its curved convexity, this first barrier to the effects of cranial trauma resists fracture. Considerable force—up to 1600 foot pounds of impact—is required to fracture the anterior wall.<sup>1</sup> This is almost twice as much as it takes to fracture the parasymphyseal area of the mandible and 50 percent more than is required to fracture the malar eminence of the zygoma. In contrast, the posterior sinus wall and floor are often paper-thin.

The sinus has a mid-line septum that divides it into two halves. The drainage connection to the anterior aspect of the middle meatus of the lateral nasal wall begins as a funnel-shaped structure at the anterior medial extremity of the insertion of the mid-line septum in the frontal sinus floor. The connection is actually a foramen in 22.7 percent of patients and a duct in 77.3 percent.<sup>2</sup>

The frontal sinus floor has an area of common wall with the orbital roof, superiomedially, and the posterior wall forms the anterior wall of the anterior cranial fossa. The posterior wall has a central spine that projects intracranially, upon which lies the superior sagittal sinus. This venous sinus begins as a superior extension of the dorsal nasal vein of the nose as it penetrates the foramen caecum. The sinus volume increases as it courses over the convexity of the brain (Figure 3.1).

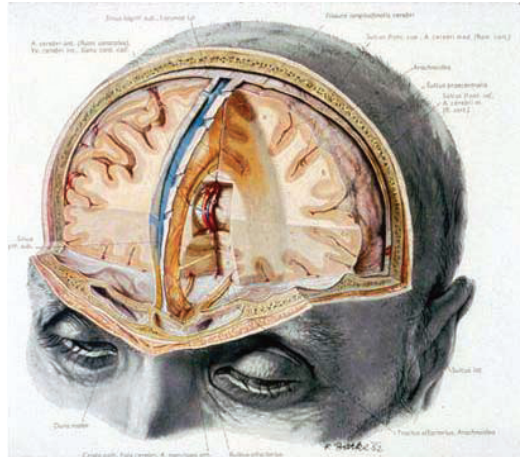
The frontal sinus mucosa has a peculiar characteristic of forming cystic structures when injured. These *mucocelles* have a tendency to erode bone probably as an osteoclastic response to the pressure exerted by the cyst.<sup>3</sup> If they become secondarily infected, they are called *pyocelles*.

Very often the patients presenting with a fracture of the frontal sinus are victims of violent crime, gunshot wounds, or industrial accidents. They commonly have multiple other, more immediately life-threatening injuries, so the sinus injury is often overlooked. Appropriate treatment of these fractures is essential, because of the potential for the formation of a frontal sinus mucocele or pyocele. With the proximity of the

**CHAPTER 3: Upper Facial Trauma**

**Figure 3.1**

Superior sagittal sinus.



posterior sinus wall to the anterior cranial fossa, these pathological entities can lead to the life-threatening complications of meningitis and brain abscess.

**B. CLASSIFICATION**

Some form of classification is necessary to describe the site and severity of injury, thus creating a meaningful treatment algorithm. First, the fractures should be classified according to site. As shown in Table 3.1, fractures can be further described according to their type. The classification system breaks down to a degree, because often multiple walls are fractured and some fractures are linear while others are displaced. The treatment plan should include addressing each individual site and each individual type of fracture.

**Table 3.1. Classification of Frontal Sinus Fractures according to Site and Type**

Step 1: Fracture Site Classification	Step 2: Fracture Type Classification
Anterior wall	Linear
Posterior wall	Displaced
Floor	Compound
Corner	Comminuted
Through-and-through	
Frontonasal duct	



## C. PRESENTATION

Since the patients have been struck with a good deal of force, many present in the emergency room in an unconscious state. The patient is emergently assessed, as outlined in Chapter 1. In the course of investigating for any central injury, a fractured frontal sinus may be apparent, but is often overlooked by virtue of the emergency stabilization and rapid evaluation required for a badly injured patient. The patient often has had an unconscious period and suffers headache. The infraorbital nerve may have been traumatized during the traumatic event, and the patient may complain of forehead numbness. There may be epistaxis, and the blood may be mixed with cerebrospinal fluid (CSF). Fractures involving the anterior wall may produce deformity.

### 1. Anterior Wall Fractures

Linear fractures of the anterior wall are often overlooked, but even if detected there would be no mandate to treat them. They may present with a subgaleal hematoma that resembles a depressed fracture because of its raised and irregular outline. Conversely, if the fracture is depressed, it will appear as a distinct depression in the area of fracture. However, if the patient is seen sometime after the occurrence of the injury, the depression may fill with blood, and the displaced area will be effaced.

Compound fractures are by definition in continuity with a forehead laceration. These fractures are often comminuted, and depressed bone fragments are seen in the depths of the cutaneous wound. Blood, CSF, and even brain may be seen coming through the laceration.

### 2. Posterior Wall Fractures

Isolated posterior wall fractures are very uncommon. If present, they are often part of a calvarial vault fracture. There are no presenting differentiating symptoms. The dilemma regarding treatment centers on distinguishing between a linear-only fracture versus a displaced fracture. Only a fine-cut computed tomography (CT) scan taken in the axial and sagittal planes will give enough definition to clearly establish or rule out displacement. When the physician is in doubt, the fracture should be treated.

A clear sign of a displaced posterior wall fracture is the presence of CSF rhinorrhea. If mixed with blood, the CSF leak can be identified by looking for the “halo sign.” A drop of nasal drainage is allowed to fall on a surgical towel. If the halo spreading from the central blood clot is more than double the width of the clot, then this is a sign of a CSF leak and thus an anterior dural tear.

### 3. Frontonasal Duct Fractures

Fractures of the frontonasal duct have no particularly distinguishing clinical diagnostic features and are usually picked up on a CT scan. Though the actual fracture may not be seen, an opacified frontal sinus that does not clear in 2 weeks raises a strong suspicion of disruption of the duct. The duct is often fractured as part of a Le Fort III maxillary fracture.

If at 2 weeks the sinus does not clear, a test can be done to establish patency of the duct. A small trephine hole in the floor of the sinus is made through a small incision in or just below the brow. The sinus is irrigated through the trephine with a saline solution containing cocaine or epinephrine. A solution containing methylene blue is instilled in the sinus, and the appearance of the dye in the middle meatus of the nose is observed with a sinus endoscope. The appearance of the dye indicates duct patency; the dye's absence is an indication for surgery.

### 4. Corner Fractures

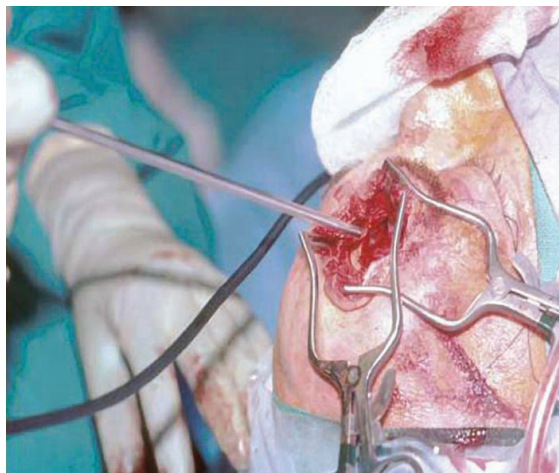
A corner fracture is usually not displaced. The anterior wall, floor, and posterior wall are fractured, and the corner fracture is normally in continuity with a more extensive fracture to the frontal bone. Corner fractures usually require no treatment.

### 5. Through-and-Through Fractures

The through-and-through fracture is the most serious of all frontal sinus fractures. It is a compound comminuted fracture involving the anterior and posterior walls, entering the anterior cranial fossa (Figure 3.2). The skin is torn—often extensively, the dura is ripped, and the frontal lobes

**Figure 3.2**

Endoscopic inspection of the frontonasal duct. View through fractured anterior wall of trephine.



are lacerated and contused. The patients are usually the victims of polytrauma. Approximately 50 percent of patients die at the scene of the injury or in the first 24 hours of hospitalization.

Characteristically the head and neck surgeon does not meet the patients until they arrive in the operating room at the behest of the operating neurological surgeon, who is busy stopping intracerebral bleeding and debriding the wound. A bicoronal scalp incision has already been made, the fractured skull fragments have been removed, and the injury has been exposed. Although one might think that the frontal sinus fracture is the least of the patient's worries, in fact, if not managed properly and the patient survives the initial injury, it will sit as a ticking time bomb, forming a mucocele that eventually causes a brain abscess or meningitis.

#### **D. MANAGEMENT**

Many frontal sinus fractures come to the emergency room with fractures of multiple walls. However, each site presents unique problems that invoke a specific solution or a choice of solutions in order to appropriately address the injury. In fractures of multiple walls, the final treatment must address the idiosyncracies of each site.

##### **1. Anterior Wall Fractures**

Nondisplaced frontal sinus fractures do not require any surgical intervention. Displaced fractures should be reduced for two principal reasons. The most important is that if there is any entrapped mucosa between the edges of the fracture, there is the potential to develop a mucocele. The second reason is to prevent the inevitable deformity of a dent in the forehead that will result if the displaced fragment is not properly reduced.

If the fracture is compounded, it can sometimes be reduced through an overlying laceration. If the laceration is too small to effectively reduce the fracture, then additional exposure can be gained by extending the laceration horizontally along a natural crease line in the forehead skin. The two other incisions that can be used are the "gull-wing" or "butterfly" incision in a glabellar crease connected to the upper medial aspects of the eyebrows. This incision is best applied in patients with short sinuses or in bald men. The coronal scalp flap provides the best surgical exposure and is the most commonly used.

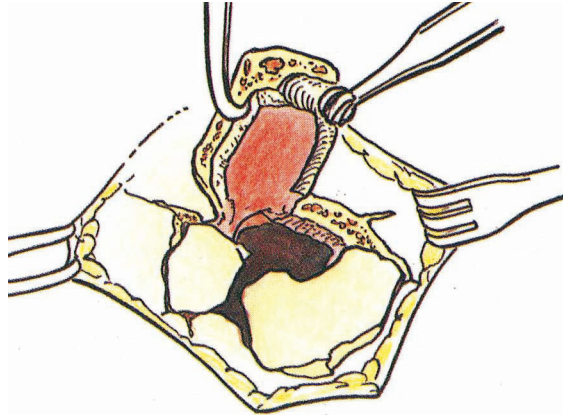
The fracture fragments are disimpacted with a stout bone hook and, as much as possible, the bone fragments are left with periosteum as a vascular pedicle. A mucosal strip adjacent to the fracture is incised and

## CHAPTER 3: Upper Facial Trauma

removed, and a thin layer of the underlying bone is resected with a diamond bur (Figure 3.3). The fracture fragments are fixed in place with a series of miniplates and square plates.

### Figure 3.3

Mucosa and bone are removed from the margins of the fracture fragments.



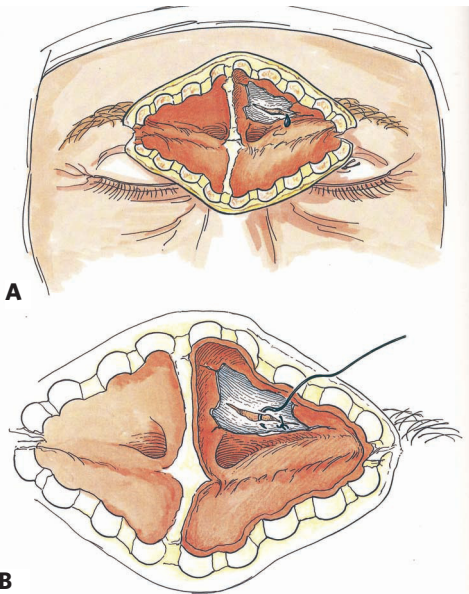
## 2. Posterior Wall Fractures

Management of posterior wall fractures is the most controversial of all the fracture sites. The major issue is whether the fragments are displaced. With the advent of fine-cut CT scanning, this dilemma is more easily resolved.

Linear fractures can be safely observed. The detection of displacement as well as an idea of the patency of the frontonasal duct can be determined by making a small trephine hole in the sinus floor through the upper lid and passing an angled telescope through the trephine hole. Posterior wall displacement as well as the presence of a CSF leak can be determined.

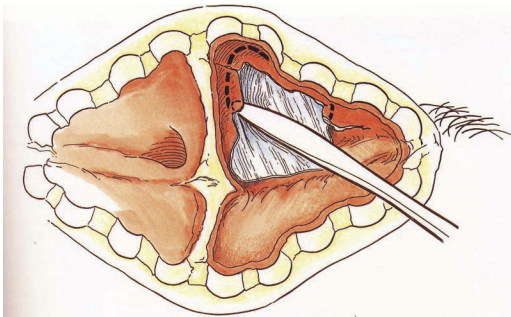
If any doubt concerning posterior wall displacement exists, frontal sinus exploration is indicated. This is usually done through a coronal scalp incision, then creating an osteoplastic bone flap of the anterior wall of the frontal sinus. A clear view of the interior of the sinus is obtained, and any disruption of the posterior wall is identified. If a CSF leak is seen, the limits of the anterior fossa dural rent are exposed by removing posterior wall bone. The dural tear is closed with interrupted sutures, and the area is reinforced with a patch of fascia lata or temporalis fascia (Figures 3.4 and 3.5).

If an area of bone greater than 2 centimeters in diameter is removed, the anticipated sinus drillout and obliteration with fat are abandoned, and a frontal sinus cranialization procedure is performed. If fat grafting



**Figure 3.4**

Suture of dural laceration in posterior wall frontal sinus with CSF leakage. (A) Dural laceration. (B) Fractured bone debrided until limits of dural rent are apparent; tear is sutured with interrupted sutures.



**Figure 3.5**

Fascia graft being tucked into position to stem CSF leak in a posterior wall fracture.

and obliteration of the sinus are preformed, then careful attention to complete removal of all mucosa is mandatory. The drilling of the bone of the interior of the sinus is essential to remove all remnants of mucosal lining prior to obliteration of the sinus cavity with a carefully harvested abdominal wall fat graft.

### 3. Frontonasal Duct Fractures

Fractures to the outflow tract from the frontal sinus are very difficult to diagnose. There are no idiosyncratic signs or symptoms that are manifested in these fractures. When suspected by retained fluid in the sinus after a 2-week period of observation or demonstration of such a fracture on the facial CT scan, the frontal sinus must be addressed.

## CHAPTER 3: Upper Facial Trauma

The sinus can be managed either endoscopically or by an open operation. The reestablishment of ductal patency has thwarted frontal sinus surgeons for over 100 years.<sup>4</sup> All methods of opening the frontal sinus floor to the nasal cavity have been attempted with varying degrees of success. Currently, the use of the Draf III endoscopic version of the Lothrop operation<sup>5</sup> has become very popular. The two classic open techniques are the Lynch operation using the Sewell-Boyden flap to line the widely open tract, and the osteoplastic flap procedure with fat obliteration.

The Draf III uses classical fiberoptic endoscopic evaluation of swallowing (FESS) techniques to remove the frontal sinus floor, the superior part of the nasal septum and the so-called “beak” area of the anterior frontal sinus floor. Because the technique causes a minimum amount of trauma in the resection area, theoretically, the opening is more likely to stay open.

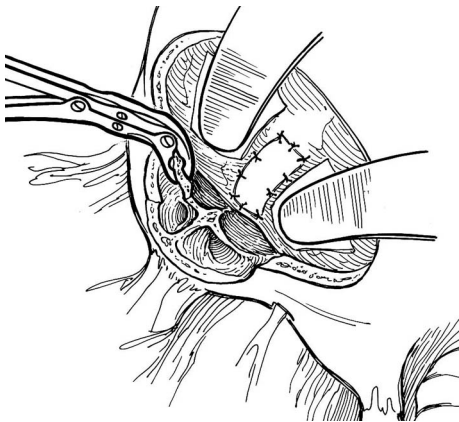
The Lynch operation uses a curvilinear incision starting in the medial brow, and courses through the so-called “nasojugal area,” half way between the medial canthus of the eye and the mid-line of the nasal dorsum. The ethmoid sinuses and the entire area of the frontonasal duct, as well as the floor of the frontal sinus, are removed. The Sewell-Boyden flap is constructed from the nasal septum medially or the lateral nasal wall anterior to the turbinates. The flap is then used to line the opening in the frontal sinus floor. The most reliable way to repair a duct fracture is to eliminate the frontal sinus entirely with the osteoplastic flap and fat obliteration procedure.

### 4. Through-and-Through Fractures

This devastating injury was formerly managed by the neurosurgeon by craniectomy, often discarding the skull fragments because of their contamination at the scene of the accident, and not cleansing them and restoration of the cranial vault because of the concern of brain swelling. The otolaryngologist classically did a Riedel ablation, with the two procedures leaving the patient with unprotected brain as well as a significant cosmetic defect.

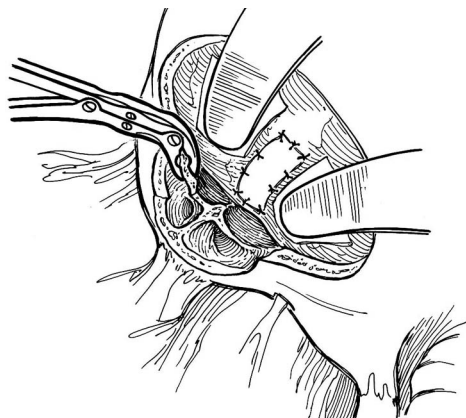
In 1975, Donald and Bernstein<sup>6</sup> and Derome and Merville<sup>7</sup> described the cranialization procedure for these through-and-through fractures. The neurosurgeon controls the intracranial problems by stopping the intracranial bleeding, debriding necrotic brain, and providing a water-tight dural repair.

The otolaryngic procedure regarding the frontal sinus injury is made easy by virtue of the extensive craniotomy needed for controlling the intracranial injury. The initial step in the procedure is to ensure all the bony fragments from the anterior wall of the frontal sinus have been saved. These are divested of dirt and soaked in Betadine® until the end of the procedure. The posterior wall of the sinus is completely removed, so that the cavity of the frontal sinus is now in continuity with the anterior cranial fossa. This is begun with a double-action rongeur and is finished off with a cutting burr (Figure 3.6). The frontal sinus mucosa is now completely stripped out with an elevator from the floor and remaining anterior wall, such that the remaining sinus cavity is completely divested of mucosa. Total removal of all mucosal remnants of the sinus is ensured by removing 1–2 millimeters of bone with a cutting burr (Figure 3.7).



**Figure 3.6**

Cranialization procedure—Brain is debrided, dura is patched, and posterior wall remnants are removed with double-action rongeur.



**Figure 3.7**

Cranialization procedure—Removal of the remaining posterior wall of the frontal sinus produces cranialization.

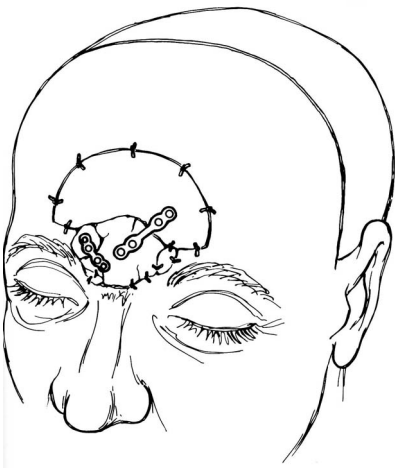
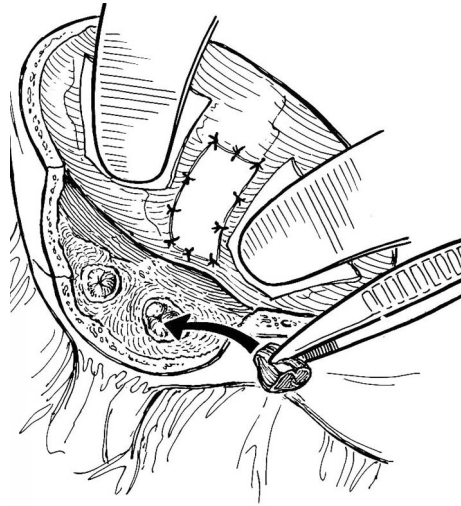


### CHAPTER 3: Upper Facial Trauma

The frontonasal duct is eliminated by inverting the frontal sinus mucosa left in the funnel-shaped entrance to the duct upon itself, and then obliterating the duct with a block of temporalis muscle (Figure 3.8). The cleansed anterior wall fragments are similarly divested of all their mucosa with a cutting bur, and then fixed in place with square plates and miniplates (Figure 3.9). The scalp is closed and a light-pressure dressing is applied.

**Figure 3.8**

Cranialization procedure—The mucosa of the sinus is removed from the sinus lumen, the frontonasal duct mucosa is inverted on itself, and the frontonasal ducts are plugged with temporalis muscle.

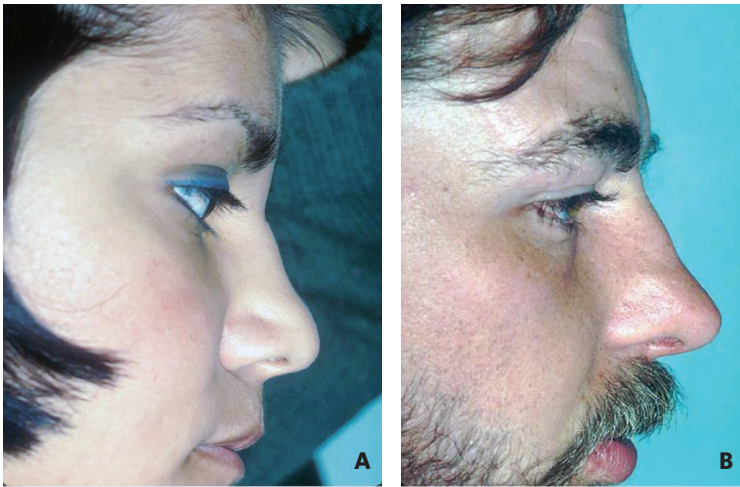

**Figure 3.9**

Cranialization procedure—Craniotomy returned with wire and fragments of the frontal sinus fixed with plates.



The dead space resulting from the enlargement of the anterior fossa rapidly fills with blood, but usually there is some degree of residual hydrocephalus. Early brain edema will add to the effacement of the space. The brain slowly advances into the space with time, as the dural graft stretches and the dead space is eliminated in about 3 months. The frontal sinus is thus eliminated as a potential source of infection, and the esthetic contour of the forehead is preserved (Figure 3.10).



**Figure 3.10**

Two patients, (A) 2 years and (B) 4 years post-cranialization.

## II. Naso-orbital-ethmoid Fractures

Fractures of the naso-orbital-ethmoid (NOE) region are typically due to blunt trauma injuries. Etiologies may range from motor vehicle accidents to falls and sports, but the force and focus of the blow determine the extent of the injuries to the structures located in this region of the face, including the orbital contents and the anterior skull base structures. The extent of the injuries, based on physical examination and imaging studies, will determine the urgency and type(s) of surgical interventions required. As with all facial injuries, a thorough knowledge of three-dimensional facial anatomy is a requirement, as is an understanding of the diagnostic tests and modalities utilized in diagnosing the injuries of NOE trauma. NOE fractures can be isolated, but are usually part of a panfacial set of fractures and injuries.

## CHAPTER 3: Upper Facial Trauma

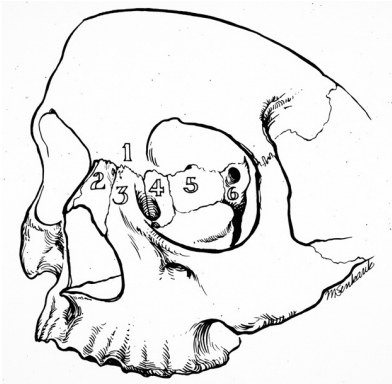
### A. ANATOMIC STRUCTURES OF THE NOE COMPLEX

NOE fractures can involve damage to multiple important osseous, vascular, cranial nerve, and supporting structures located within the NOE complex, including:

- Nasal bones (Figure 3.11).
- Perpendicular plate of the ethmoid/septum.
- Nasal process of the frontal bone.
- Cribriform plate and olfactory nerve.
- Lamina papyracea, medial orbit, ethmoid sinus.
- Orbital fat, medial rectus muscle, superior oblique muscle with trochlea.
- Ethmoid arteries, ethmoid nerves.
- Medial canthal attachments (Figure 3.12).
- Lacrimal fossa, lacrimal sac, superior and inferior canaliculi, superior portion of the nasal-lacrimal duct (Figure 3.13).
- Nasal process of the maxilla and lateral-superior nasal wall.

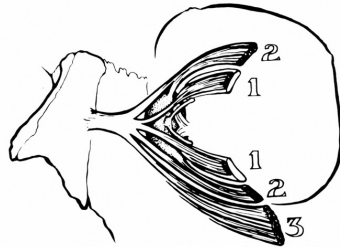
**Figure 3.11**

NOE pertinent osteology—(1) nasal process of frontal bone; (2) nasal bones; (3) nasal process of maxilla; (4) lacrimal bone; (5) lamina papyracea; (6) lesser wing of sphenoid bone.



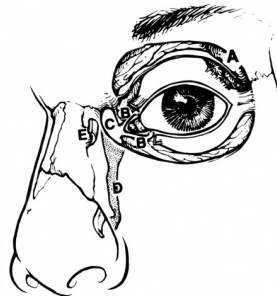
**Figure 3.13**

Nasal lacrimal system anatomy—(A) lacrimal gland; (B) superior and inferior canaliculi; (C) lacrimal sac; (D) nasolacrimal duct; (E) reflected anterior slip of medial canthal tendon.



**Figure 3.12**

Anterior and posterior slips of the medial canthal tendon surrounding the lacrimal sac—(1) pretarsal orbicularis muscle; (2) preseptal orbicularis muscle; (3) preorbital orbicularis muscle.



## B. INDICATIONS OF INJURY TO THE NOE COMPLEX STRUCTURES

In general, the subjective symptoms and objective signs of injuries to the NOE complex will reflect the pathology evidenced by the specific structures that are injured.

### 1. Symptoms (Subjective)

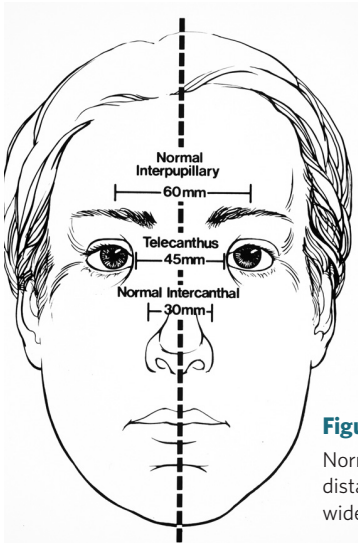
The subjective symptoms of injuries to the NOE complex include the following:

- Diplopia.
- Nasal stuffiness.
- Epistaxis.
- Visual disturbances.
- Pain.
- Dizziness, vertigo.
- Anosmia.

### 2. Signs (Objective)

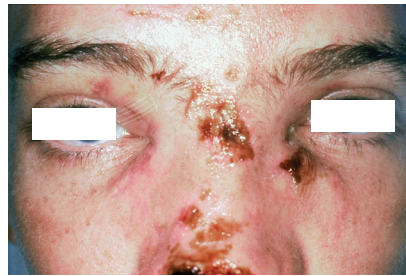
#### a. Traumatic Telecanthus

The average interpupillary distance is 60–62 millimeters (mm), which corresponds to an intercanthal distance of approximately 30–31 mm. The diagnosis of traumatic telecanthus requires a measurement in excess of those normative values (Figures 3.14 and 3.15). The pathology can be either unilateral or bilateral, with the former more difficult to measure.



**Figure 3.14**

Normal interpupillary and intercanthal distances, and traumatic telecanthus widening.



**Figure 3.15**

Patient demonstrating traumatic telecanthus with splaying of the NOE complex.

## CHAPTER 3: Upper Facial Trauma

### **b. Diplopia**

Double vision elicited on extraocular motion in the cardinal positions of gaze can be due to injuries to the medial rectus muscle, superior oblique muscle and/or trochlear slip, oculomotor nerve, trochlear nerve, and entrapment of medial orbital structures into a fracture of the lamina papyracea. Nerve injury is usually a neuropraxia, so if forced duction tests are normal, observation is warranted.

### **c. Nasal Stuffiness**

Nasal stuffiness occurs with blood in the nasal cavity; septal hematoma (which is less likely with injuries of the bony perpendicular plate of the septum than the cartilaginous septum); compression of the upper nasal passages, with infracturing of the nasal bones; and generalized mucosal edema.

### **d. Epistaxis**

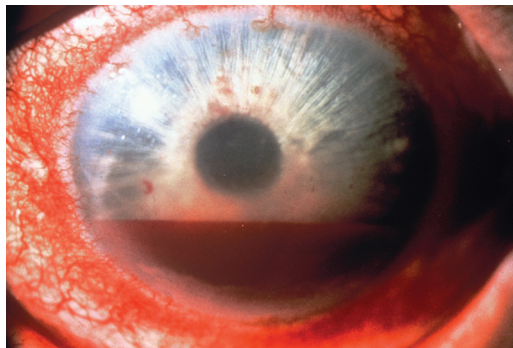
Epistaxis is quite common with NOE fractures. It usually represents the disruption of the nasal mucoperiosteum caused by the blunt trauma or shearing forces and displaced bony fractures. Severe epistaxis may indicate disruption of the ethmoid arteries and/or the sphenopalatine arteries; the latter is less likely, due to the more inferior location of the sphenopalatine arteries in the nasal cavity.

### **e. Visual Disturbances**

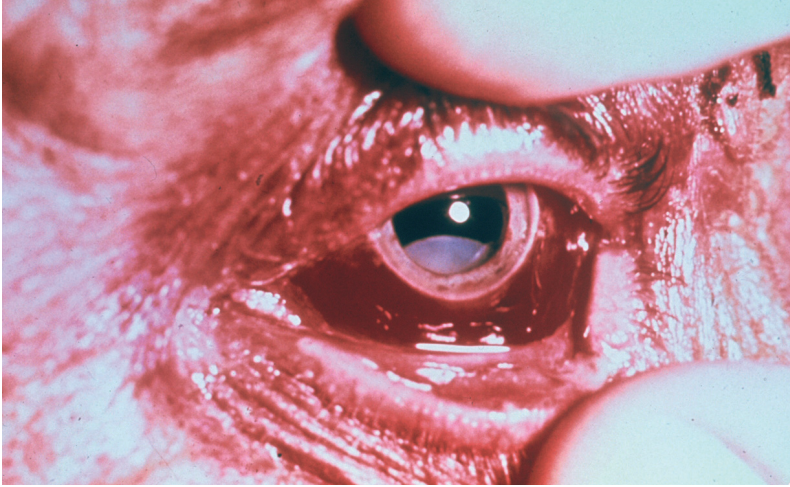
Visual disturbances are common with NOE fractures. They are often due to orbital edema, periocular swelling, and injury to the medial orbital muscles and nerves. Non-diplopia signs include a dilated pupil or Marcus-Gunn pupil, indicating injury to the optic nerve. The cornea may be disrupted, abraded, or lacerated, and hyphema (Figure 3.16) is very common with blunt mid-facial trauma. A dislocated ocular lens is rare,

**Figure 3.16**

Hyphema of the globe is seen as layered blood in the anterior chamber.



but possible (Figure 3.17). Rupture of the globe is also a rare, but devastating, injury.



**Figure 3.17**

Dislocated lens seen displaced to inferior portion of anterior chamber of the globe.

#### ***f. Imbalance***

Imbalance may be present in patients with NOE injuries, primarily in patients with serious trauma to the face that can cause a concussion, anterior skull base contusion, cerebral edema, or injury to the medial longitudinal fasciculus. Contrecoup injuries to the brainstem and vestibular/cerebellar pathways may have occurred; these signs are ominous for more serious intracranial pathology. Nystagmus may be a feature of contrecoup trauma.

#### ***g. Anosmia***

Anosmia is another worrisome sign. If the patient fails to perceive the smell of common scents, such as soap or alcohol, further investigation is warranted. The cause may simply be an accumulation of blood, mucus, and swollen nasal membranes, but could also be due to a disruption of the olfactory nerve at the level of the cribriform plate. If this injury is suspected, the patient should be tested for CSF rhinorrhea, using filter paper in the front-leaning-head position or collected and tested for beta-2 transferrin.

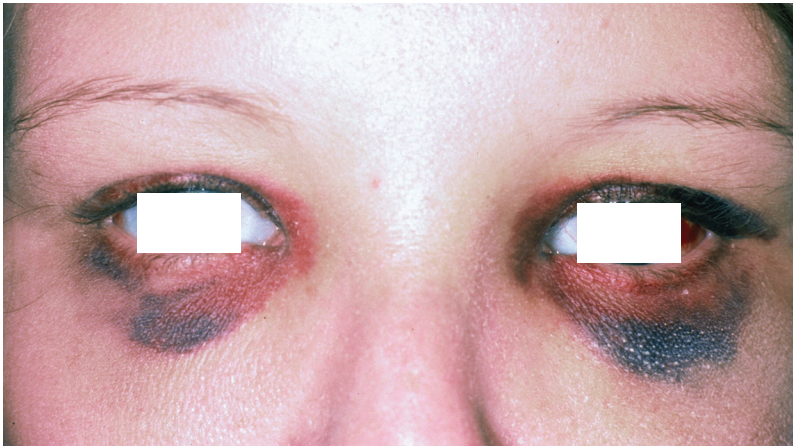
## CHAPTER 3: Upper Facial Trauma

### ***h. Periorbital Ecchymosis***

Periorbital ecchymosis (“raccoon eyes”) is a common indicator of ruptured blood vessels—usually the ethmoid arteries and/or the angular artery and vein near the medial canthus (Figure 3.18). It can also be suggestive of a basilar skull fracture, which must be ruled out through diagnostic imaging.

#### **Figure 3.18**

Bilateral periorbital ecchymoses.



### ***i. Retrobulbar Hematoma***

Retrobulbar hematoma is a very serious condition, in which periglobal blood vessels have been ruptured and blood accumulates around or within the muscular cone. The patient will complain of pain, decreasing vision, and pressure, and may have nausea and vomiting. There will be obvious proptosis and a firm globe to gentle palpation, compared to the normal side.

This is a true emergency. Ophthalmologic consultation is mandatory. However, owing to the laxity that generally occurs with a lateral splaying of the medial canthal tendons, there is a natural release to the intraorbital pressure caused by the expanding hematoma. Nevertheless, this will not last long, and intervention should be undertaken as soon as diagnosed.

### ***j. Epiphora***

Epiphora is usually due to tissue edema surrounding the medial eyelids. However, fractures and soft tissue injuries involving the lacrimal

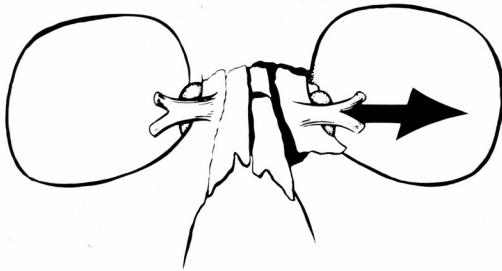


drainage system will produce epiphora, which requires further evaluation with lacrimal probing at the time of the surgical repair.

### C. CLASSIFICATION OF MEDIAL CANTHAL TENDON INJURIES

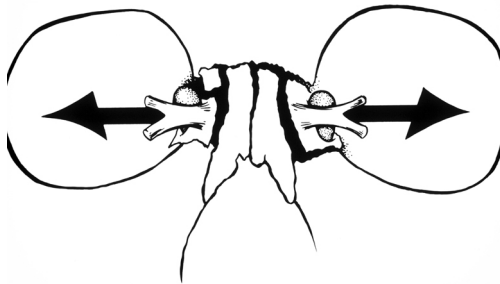
Medial canthal tendon injuries are classified according to three types:

- **Type I:** Single-fragment bone segment with intact canthal tendon insertions (Figure 3.19).
- **Type II:** Comminuted central bone segment with fractures remaining external to the medial canthal tendon insertion (Figure 3.20).
- **Type III:** Comminuted single fragment with fractures extending into bone bearing the canthal insertion.



**Figure 3.19**

Type I medial canthal region fracture, unilateral.



**Figure 3.20**

Type II medial canthal region comminuted fracture, right medial orbit.

The injury type can be identified on imaging studies and confirmed at surgical exploration and repair.

Though uncommon, blunt trauma can also result in a rupture of the anterior and/or posterior insertions of the canthal slips near their insertion on the lacrimal fossa. It would be seen in the lax eyelid, without evidence of distracted lacrimal fossa fractures.

### D. LACRIMAL SYSTEM INJURIES

Laceration of the medial eyelids with discontinuity of the lacrimal canaliculi will be seen in vertical lacerations medial to the puncta. Deep

## CHAPTER 3: Upper Facial Trauma

horizontal lacerations at the medial canthus can also disrupt the canaliculi but are less common.

Fracture(s) that involve the lacrimal fossa can rupture the lacrimal sac or avulse the common canaliculus from the lacrimal sac. This may only be identified by inserting a lacrimal probe into the system via the upper and/or lower puncta and noting a failure of the probe to pass easily into the lacrimal sac.

The floor of the lacrimal fossa contains the opening to the superior portion of the lacrimal duct. Fractures involving this region can be subtle. Unless identified on imaging or suspected from the location of the fractures, they can be overlooked, leading to persistent epiphora.

Identifying patency of the nasolacrimal system after NOE injuries usually necessitates performing primary and secondary Jones dye tests.

### 1. Primary Jones Dye Test

#### a. Test Procedure

- Instill one drop of fluorescein in the inferior cul-de-sac of the lower eyelid
- Insert a cotton pledget minimally soaked in a topical anesthetic, such as 2 percent lidocaine beneath the inferior turbinate.
- After 5 minutes, remove the pledget and examine for fluorescein.

#### b. Interpreting Test Results

- If fluorescein is present, then this is a positive primary Jones dye test, indicating that the lacrimal drainage system is patent.
- If fluorescein is not present, this is a negative primary Jones dye test, and further testing is required to determine the level of obstruction.

### 2. Secondary Jones Dye Test

#### a. Test Procedure

- Place a clean cotton pledget beneath the inferior turbinate.
- Flush the fluorescein from the cul-de-sac with saline.
- Irrigate the lacrimal sac via the inferior canaliculus using a special blunt canalicular needle and syringe.

#### b. Interpreting Test Results

- If fluorescein is identified on the fresh pledget, then this is a positive secondary Jones dye test, indicating a functional obstruction in the nasolacrimal duct.
- If no dye is present on the pledget, but saline is observed, then this is a negative secondary Jones dye test, indicating pathology at the lacrimal punctum or canaliculus.



- If no saline is observed after irrigation, there is a complete blockage of the nasolacrimal system at some level, which should be obvious from the extent of the traumatic pathology.

## **E. ISOLATED ORBITAL FRACTURES**

Typically, orbital fractures in NOE injuries are isolated to the region of the lamina papyracea and inferior-medial orbit. While medial orbital fractures can result in entrapment of periosteum, fat, and ocular muscle, it is not common because of the lack of gravitational force and because the ethmoid cells provide an additional support to the lamina. When entrapment does occur, it must be differentiated from a neuropraxia of the oculomotor nerve to the medial rectus by forced duction testing.

## **F. DIAGNOSTIC EVALUATIONS**

### **1. Full-Body Trauma Assessment**

Like most patients with facial trauma, it is usually necessary for the trauma team to clear the patient from more serious injuries before the full evaluation and decision-making process on the facial trauma can take place. This includes the full-body trauma assessment, particularly of the circulation, airway, breathing, and neuro status, as well as the remainder of the bodily assessment. It is helpful for the otolaryngology resident to be present for this total body trauma assessment, as positive findings will impact the evaluation and treatment of facial fractures. Additionally, after the primary and secondary assessments, the otolaryngology resident will be able to focus specifically on a detailed head and neck examination.

### **2. Head and Neck Examination**

Particularly pertinent to NOE injuries, the head and neck examination should closely assess neurological status, nasal airway, vision (including pupillary examination and range of motion), CSF leak, epistaxis, nasal airway patency, and eyelid tension. Eyelid tension, when tested with the “bowstring test,” may demonstrate a laxity of the medial canthal tendon when the eyelid is grasped by eyelashes and pulled laterally. A normal attachment of the medial canthal tendon will demonstrate a firm resistance to distraction, while a disrupted attachment will feel lax. Since isolated NOE fractures are not common, but more often are a part of panfacial fractures, the entire facial skeleton must be adequately evaluated.

### **3. Ophthalmological Evaluation**

Any trauma at or around the orbit justifies an ophthalmological evaluation, preferably before any surgical procedure is planned. An

## CHAPTER 3: Upper Facial Trauma

undiagnosed ocular or periocular injury could further jeopardize vision through incomplete evaluation and premature surgery. In particular, the presence of a hyphema in the anterior chamber, dislocated lens, corneal or scleral laceration, or retinal injury will require postponement of the surgical procedure until the eye is cleared by the ophthalmologist.

### 4. Inspection of the Nasal Interior

Inspection of the nasal interior, particularly the superior and superior-posterior aspects, should be performed with a rigid or flexible nasal scope after suctioning and decongestion. It is important to identify any areas of obvious hematoma, tearing or rents of the mucosa, and intranasally exposed bone. Additionally, after decongestion (preferably with cotton pledgets), the patient's sense of smell can be tested with a common scent or a scratch-and-sniff test. Care should be taken during the examination to avoid the immediate area of the cribriform plate.

### 5. Interpupillary and Intercanthal Distance Measurements

The interpupillary and intercanthal distances should be measured to determine if traumatic telecanthus is present (see section II.B.2.a, above). If the intercanthal distance is significantly widened, and not thought to be just soft tissue edema or hematoma, there is a good chance that the lacrimal drainage system has also been disrupted.

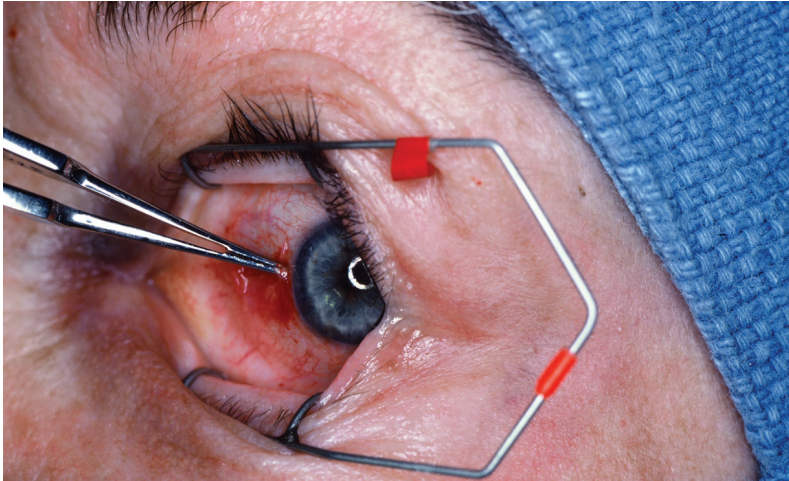
### 6. Imaging Studies

Imaging studies are clearly indicated in patients with NOE injuries. A head CT scan may have already been performed by the trauma or neuro team. Nevertheless, it is important to assess the NOE complex and anterior base of the skull well with fine cuts. If the head and neck examination raises a suspicion of additional facial injuries, then a complete facial bone series would be in order. Both soft tissue and bone windows for the CT scan of the face and anterior skull base will be helpful to identify injuries to the orbit, medial canthal region, cribriform plate region, floor of the frontal sinus (outflow), and periorbital structures. Additionally, the integrity of the lacrimal fossa and nasolacrimal duct can be assessed.

### 7. Forced Duction Testing

Forced duction testing after application of topical ophthalmic anesthetic will be very helpful in differentiating true entrapment of medial orbital structures from neuropraxia and muscle edema and contusion. This test is usually performed preoperatively to ascertain whether a surgical procedure to reduce the entrapped tissues will be required. After application of topical anesthesia (tetracaine hydrochloride 0.5 percent ophthalmic solution), which takes effect usually within 15 seconds, the

region of the attachment of the medial rectus muscle to the sclera is grasped with a fine-toothed ophthalmic forceps (Figure 3.21). The globe is then rotated laterally to determine whether there is resistance to, or



**Figure 3.21**

In forced duction testing, the area of the insertion of the medial rectus muscle to the sclera is grasped with a fine-toothed forceps and rotated laterally.

limitation of, rotation. If there is resistance or limitation, in comparison to the uninjured side, entrapment of the muscle is presumed. If patients have difficulty keeping their eyelids open, then a wire eyelid speculum (retractor) can be used. In combination with imaging evidence of entrapment, the forced duction test is indication for medial orbital exploration.

### **8. Plain Radiographs of the Face**

Plain radiographs of the face are rarely helpful, unless no sophisticated imaging system is available at the site of the patient's initial evaluation. A complete head and neck examination will be of more benefit than plain radiographs in developing a differential diagnosis of the patient's injuries. However, if the CT scanner is not available, then a Caldwell view of the facial bones is better than no imaging as a screen for disruption of the NOE complex.

### **9. Digital Photographs**

Finally, with the patient's permission, if the resident and site have the capability, digital photographs should be taken and stored in a secure place according to the Health Insurance Portability and Accountability

## CHAPTER 3: Upper Facial Trauma

Act of 1996 (HIPAA) regulations. These photographs are invaluable for planning the patient's subsequent secondary reconstruction, if needed, and for teaching and educational purposes. Each hospital facility generally has guidelines and rules for operative photography; typically hospitals ban using cell phone photography. A dedicated patient photography camera should be used. Using digital photography has multiple benefits, including planning the surgical procedure with the attending otolaryngologist, documenting injuries for possible subsequent legal proceedings (assault and battery), planning follow-on reconstructive procedures, and using the images for medical education.

### G. SURGICAL MANAGEMENT

#### 1. Indications for Surgery

- Compressed NOE complex.
- Traumatic telecanthus (widened NOE complex), unilateral or bilateral.
- Persistent epistaxis, despite local hemostatic measures.
- Medial orbital fracture with entrapment demonstrated on forced duction testing.
- Fracture(s) seen on imaging studies of the floor of the frontal sinus, which could block outflow.
- Fractures of the NOE involving the medial canthal tendons.
- Disruption of the lacrimal fossa and superior nasolacrimal duct.
- Obvious injury to the region of the lacrimal canaliculi.
- Evidence of a developing retrobulbar hematoma, which requires urgent ophthalmologic intervention.
- CSF rhinorrhea due to a fracture of the cribriform plate or posterior wall of the inferior frontal sinus seen on imaging studies.

#### 2. Timing of Surgical Procedures

Fortunately, with NOE complex fractures, there is usually sufficient time before repair to adequately assess the patient's injuries, initiate intravenous antibiotic therapy, observe the patient if there is any concern about CNS symptoms or signs, and properly prepare the operating room for the procedures. This means that most NOE fracture patients will not need to be operated on immediately, but may wait up to 48 hours, if needed, for the best possible approach. Only conditions such as retrobulbar hematoma, unrelenting nasal bleeding, or a perforated globe will require urgent surgery.

#### 3. Surgical Exposure Options

Because most central facial fractures, such as NOE fractures, usually have nasal bleeding as a general component, the patient may have

swallowed a good deal of blood. This should be taken into consideration, as well as how long ago the patient ate and drank, when scheduling a reconstructive surgical procedure. If there is serious bleeding that will require intraoperative packing or clipping/cautery of an ethmoid or sphenopalatine artery, the patient may have to be intubated awake, followed by oral-gastric tube aspiration of stomach contents.

#### ***a. Primary Objectives of the Surgical Repair/Reconstruction of the NOE Complex***

- Stop nasal bleeding through compression and/or clipping/cautery of vessels as needed.
- Reduce the compressed and widened NOE bones and splint or fixate them into proper position. Reduce any fracture edges that may be involving the cribriform plate.
- Re-establish normal intercanthal distance and maintain it in proper position for healing, usually by internal fixation.
- Re-establish continuity to the nasolacrimal drainage system through closure of lacerations and internal stenting.
- Reduce medial orbital entrapped tissues, if present, while protecting the globe.
- Explore and repair frontal sinus floor and/or posterior sinus wall fractures as required.
- Re-attach the trochlea of the superior oblique muscle if it has been disrupted from its normal osseous/periosteal attachment.
- Re-establish a normal frontal and profile appearance to the NOE complex region.
- Repair any lacerations with a fine plastic closure, especially those that may be used for exposure of the fractures.
- Repair CSF leak at the anterior skull base, if conservative measures and time have not led to closure.

#### ***b. Multiple Surgical Approaches***

There are multiple surgical approaches to reconstruct the NOE complex fractures, depending on the extent of the injuries and the structures involved.

##### *i. Lacerations*

If one or more lacerations are located in the NOE complex, it may be possible to expose the fractures and associated injured structures through these lacerations. Often, the lacerations are not well placed and may need to be extended or entirely not utilized for exposure. A fine-plastic closure of the lacerations, whether used for exposure or not, will be necessary. It is usually best to defer plastic closure of the

## CHAPTER 3: Upper Facial Trauma

lacerations to the end of the operation, to prevent inadvertent dehiscence during repair of the bony fractures.

### *ii. Transconjunctival Approach*

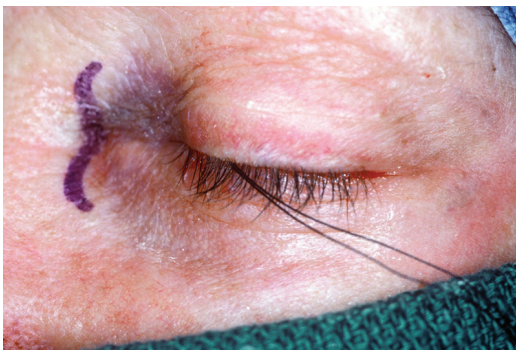
The transconjunctival approach can be utilized for isolated medial wall orbital blowout fractures with entrapment of a small amount of orbital fat or medial rectus muscle. The incision usually is placed posterior to the caruncle, and has very limited exposure to other sites of the NOE complex. However, if a medial orbital fracture is found to extend to the inferior orbital wall, this incision may be extended to expose that area.

### *iii. Transcaruncular Approach*

A transcaruncular approach is similar to the transconjunctival approach, except that the incision is placed anterior to the caruncle, which is elevated with the soft tissue flap. The medial orbital periosteum is incised just posterior to the posterior lacrimal crest, and the dissection carefully proceeds back to the posterior ethmoid artery. It provides a slightly better visualization of the medial orbit, but is insufficient to provide exposure for repair of more extensive fractures of the complex.

### *iv. Extended Medial Canthal/Lateral Nasal Approach*

An extended medial canthal/lateral nasal approach is often utilized to reduce and fixate the NOE complex fractures and to reconfirm the medial canthal tendons to their proper position. The incision is usually gull-wing shaped, placed approximately 8–10 mm from the inner palpebral angle, extending superiorly and inferiorly for approximately 15–20 mm (Figure 3.22). The periosteum can be elevated laterally, exposing the lacrimal fossa, medial orbit (lamina papyracea), and



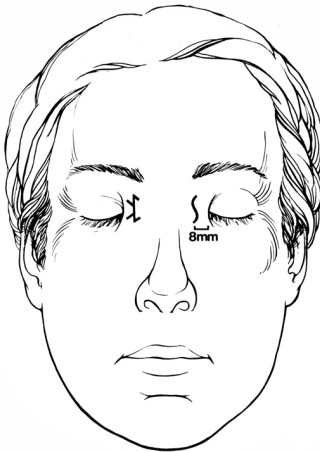
**Figure 3.22 (right)**

Gull-wing medial canthus incision in patient. Silk suture is around the body of the medial rectus muscle for traction in reducing entrapment.

ethmoid arteries (Figures 3.23 and 3.24). The exposure is sufficient to reduce medial orbit entrapments and fixate the intercanthal distance to the proper width (Figures 3.25 and 3.26). The incision can be extended superiorly (as with a Lynch incision) to expose the region of the trochlear slip, if that structure needs repair, or can be reattached to the superior-medial orbital wall. If the incision is extended much beyond 1 centimeter, it is wise to incorporate a small Z-plasty to reduce the risk of web formation in this concave anatomic area.

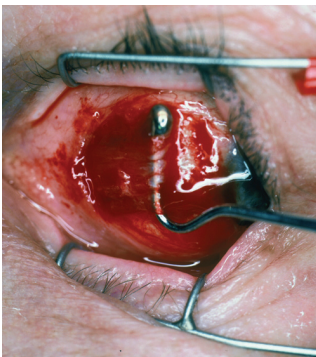
**Figure 3.23**

Medial canthal incisions to approach medial orbital fracture—double Z-plasty on the right, and gull-wing incision on the left.



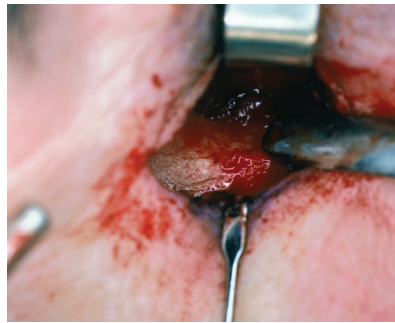
**Figure 3.25**

Traction on the medial rectus muscle to release entrapment in medial orbital fracture.



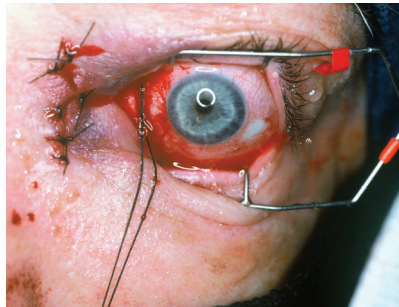
**Figure 3.24**

Exposure of the left medial orbital fracture for repair and release of entrapped orbital tissue, as viewed from patient's right side.



**Figure 3.26 (left)**

Completion of medial orbital repair and release of orbital contents.





## CHAPTER 3: Upper Facial Trauma

### *v. Bifrontal (Coronal) Forehead Flap*

For severe NOE fractures that involve the anterior skull base, nasal process of the frontal bone, inferior/anterior/posterior frontal sinus or that extend into the cribriform plate, it is usually necessary to approach the reconstruction through a bifrontal (coronal) forehead flap, elevating in the subperiosteal plane. This exposure will also allow for repair of an avulsed trochlea, and obliteration of the frontal sinus, if indicated.

### **4. Reconstructive Options**

The reconstruction of NOE injuries usually involves the reduction and fixation of the nasal bones, medial orbit, nasolacrimal system, and medial canthal tendons, with the goals to obtain near-normal appearance and function, as well as to reduce immediate and late complications.

#### **a. NOE Fracture Reduction**

Reduction of the NOE fractures in the operating room is normally a simple maneuver of manually compressing the splayed fractures at the level of the medial canthi to obtain a more normal intercanthal distance, based on half of the patient's interpupillary distance. Often, this reduction sufficiently produces adequate NOE anterior/profile projection, and the bones maintain their position without internal fixation. Only an external nasal cast may be required in most patients. Typically, the nasal bones will also be fractured inferior to the NOE complex, so these need to be reduced properly, as well, as described in Chapter 4 of this Resident Manual. It is also helpful to have decongested the nasal mucosa with topical oxymetazoline hydrochloride (0.25 percent), with or without 4 percent lidocaine hydrochloride, prior to the closed reduction.

#### **b. Nasal Bone Reduction**

During the closed reduction process, if the nasal and ethmoid processes of the frontal and maxillary bones have also been compressed posteriorly, it might be necessary to insert the blades of an Asch forceps into the superior nasal region to assist with the anterior distraction of the fragments. If the cribriform plate has been fractured, great care must be exerted during proper insertion of the forceps and the gentle distraction process, so as not to further violate this critical area.

#### **c. Techniques for Fracture Fixation**

If the NOE fractures are unstable, requiring internal stabilization—particularly to maintain the proper intercanthal distance—then several fixation options are commonly used.



### *i. Internal Transnasal Wiring*

Internal transnasal wiring can be applied after the medial canthal region has been exposed bilaterally. In the past, transnasal wiring was performed without necessarily exposing the bony fragments, with the wires tightened over skin buttons. This led to a high incidence of skin necrosis, so the preferred method currently is to use internal wiring.


Small holes are drilled adjacent to the anterior lacrimal crest and just superior to the posterior lacrimal crest, avoiding the lacrimal sac and common canaliculus. Stainless steel wire is then threaded through the holes, across the septum and back again to cerclage the NOE complex, tightening the wires after manual reduction to achieve the correct intercanthal distance. The wires will normally remain in place beneath the periosteum, unless they cause discomfort to the patient at a later date or become exposed.

### *ii. Low-Profile Miniplates*

The more preferred method of fixating the NOE fractures is to apply low-profile miniplates to the fracture sites after reducing the fractures and achieving proper intercanthal distances. The area for plate attachment is small, so 2-4 hole plates are usually the surgeon's choice. The plates will be secured in place with short screws, and caution is taken not to drill the holes too deeply to jeopardize the region of the ethmoid fovea or the cribriform plate. Exposure is normally gained for plate application through either a gull-wing incision medial to the attachment of the medial canthi, or a coronal forehead approach. It is important to plan the exposure incision well away from the plate, to lessen the risk of plate exposure. The plates may be left in place, unless they cause discomfort to the patient in the future.

### *iii. Polymer Canalicular Tube*

Reconstruction of a damaged lacrimal drainage system will likely require the insertion of a polymer canalicular tube (Figure 3.27).



**Figure 3.27**

Polymer canalicular tube stent for damaged lacrimal drainage system. Note the blunt metal tips for threading into canaliculi via the puncta.

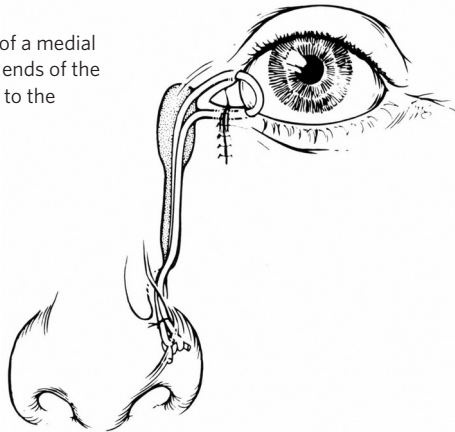
## CHAPTER 3: Upper Facial Trauma

Each end will have a thin, blunt wire tip that can be inserted into the superior and inferior puncta, with the wires manipulated through the canaliculi into the lacrimal sac, and thence into the nasal cavity via the nasolacrimal duct and inferior meatus.

The wires are brought out the nares, cut free from the tubing, which is then tied into a series of knots and sutured inside the lateral nasal vestibule. This effectively creates a loop, with the loop portion connecting the two puncta, allowing the discontinuous lacrimal system to heal over the tubular stent, which can be left in place up to 6 weeks. If there are associated lacerations of the canaliculi from a vertical medial eyelid wound, then these can be repaired over the tubular stent with fine absorbable synthetic suture (Figure 3.28). If the reconstruction of the lacrimal system is unsuccessful, depending on the location of the blockage, an endoscopic dacryocystorhinostomy may be required in the future for unacceptable epiphora.

### Figure 3.28

Lacrimal stent in place after repair of a medial canthal region laceration. Note the ends of the stent are tied together and sutured to the lateral nasal vestibule.



#### *iv. Elevating the Periosteum and Identifying Entrapped Orbital Tissue*

If there is a medial orbital wall fracture (lamina papyracea and ethmoid sinus complex), this area must be explored. Elevating the periosteum and identifying entrapped orbital tissue will normally be sufficient. It is important to recall that the anterior and posterior ethmoid arteries penetrate the lamina papyracea in mid-wall, and may need to be clipped or cauterized, preferably before they start bleeding. The optic foramen is located just behind the posterior ethmoid foramen, so care must be taken not to extend the exposure beyond this point in risk of damaging the optic nerve.

#### *v. Self-Seal after Reduction of the Fractures*

Most CSF leaks at the level of the cribriform plate will self-seal after reduction of the fractures. Consideration may also be given to placing the patient in the semi-upright position and inserting an epidural drain. For persistent leaks, an endoscopic approach to repair is usually successful.

### **H. PREVENTION AND MANAGEMENT OF COMPLICATIONS**

#### **1. Indications for Antibiotics**

Indications for antibiotics include any fractures that violate the integrity of the nasal or sinus mucosa, cause a pathway from the sinuses to the orbit or intracranial contents, or are present in a CSF leak. Since clinicians disagree about the use of antibiotics in small CSF leaks, residents should discuss this subject with their attending otolaryngologists.

A broad-spectrum antibiotic should be chosen, which is effective against the usual nasal and sinus pathogens. Special consideration should be given to patients who have a history of chronic or recurrent sinusitis with respect to the potential presence of drug-resistant organisms.

Antibiotic coverage need not extend past 5–7 days, unless the wounds become infected or an acute ethmoid or frontal sinusitis is detected.

#### **2. CSF Leaks**

As discussed above in section II.B.2.g, most CSF leaks will spontaneously resolve after repair of the NOE fractures. However, it may be necessary to repair the defect with an endoscopic tissue patch, septal flap, or anterior cranial fossa approach to the cribriform plate region with a dural patch or pericranial flap. CSF rhinorrhea due to a posterior-inferior frontal sinus-displaced fracture may be treated by obliteration of osteoplastic frontal sinus fat.

#### **3. Corneal Injuries**

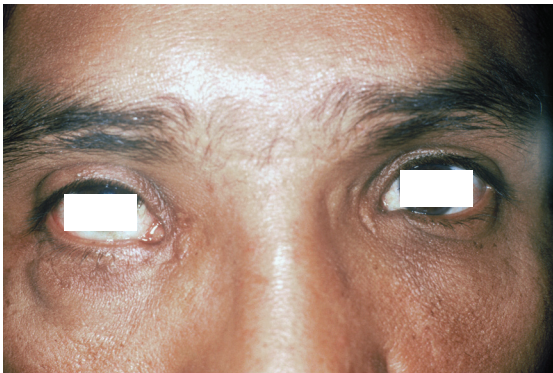A corneal laceration as a result of the blunt trauma will normally be managed by the ophthalmologist, and could delay the repair of NOE injuries until the specialist is satisfied that the cornea is healing satisfactorily. Abrasions are less likely to delay the repairs, but the ophthalmologist will likely wish to protect the cornea from further, inadvertent injury during the surgical procedure. Typically this will be achieved by placing a corneal protector on the globe before the surgery and removing it at the end of the surgery. Even in the absence of any corneal

## CHAPTER 3: Upper Facial Trauma

pathology, many surgeons prefer to apply a corneal protector for the security and safety of this tissue during fracture repair.

### 4. Lower Lid Abnormalities

Failure to adequately reconstitute the proper intercanthal distance through reduction and fixation of the bone to which the medial canthal tendons are attached can lead to lower eyelid laxity and ectropion. Depending on the severity of the ectropion, an additional lower lid shortening procedure may be required, with or without a medial canthal tendon tightening. Malposition of the medial canthus can also be a complication of poor repositioning of NOE fractures (Figure 3.29). Adequate time for healing and tissue firming should be allowed before recommending these procedures.



**Figure 3.29**

Malpositioned right medial canthus, with persistent right traumatic telecanthus and chronic epiphora due to eversion of the inferior punctum.

### 5. Persistent Telecanthus

One particularly common and troublesome complication is the inadequate reduction and fixation of the NOE fractures, leading to a persistently widened intercanthal distance and an unpleasant appearance to this area of the face. In a few patients, this could actually be a “pseudo-telecanthus,” where persistent soft tissue edema and scarring have given the appearance of a telecanthus.

A trial of gentle massage over time as well as consideration for steroid injections into the soft tissue (away from the canthal tendons) may be successful. If the telecanthus is due to inadequate narrowing of the NOE complex, then consideration can be given to the performance of osteotomies, reduction, and refixation. Because this procedure is difficult, the surgeon should have experience in its conduct.

### 6. Failure to Correct Medial Orbital Tissue Entrapment

Normally, exposing the medial orbital blowout fracture and releasing the tissue from entrapment will be sufficient to prevent subsequent fat

necrosis or persistent diplopia. However, for a large defect in the lamina papyracea, it may be helpful to insert a soft tissue graft, such as temporalis fascia “tucked” between the orbital periosteum and the defect, to prevent future internal prolapse. If entrapment persists after initial reduction, a repeat CT scan of the facial skeleton with soft tissue window may indicate the extent of tissue entrapment. A repeat exploration and repair may be indicated.

### **7. Persistent Diplopia**

Diplopia that was present preoperatively due to entrapment may persist for several weeks to months post-repair, owing to persistent edema of the medial orbital structures and the contraction of scar tissue. If the diplopia persists, then inadequately reduced entrapment may be present (see section II.H.6, above), or there may be an undiagnosed neurological injury to the oculomotor nerve or trochlear nerve.

The patient should be evaluated by a neuro-ophthalmologist. Neuropraxia should clear within several months, but a more serious nerve injury may not recover, and ocular muscle surgery might be required. If it can be determined that the trochlear attachment of the superior oblique muscle tendon has been disrupted from its osseous connection, then exploration, in conjunction with an ophthalmologist, to reattach the trochlea to the superior-medial orbital wall, may be indicated. This can be accomplished through a Lynch-type incision.

### **8. Anosmia**

If anosmia is present after the injury, it is likely due to either a cribriform plate fracture or a contrecoup injury to the olfactory tracts. It is highly unlikely that it will improve over time. Anosmia is typically an “all or none” recovery phenomenon. However, other less likely etiologies should be investigated—obstructive scarring in the superior nasal vault, foreign body reaction (wire or screws), excessive mucosal edema, fractured/dislocated septum, and nasal polyps.

### **9. Frontoethmoid Sinusitis**

Owing to the potential extensive disruption of the ostia of the frontal and ethmoid sinuses with NOE fractures, sinus aeration and the development of a chronic sinusitis are not uncommon. Additionally, the lamellae of the ethmoid sinuses are typically crushed in the NOE fractures, which may well result in sequestration, infection, and mucopyocele. These conditions will be obvious on follow-up fine-cut CT scans and should be appropriately addressed medically and surgically.

## CHAPTER 3: Upper Facial Trauma

The frontal sinus floor and immediate surrounding inferior portion is at high risk for injury in NOE fractures, which can result in trapped, inspissated mucus, and the development of a mucopyocele. Because of their proximity to the anterior cranial cavity, such infections can spread to the dura and intracranially, causing meningitis and frontal lobe abscess. If the frontal sinus is not obliterated, as indicated due to displaced posterior-inferior wall fractures, then frequent follow-up of the patient is important to identify the early formation of poor sinus drainage and pending serious complications.

### III. Summary and Conclusion

#### A. FRONTAL SINUS AND ANTERIOR SKULL BASE TRAUMA

Frontal sinus fractures are uncommon, and the victims of these injuries are exposed to a significant traumatic impact. The fractures are often multiple, and a treatment algorithm that addresses each wall and type of fracture, such as that presented in this chapter, is recommended. An acute awareness of the potential complications of entrapped and damaged mucosa necessitates careful management of these injuries.

#### B. NOE FRACTURES

NOE fractures and associated injuries are usually due to blunt trauma, and are associated with other facial or head injuries.

The patient is initially evaluated by the trauma team and, when cleared, can be further evaluated by the otolaryngologist, often in consultation with the ophthalmologist. NOE trauma can involve the medial orbit, ethmoid vessels and nerves, cribriform plate, medial canthal region, nasolacrimal drainage system, ethmoid and frontal sinuses, perpendicular plate of the septum, anterior skull base, and nasal bones. Appropriate imaging studies are required after a thorough head and neck and neurological examination.

Complications can include traumatic telecanthus; visual disturbances, including diplopia; compression and splaying of the NOE bony complex; ethmoid artery bleeding; entrapped medial orbital contents; fractures of the sinus complexes, including the ostia; CSF rhinorrhea; anosmia; and discontinuity of the nasolacrimal drainage system.

Repair and reconstruction goals are to re-establish normal intercanthal distances and nasal root projection, release any entrapped medial orbital tissues, protect the globe and optic nerve, properly fixate the medial canthal tendons, stop bleeding, stop CSF leak, ensure a patent nasal airway, and address ethmoid and frontal sinus fractures.

Serious issues involving the orbital structures can best be managed in conjunction with the consultant ophthalmologist.

#### IV. References

1. Nahum AM. The biomechanics of maxillofacial trauma. *Clinical Plastic Surgery*. 1975;2:59.
2. Lang J. Paranasal sinuses. In: Lang J. *Clinical Anatomy of the Nose, Nasal Cavity and Paranasal Sinuses*. New York, NY: Thieme Medical Publishers, Inc.; 1989:63.
3. Fenton WH, Donald PJ, Carlton W. The pressure exerted by mucoceles in the frontal sinus. *Archives of Otolaryngology*. 1990;116:836-840.
4. Lawson W. Frontal sinus. In: Blitzer A, Lawson W, Friedman WH, eds. *Surgery of the Paranasal Sinuses*. Philadelphia, PA: WB Saunders; 1985:120-148.
5. Draf W. Endonasal micro-endoscopic frontal sinus surgery: The Fulda concept. *Operative Tech Otolaryngol Head Neck Surg*. 1991;2:234-240.
6. Donald PJ, Bernstein L. Compound frontal sinus injuries with intracranial penetration. *Laryngoscope*. 1978;88:225-232
7. Merville LC, Derome PJ. Concomittant dislocations of the face and skull. *J Maxillofac Surg*. 1978;6(1):2-14.

#### V. Recommended Reading

Holt GR, Holt JE. Incidence of eye injuries in facial fractures: An analysis of 727 cases. *Otolaryngol Head Neck Surg*. 1983;91:276-279.

Imahara SD, Hopper RA, Wang J, Rivara FP, Klein MB. Patterns and outcomes of pediatric facial fractures in the US: A survey of the National Trauma Data Bank. *J Am Coll Surg*. 2008;207(5):710-716.

Mazzoli RA, Ainbinder DJ, Hansen EA. Orbital trauma. Chapter 20 in: Thach AB, ed. *Ophthalmic Care of the Combat Casualty*. Fort Detrick, MD: U.S. Army Borden Institute; 2003. Accessed at: [http://www.bordeninstitute.army.mil/published\\_volumes/ophthalmic/OPHch20.pdf](http://www.bordeninstitute.army.mil/published_volumes/ophthalmic/OPHch20.pdf).

Nguyen M, Koshy JC, Hollier LH Jr. Pearls of naso-orbital-ethmoid trauma management. *Semin Plast Surg*. 2010;24(4):383-388.

Vora NM, Fedok FG. Management of the central nasal support complex in naso-orbital ethmoid fractures. *Facial Plast Surg*. 2000;16(2):181-191.

## Chapter 4: Midfacial Trauma

Robert M. Kellman, MD

John M. Morehead, MD

### I. Maxillary and Orbital (and Zygomatic) Fractures

Fractures of the midfacial bones are most commonly due to blunt trauma from falls, altercations, and motor vehicle accidents. While penetrating injuries certainly occur, they are less common, and are typically not addressed in discussions of fractures.

#### A. DENTAL TERMINOLOGY

##### 1. Maxillae and Mandible

To clearly communicate about the anatomy and to discuss common fractures, it is necessary to provide some terminology commonly used to describe and classify these fractures. In addition, when discussing fractures that involve bones that hold teeth (i.e., the maxillae and mandible), it is important to understand the basics of occlusion.

##### *a. Intercuspatation*

The maxillary and mandibular dentition interdigitate (called intercuspatation) for the purpose of chewing food.

##### *b. Crossbite*

The maxillary arch is generally larger than the mandibular arch, so that the maxillary dentition is supposed to be more lateral and anterior (buccal and labial) than the mandibular dentition. When this does not occur, it is referred to as a “crossbite,” which can occur unilaterally or bilaterally. If a crossbite is not premorbid, it can be the result of a trauma.

##### *c. Overjet and Overbite*

The “jetting” of the maxillary incisors forward of the mandibular incisors is called “overjet,” which is a normal finding. The vertical extension of the maxillary incisors is also normal, and is called “overbite.” Of course, both of these can be abnormal if the distances involved are excessive or less than optimal.

##### *d. Angle's Classification*

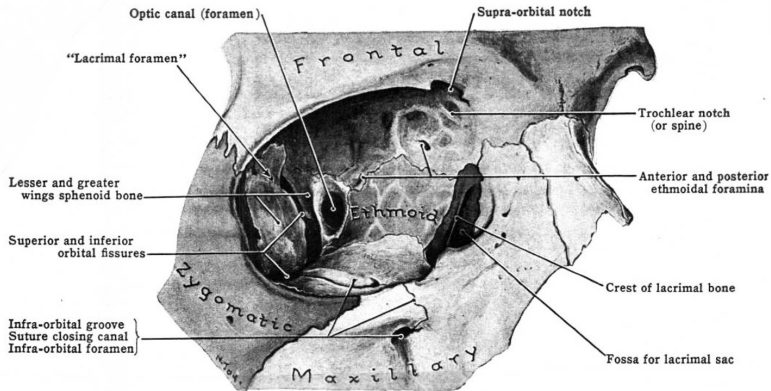
The overall relation between the maxillary and mandibular dentition is generally defined by Angle's classification, described as the “mesiobuccal cusp of the maxillary first molar fitting into the mesiobuccal groove of the mandibular first molar” on each side. (Keep in mind that since the normal maxillary arch is larger, the maxillary incisors sit anterior to the



mandibular incisors, yet the maxillary molar sits slightly posterior to the mandibular molar.) Familiarity with what is normal is important when repairing fractures in this area.

## B. MIDFACIAL ANATOMY

The midfacial structure includes left and right paired, mirror-image bones that make up the orbits, nasal structure, cheekbones, maxillae (which hold the upper teeth), and palate. Of course, multiple bones contribute to the orbital structure, including the maxilla, zygoma, sphenoid (both greater and lesser wing components), frontal, ethmoid, lacrimal, and palatine bones (Figure 4.1).



**Figure 4.1**

Illustration depicting orbital structure. Source: Agur and Dalley, Figure 518.

The bones of the face provide support for important physiologic functions, including support of the nasal airway and olfaction, support and protection of the globes and visual function, and support for the teeth and masticatory function. It has also been suggested that the facial bone structure includes strong areas (buttresses) that support the anatomy and provide the strength needed for masticatory function, and that these areas are separated by weaker areas that provide protection for important structures, such as the eyes and the brain (Manson, Stanley). (It has been theorized that the paranasal sinuses may function as "crumple zones" or shock absorbers that can protect the eyes, optic nerves, carotid arteries, and brain from some blunt traumas (Kellman, Kellman & Schmidt).) The midface is suspended from the skull base, and posteriorly, the pterygoid plates complete the midfacial structure.

### 1. Strong Areas of the Facial Bone

The strong areas of the facial bone transmit forces both vertically and horizontally. Repair of midfacial fractures requires restoration of continuity and structural integrity across these important supporting structures of the midface.

#### **a. Vertical Buttresses**

The vertical buttresses include bilateral medial and lateral buttresses that extend from the dentition superiorly, and posterior vertical buttresses that extend through the pterygoid plates to the skull base.

#### **b. Medial Anterior Buttresses**

The medial anterior buttresses extend from the alveoli along the strong pyriform aperture bone superiorly along the maxilla through the nasal bone to the frontal bone.

#### **c. Lateral Buttresses**

The lateral buttresses extend from the alveoli up along the zygomatico-maxillary junction and continue through the lateral orbital rim to the frontal bone laterally.

#### **d. Anterior-Posterior Horizontal Buttresses**

The anterior-posterior horizontal buttresses extend from the malar eminences bilaterally posteriorly along the zygomatic arches to the temporal bones.

#### **e. Lateral-to-Lateral Horizontal Buttresses**

There are two lateral-to-lateral horizontal buttresses: a superior buttress that extends from one malar eminence to the other across the inferior orbital rims and nasal bones, and an inferior buttress that extends across the inferior maxillae from one side to the other across the midline and includes the palate for strength extending posteriorly.

### 2. Maxillae

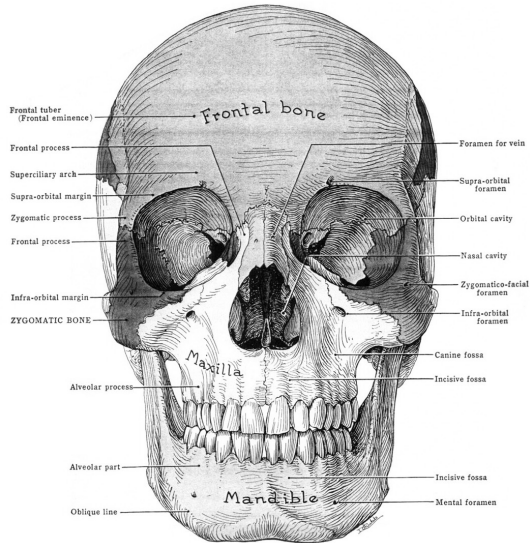
The maxillae are the paired bones that contain the maxillary dentition (teeth 1 to 16, counted from right third molar to left third molar). They provide support to the lateral nasal wall and nasal bones, as well as the inferior orbital rims. The maxillae house the maxillary sinuses. The second division of the trigeminal nerve (V2) passes into the maxillae from the orbit and exits anteriorly through the anterior maxillary wall, as the infraorbital nerve. The paired maxillae meet inferiorly in the midline.

### 3. Nasal Bones

The nasal bones project from the frontal processes of the maxillae and form the bony support of the upper portion of the nose (Figure 4.2). They connect the midface to the skull (frontal bones) anteriorly in the midline.

**Figure 4.2**

Illustration depicting frontal view of the skull. Source: Agur and Dalley, Figure 459.



### 4. Orbits

The orbits have a four-walled pyramidal shape, with the apex located medial and superior.

#### **a. Lacrimal, Ethmoid, and Palatine Bones**

The optic canal is at the apex and transmits the optic nerve. The medial wall is composed of the thick lacrimal bone, which supports the lacrimal sac; the thin lamina papyracea of the ethmoid bone; and, to a smaller extent, the palatine bone.

#### **b. Sphenoid Bone**

The medial wall of the optic canal is provided by the strong lesser wing of the sphenoid bone. The floor is composed primarily of the thin roof of the maxillary sinus.

**c. Zygomatic Bones**

Laterally, the zygoma anteriorly and the greater wing of the sphenoid posteriorly form the lateral wall. Superiorly, the frontal bone forms the much stronger orbital roof. The zygomatic bones have a complex three-dimensional structure, including the arch, which is a thin posterior extension that extends posteriorly from the lateral portion of the malar eminence, and abuts against the temporal bone, which contributes the posterior half of the arch. Though thin, the arch creates the lateral projection of the face.

**d. Malar Eminence**

The malar eminence forms the prominent cheekbone structure, and its posterior portion contributes important support to the inferolateral orbital wall. Displacement of the malar eminence often leads to significant displacement of the globe.

**C. MIDFACIAL FRACTURES**

**1. Le Fort Series of Fractures**

While numerous classification systems have been proposed, they are not necessarily precise. Few have matched the simplicity and user-friendliness of the old, but clinically useful, Le Fort system.

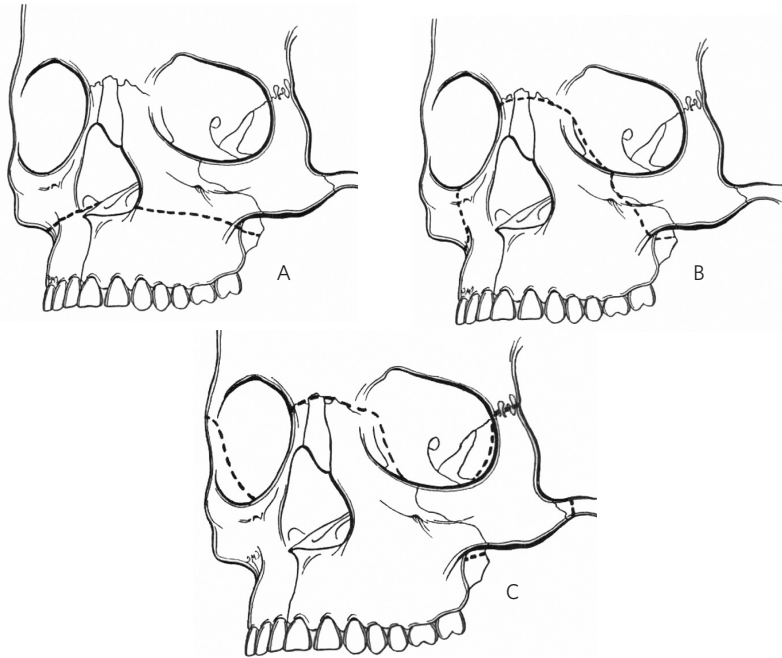
Around the end of the 19th century, René Le Fort, a French military surgeon, created a series of fractures by traumatizing cadaver faces. He noticed several patterns that seemed to occur that tended to separate the tooth-bearing bone from the solid cranium above. These patterns tended to occur at three general anatomic levels that have come to be known as Le Fort I, II, and III fractures (Figure 4.3). While few fractures precisely match the Le Fort definitions, these approximations are extremely useful in communicating the nature of an injury among physicians, and they are also useful in planning treatment planning. Le Fort I, II, and III basically define the level at which the bones holding the teeth are separated from the remaining bone above.

**a. Le Fort I**

The Le Fort I classification describes a fracture that extends across both maxillae above the dentition. It crosses each inferior maxilla from lateral to medial through the pyriform apertures and across the nasal septum. Posteriorly, it generally severs the pterygoid plates inferiorly. This frees the tooth-holding maxillary alveoli from the remaining facial bones above.

### Figure 4.3

Illustration depicting: (A) Le Fort I, (B) Le Fort II, and (C) Le Fort III fractures. Source: Kellman and Marentette, Figure 8-29.



#### **b. Le Fort II**

The Le Fort II classification starts in the maxilla laterally but extends more superiorly into the orbital floor. It crosses the anterior inferior and medial orbits and crosses the nasal bones superiorly, or separates the nasal bones from the frontal bones at the frontonasal suture. It continues posteriorly across the nasal septum and pterygoid plates. It is commonly called the pyramidal fracture due to the pyramidal shape of the inferior facial fragment.

#### **c. Le Fort III**

Finally, the Le Fort III classification completely separates the facial bones from the skull, resulting in what is known as a complete craniofacial separation. It traverses the zygomatic arches laterally and the lateral orbital rims and walls, crosses the orbital floors more posteriorly, crosses the medial orbits (lamina papyracea), and is completed at the

## CHAPTER 4: Midfacial Trauma

frontonasal junction. Posteriorly, like the Le Fort II, it traverses the nasal septum and the pterygoid plates, thus completely separating the facial structure from the skull.

### 2. Zygomatic Fractures

Zygomatic fractures have sometimes been called “tripod” or “quadrapod” fractures, due to the perceived three or four attachments of the zygoma to the surrounding bones—mainly, the frontal bone at the lateral orbital rim, the temporal bone along the zygomatic arch, and the maxillary bone along its broad attachment. The zygoma’s broad lateral expanse near the pterygoid plates leads to the confusing nomenclature, since it can be considered a single attachment (tripod) or double attachment at the inferior orbital rim and zygomaticomaxillary suture (quadrapod). Either way, when these attachments are fractured, the malar eminence is generally displaced posteriorly, laterally, or medially. When the inferior orbital rim rotates medially, it is considered medially displaced; when it rotates laterally, it is considered laterally displaced; and when it is impacted posteriorly, it is considered posteriorly displaced. Obviously, the direction of displacement determines the approach to repair.

### 3. Orbital Fractures

Orbital fractures are usually described by the status of the walls and rims. A pure blowout fracture occurs when a wall is “blown out” without identifiable fracture of the rim. Floor fractures are both most common and most severe, presumably since there is ample space for significant displacement. Medial fractures are common but are typically less severe. Lateral wall displacement is generally associated with displacement of the zygoma, and roof fractures are uncommon.

## D. DIAGNOSIS OF MIDFACIAL TRAUMA

Clinical assessment is always necessary, despite the ready availability of and need for computed tomography (CT) scans. While clinical evaluation will provide an indication of the fractures present, there is also the more important need to assess areas of function. As noted in Chapter 1, the primary and secondary evaluation of the patient, including neurologic function and assessment of the cervical spine, will precede the evaluation of the fractures in preparation for their repair.

### 1. Assessment of Vision

Assessment of vision is urgent. Though rarely indicated, visual loss due to pressure on the optic nerve may be helped by urgent optic nerve decompression. This is generally performed only when the patient arrived at the hospital with some vision, and the vision has decreased

or failed to improve with high-dose steroids. It is also important to assess eye movement for evidence of extraocular muscle entrapment (and/or nerve injury). Most important, before considering surgical intervention around the orbit, an ophthalmological evaluation to rule out ocular and/or retinal injury is mandatory.

## **2. Assessment of Other Nerves**

Other nerves should be assessed, including trigeminal nerve function in all divisions and particularly facial nerve function, since not only documentation but also the possibility of decompression or peripheral repair need to be considered when indicated.

## **3. Le Fort Fractures**

Le Fort fractures are generally evaluated by assessing movement of the tooth-bearing maxillary bones relative to the cranium, making sure that the teeth themselves are not moving separately from the bone. The anterior maxillary arch is held and rocked relative to a second hand on the forehead. If there is movement of the maxillary arch and maxillae relative to the frontal bones, then a Le Fort fracture can be presumed. The level of movement may be difficult to detect, but the CT scan will sort that out.

## **4. CT Scan**

Finally, the CT scan is the key to the diagnosis of midfacial fractures. In general, axial CTs are best for visualizing vertical bone structures, and coronal CTs are best for visualizing horizontal structures, though with modern CT algorithms and high-resolution scanning, both can be easily produced and should be utilized. The three-dimensional (3D) CT is helpful for creating a gestalt for the surgeon, but it is less accurate than the axial and coronal CTs from which it is created.

## **E. CONSIDERATIONS FOR REPAIR OF MIDFACIAL TRAUMA**

Midfacial bones are repaired for two main reasons: to restore normal function and to restore normal facial contour (cosmesis). Before making the decision to proceed with repair, it is important that the patient (and/or family) understands the risks and benefits of the surgery, as well as the risks of not repairing the fractures.

### **1. Orbital Fractures**

The main dysfunction for which orbital repair is performed is diplopia, which is usually due to muscle entrapment of one of the extraocular muscles, though it can occur as a result of significant globe malposition as well. Globe malposition can also cause significant cosmetic deformity.

## CHAPTER 4: Midfacial Trauma

### 2. Zygomatic Fractures

Zygomatic fractures may be another cause of globe dysfunction/malposition, because of the contribution of the zygoma to the orbital structure. More commonly, however, a displaced zygoma, particularly a depressed arch, may lead to impingement on the temporalis muscle, causing trismus and/or painful mouth opening and difficulty with mastication. More commonly, however, zygomatic fractures are reduced for cosmetic reasons. It is also common for patients to refuse repair, when the problem is only cosmetic.

### 3. Maxillary Fractures

Le Fort fractures can affect the position of the dentition and result in significant malocclusion. Because this will interfere with chewing, repair is very important.

## F. APPROACHES TO REPAIRING MIDFACIAL TRAUMA

### 1. Orbital Fractures

A number of different options can be used when approaching orbital fractures, and each has its proponents and detractors. It is important to protect the cornea from trauma when utilizing these approaches. The common approaches to the orbital floor include:

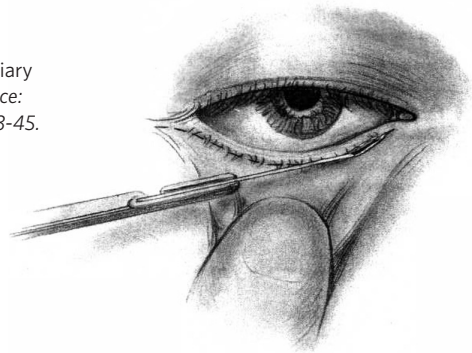
#### a. Lower Lid Approaches

##### i. Subciliary Incision

This transcutaneous approach is generally placed 1–2 millimeters (mm) below and parallel to the lash line (Figure 4.4). The incision can be made through skin and muscle, and dissection can be carried out under the muscle to the inferior orbital rim. Alternatively, the incision can be made through skin, carried inferiorly for several mm, whereupon the orbicularis muscle is dissected away from the orbital septum, exposing the inferior orbital rim. Care must be taken to avoid damaging the thin

#### Figure 4.4

Illustration depicting the subciliary transcutaneous approach. Source: Kellman and Marentette, Figure 3-45.





skin. It is also important to avoid injury to the orbital septum, to minimize the risk of ectropion developing as a result of scarring.

#### *ii. Infraorbital Incision*

This incision is performed more inferiorly than the subciliary incision, usually at the junction of the lower lid and cheek skin. It is a very direct approach to the bone. However, the scar tends to be more visible, and if the dissection is continued laterally, there is a tendency for prolonged lower lid edema.

#### *iii. Transconjunctival Approaches*

Transconjunctival approaches avoid skin incisions. When they were introduced, it was hoped that lid malpositions would no longer be seen. However, although ectropion is less common with this incision, entropions are more common.

#### *iv. Preseptal Incision*

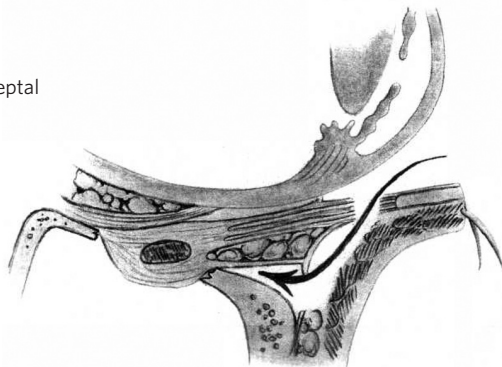
After incising the lid conjunctiva anterior to the insertion of the orbital septum, dissection is carried in front of the septum, which is followed to its attachment on the inferior orbital rim (Figure 4.5). Incision of the periosteum on the bone provides access to the orbital floor.

#### *v. Postseptal Incision*

The conjunctival incision is placed more posteriorly, closer to the fornix, though still on the lid conjunctiva (not the bulbar conjunctiva). Orbital fat is encountered, since the incision is behind the orbital septum (Figure 4.6). Incision is immediately turned inferiorly to reach the anterior portion of the orbital floor. (If care is not taken to aim inferiorly—and sometimes even a bit anteroinferiorly—then dissection will continue through the orbital fat further posteriorly into the orbit.)

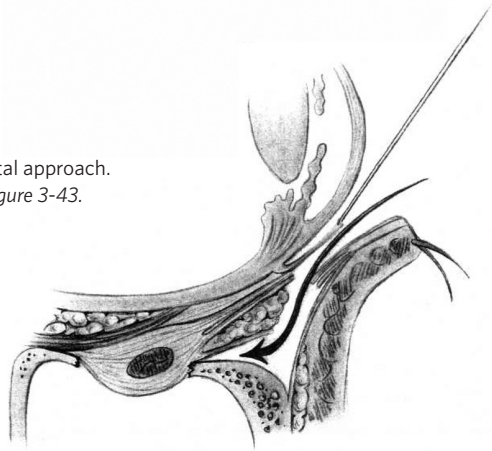
#### **Figure 4.5**

Illustration depicting the preseptal approach. Source: Kellman and Marentette, Figure 3-42.



**Figure 4.6**

Illustration depicting the postseptal approach.  
Source: Kellman and Marentette, Figure 3-43.



**b. Transmaxillary/Transnasal Approaches**

In the past transmaxillary approaches used direct visualization with a headlight. Today these repairs are performed using endoscopic assistance. However, this approach exposes orbital floor fractures from below, so it is not possible to see what is happening on the orbital side of the fracture.

**c. Endoscopic Transmaxillary Approach**

This approach involves making a window in the anterior wall of the maxillary sinus. Generally, a small plate may be placed and removed prior to making the bone cuts, so that the bony window can be replaced after fracture reduction has been achieved. The orbital floor is then visualized through the maxillary sinus.

**d. Endoscopic Transnasal Approach**

Access is more difficult with this approach, since visualization is limited by the pyriform aperture and nasal septum. However, the orbital floor can be visualized via a large middle meatal antrostomy.

**e. Approaching the Medial Orbital Wall**

*i. External Incision*

A vertical skin incision half way between the nasal dorsum and the medial canthus can be made and taken down through periosteum to bone. Elevation can then proceed posteriorly under the periosteum. Care must be taken to avoid damage to the lacrimal sac and the periosteum (note that the medial canthal ligaments are detached, but will reattach when the periosteum is allowed to reposition itself).

### ii. Transconjunctival Incisions

- *Postcaruncular*—This incision is made vertically through the mucosa down to bone. The main problem with this incision is that it begins fairly posteriorly, thereby limiting access to the anterior third of the medial orbital wall.
- *Transcaruncular*—This incision is similar to the postcaruncular, except that it is performed a little more anteriorly.

### iii. Endoscopic Transnasal

This approach is performed endoscopically through the ethmoid sinus. Care must be taken when opening the ethmoid bulla, since the orbital contents are in the sinus, and when the bulla is opened, the orbital fat is generally right there.

## f. Approaching the Lateral Orbital Wall

### i. Infrabrow Incision

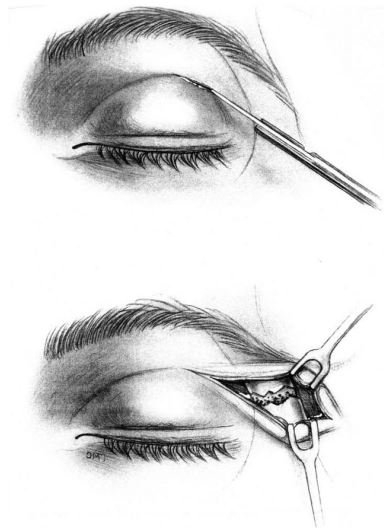
Incisions through the brow are not recommended, since scars separate the hair follicles and become quite visible. An incision can be made either above or below the brow; however, for orbital access, incising below the brow is more direct.

### ii. Upper Lid Skin Crease Incision

The upper lid crease (upper lid blepharoplasty) incision is preferred, since it hides nicely once it heals (Figure 4.7). The incision goes through the skin and orbicularis muscle, and then extends superiorly to the bone.

### Figure 4.7

Illustration depicting the upper lid blepharoplasty incision. Source: Kellman and Marentette, Figure 3-49.



## CHAPTER 4: Midfacial Trauma

### *iii. Extended Lower Lid Transconjunctival (with or without Lateral Canthotomy)*

The lower lid transconjunctival incision described above can be extended laterally, either (1) within the orbit (posterior to the lateral canthus), though this limits access anteriorly, or (2) preferably, by incising the lateral canthus, separating the upper and lower lid attachments and performing an inferior cantholysis. This can be extended laterally through the skin as needed for exposure of the lateral orbital rim. It is important to reattach the ligament to the lateral orbit inside and behind the rim at the end of the procedure.

### *iv. Extended Subciliary Incision*

As with the transconjunctival incision noted above, the lower lid subciliary incision can be extended laterally as well.

## **g. Approaching the Orbital Roof**

### *i. Lynch (External Ethmoidectomy) Incision*

This incision begins half way between the nasal dorsum and the medial canthus. It then extends superiorly and laterally into the medial superior upper lid, beneath the brow. Periosteal elevation provides access to the medial superior orbit. Note that the trochlea of the superior oblique muscle is elevated with the periosteum, and care must be taken to avoid damage to this structure. Also note that lateral superior exposure can be obtained through the upper lid blepharoplasty incision described above.

### *II. Transcranial (Generally Coronal) Incision*

The coronal incision can be elevated to a level below the superior orbital rims for access to the orbital roofs. Note that care must be used to avoid injury to the supraorbital neurovascular bundles.

## **2. Zygomatic Fractures**

Many displaced zygomatic fractures can be reduced via a transoral approach to the zygomaticomaxillary suture. However, if there is too much displacement or comminution, an orbital exposure allows access to the inferior orbital rim and the lateral internal orbit, where the zygomaticosphenoid suture can be aligned.

- The lateral orbital rim can be exposed through either a brow incision or an upper lid crease incision.
- In the most severely displaced and comminuted fractures, exposure of the zygomatic arch may be necessary. This is generally performed via a coronal or hemicoronal incision.

- Isolated zygomatic arch fractures may be reduced without fixation in many cases. This is typically performed from a distance, using either a temporal (Gillie's) approach or a transoral (Kean) approach.

### 3. Maxillary Fractures

#### **a. Le Fort Fractures**

Most Le Fort fractures will require fixation at the lower maxillary level, to build a proper foundation for the remainder of the fracture stabilization. A sublabial transmucosal exposure provides excellent exposure of the front face of the maxillae bilaterally, allowing repair at the Le Fort I level.

#### **b. Dental Arches**

For any fractures involving the dental arches, arch bars are generally applied first to assist with reduction of the occlusion.

#### **c. Nasofrontal Junction**

Fractures at the nasofrontal junction are exposed via a coronal incision when necessary. Otherwise, a direct horizontal incision can sometimes be used when only limited exposure is needed for repair.

## G. FRACTURE REDUCTION AND REPAIR

For maxillary and zygomatic fractures, the main goal of repair is to reestablish the correct bony architecture by repositioning the bones into their correct anatomical positions and fixating them in those correct positions. Fixation is most commonly performed using rigid fixation devices—typically plates and screws.

### 1. Zygomatic Fractures

For zygomatic fractures, the rotated fractures need to be corrected by rotation contrary to the rotation created by the injury. If the zygoma was impacted, then reduction requires direct pull counter to the direction of the impaction. This disimpaction technique involves placing a sturdy instrument, such as a Dingman elevator, beneath the malar eminence and applying a firm, but not excessive, distractive force. The instrument can be placed through an incision in the temporalis fascia from above or the mucoperiosteum from below.

Reduction is often monitored along the zygomaticomaxillary buttress intraorally. When the bone is adequate to ensure reduction, fixation along the zygomaticomaxillary buttress using an appropriate plate and screw will often suffice.

## CHAPTER 4: Midfacial Trauma

However, if there is comminution in this area, not only will reduction be more difficult to determine, but fixation will be more difficult as well. Additional reduction and fixation may be applied along the inferior orbital rim and along the lateral orbital wall at the zygomaticosphenoid junction. (Reduction here is very helpful, though fixation here is less common.)

The frontozygomatic area (lateral orbital rim) provides strong bone for fixation when necessary. If the zygomatic arch needs to be explored and repaired (which is less common, typically occurs only in severely displaced and comminuted fractures), fixation should be performed using either wires or the thinnest plates available, since plates in this area can be visible and can alter the facial width.

### 2. Maxillary and Extended Maxillary Fractures

#### **a. Recreation of Correct Occlusion**

Le Fort (maxillary and extended maxillary) fractures are repaired by first ensuring recreation of the most correct occlusion possible. When dentition is adequate, arch bars are the best means of ensuring correct occlusion, particularly in severe fractures.

#### **b. Associated Mandibular Fractures**

When mandibular fractures are associated with midfacial fractures, it is often necessary to first repair the mandible to provide a template for the maxillary dentition, particularly when the palate is split.

#### **c. Fixation of Maxillary Fractures**

If proper occlusion has been reestablished, the maxillary fractures can be fixed, so as to ensure that the proper occlusal relationship is maintained. This is in fact more critical than achieving an ideal visual appearance of “perfect” bony reduction along the fracture lines.

#### **d. Le Fort Fractures**

If a complex Le Fort III (i.e., craniofacial separation along with zygomatic and lower maxillary fractures) is repaired from the top down, fixation of the zygomas to the skull will change these complex fractures from a Le Fort III to a Le Fort I fracture, and repair of the nasofrontal junction and inferior orbital rims will convert the remainder to Le Fort I fractures.

Le Fort I fractures must be repaired along the strong medial and lateral vertical buttresses, as described earlier in section B.1 of this chapter. These areas provide the strong bone that will support both the screws

and the forces of mastication that will be transmitted through these areas during function.

### **3. Blowout Fractures of the Orbits**

Blowout fractures of the orbits present a somewhat different paradigm, in that the goal is directed less at fracture reduction (with the exception of the zygomatic component of an orbital fracture) and more at recreating the damaged orbital wall that is affected by the fracture. Therefore, repair generally includes reduction of any herniated orbital contents, followed by placement of some supporting material to hold the contents in place and restore the normal orbital wall contour. The material selected will depend on the surgeon's preference, and includes autograft bone and cartilage, as well as allograft and homograft materials.

## **H. COMPLICATIONS**

### **1. Inadequate Reduction**

The most common complication is less than adequate reduction. When this occurs in the maxilla, it will often result in a malocclusion. Failure to properly reduce the zygoma can result in significant alterations of facial and orbital shape, with both cosmetic deformity and globe malpositions likely.

### **2. Imprecise Reconstruction of the Orbit**

Imprecise reconstruction of the orbit will generally result in a globe malposition—most commonly enophthalmos, though exophthalmos and hyperophthalmos occur frequently as well.

### **3. Globe Malposition**

Diplopia can be the result of a globe malposition. However, diplopia is more likely due to residual entrapment of an extraocular muscle or a traumatic injury to an extraocular muscle or the nerve to one of these muscles (which would not be corrected by the surgery to reduce the fractures).

One of the ways to minimize the risk of a malreduction leading to a globe malposition postoperatively would be to perform an intraoperative CT scan, if available. Alternatively, the patient's head can be elevated 30 degrees on the operating table to assess the level of the pupils on both eyes. To identify diplopia due to inadequate release of entrapped tissue, intraoperative forced duction testing can be performed.

## CHAPTER 4: Midfacial Trauma

### 4. Eyelid Malpositions

Eyelid malpositions result from eyelid incisions used to repair orbital and facial fractures. This complication can be minimized by meticulous dissection of the lids, taking care particularly to avoid injury to the orbital septum.

### 5. Reduced Vision and Blindness

The most feared complication of orbital injuries and their repair is reduced vision and blindness. Fortunately, this is very rare. Nevertheless, as noted above, an ophthalmological evaluation should be performed prior to manipulating the orbital bones after trauma, to ensure no injury is present that would increase the risk of a feared ocular complication.

### 6. Scars and Hair Loss

Because less than ideal healing of any wound is possible, patients should be warned about scars and hair loss. Irregularization of coronal incisions can minimize scar visibility in patients who have low risk of male pattern baldness.

### 7. Nonunion

Nonunion appears to be quite rare with midfacial fractures, and is not usually discussed. The bones of the midface tend to heal, even when they have not been repaired. This is probably due to the minimal forces that are exerted on these bones during function. Implants can become colonized with bacteria and become a source of chronic, recurrent infection. When this occurs, they should be removed. Occasionally, bone resorption may be seen under or around an implant. Also, implants may extrude; this is most common with orbital implants, so patients should be warned of this possibility when nonautologous implants are used.

### 8. Dental Injury

Dental injury is always possible when working with fractures that are near the dentition. Great care should be exercised when placing screws to try to avoid injury to tooth roots. Arch bars can also cause loosening of teeth and gingival injury.

### 9. Cerebrospinal Fluid Leaks

Finally, CSF leaks may be the result of the initial trauma and/or the repair. CSF leaks should be addressed surgically, to ensure a safe separation between the sterile intracranial cavity and the naturally contaminated nasal and sinus cavities.



## II. Nasal Bone Fractures

### A. INTRODUCTION

Nasal fractures are a commonly encountered, and often isolated, form of facial fractures. The prominence of the nose on the face makes it the common recipient of injury. Despite the frequency in which nasal fractures are encountered, the consulting surgeon may be confused regarding which approach is best applied to a given patient. Choices range from no treatment at all, to extensive and comprehensive techniques applied in the operating room involving maneuvers used in septorhinoplasty. The timing of treatment may be just as confusing, as patients and referring physicians often expect for the consulting otolaryngologist to “set” the presumed broken nose immediately, when the actual extent of fractures and even deformity present may not be fully evident upon presentation. The following outline presents a guideline that resident physicians in otolaryngology-head and neck surgery may use to make sound decisions and to build practice patterns that can be refined with experience.

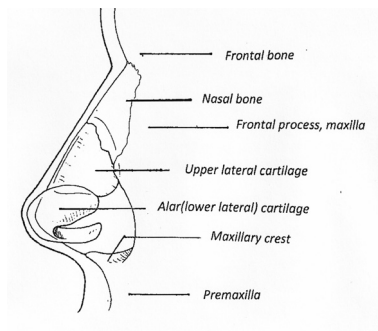
### B. REVIEW OF ANATOMY

#### 1. Bony: Paired Nasal Bones (Figure 4.8)

- Maxillafrontal processes laterally.
- Premaxilla inferiorly.
- Maxillary crest internally.
- Ethmoid-perpendicular plate.
- Lamina papyracea.
- Paired lacrimal bones.
- Nasal process of frontal bone.

#### 2. Cartilaginous (Figure 4.8)

- Quadrangular (septal) cartilage.
- Paired upper lateral cartilages, contiguous with septal cartilage dorsally.
- Paired lower lateral (alar) cartilages, with medial and lateral crura (“legs”).
- Sesamoid accessory cartilages (variable).

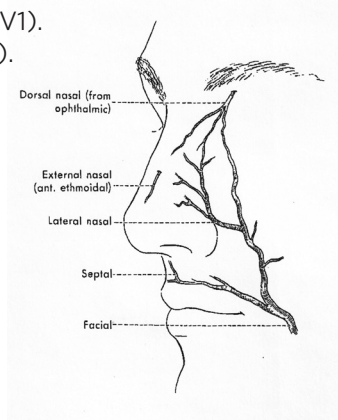


**Figure 4.8**  
Nasal bony and  
cartilaginous anatomy.

## CHAPTER 4: Midfacial Trauma

### 3. Neurovascular (Figure 4.9)

- Lateral nasal and septal arteries, from facial artery (external carotid).
- Dorsal nasal artery, from ophthalmic artery (internal carotid).
- Sensory innervation from trigeminal nerve:
  - Root and dorsum from ophthalmic (V1).
  - Sidewall, mostly from maxillary (V2).



**Figure 4.9**

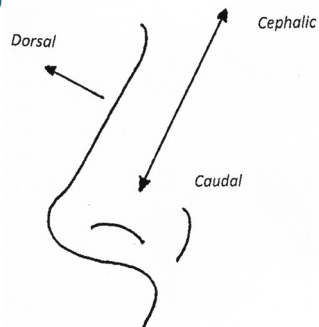
Nasal vascular anatomy.

### 4. Conformational

- Pyriform (“pear-shaped”) aperture:
  - Bordered by nasal bones, maxilla.
- Soft tissue envelope.
- Skin externally (abundantly sebaceous) and internally, vestibule (hair-bearing “vibrissae”).
- Mucous membrane lining internal to vestibule (border is *limen vestibuli*).
- Fibrofatty tissue works with cartilages and bone to maintain conformational integrity.
  - Upper vault, mostly bony, is rigid.
  - Lower vault, mostly cartilaginous, fibrofatty, is flexible, performs valve function.
  - Paired nostrils (nares) with intervening columella containing medial crura of lower lateral cartilages.

### 5. Orientational Terminology (Figure 4.10)

- Dorsal: toward “bridge.”
- Cephalic: toward top of head.
- Caudal: toward mouth.



**Figure 4.10**

Nasal orientational terminology.

## C. EVALUATION AND DIAGNOSIS

### 1. History of Trauma

- Usually blunt.
- Motor vehicle accident.
- Altercation.
- Sports (especially, but not always, contact).
- Falls (especially in elderly, debilitated).
- Injuring blow, usually delivered from one side or from front, occasionally from below, rarely from above.

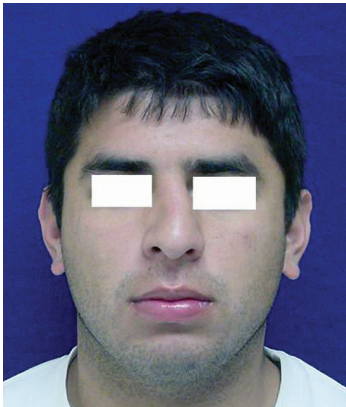### 2. Nasal Deformity, Causally Related to Occasion of Trauma

- Establish presence of deformity.
- Comparison with preinjury photos (e.g., driver's license).
- Delay definitive examination for 10–12 days, allowing swelling/bruising to decrease.

### 3. Simple Lateral Deviation (Figure 4.11)

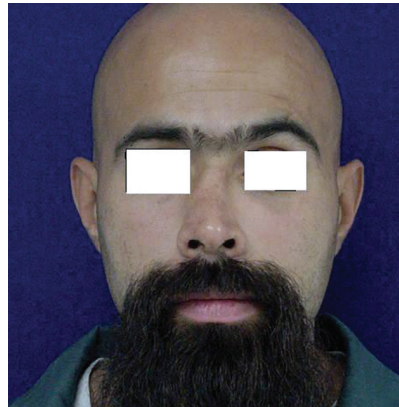
- Of bony vault.
- Of cartilaginous vault.
- Of both.

### 4. Complex Deviation (“Twisted Nose”) (Figure 4.12)



**Figure 4.11**

Simple lateral deviation.



**Figure 4.12**

Complex deviation (“twisted nose”).

## CHAPTER 4: Midfacial Trauma

### 5. Spaying/Widening of Nose (Figure 4.13)

### 6. Widening of Nasal Root, or Telecanthus

- May suggest orbital/ethmoid fracture, especially when acute swelling has subsided.

### 7. Nasal Function Alteration, Causally Related to Occasion of Trauma

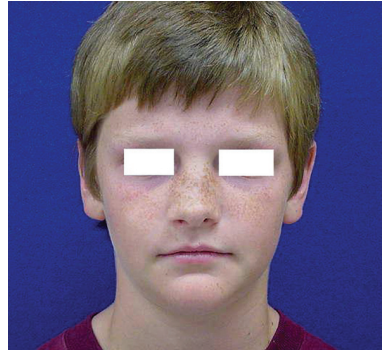
- New, fixed nasal obstruction.
- Often, but not always, unilaterally.
- New olfactory deficit (anosmia).

### 8. Examination

- Attend to associated injuries, as applicable (e.g., cervical, cranial, facial).
- Examine eyes/orbits (pupils, globes, extraocular motion, visual acuity).
- Narrow consideration to nose when other injuries are identified or excluded.
- Preferably, conduct examination in the otolaryngology clinic with availability of good lighting and nasal examination instruments.
- Establish nature of external deformity, as above.
- Palpate for bony stepoffs, displacements, discontinuities.
- Palpate for mobility of fractured segments, comminution.
- Identify/characterize nasal soft tissue (skin) lacerations/avulsions.
- Apply anterior rhinoscopy, with added nasal endoscopy as required, to identify presence of:
  - Septal deformities, both cartilaginous and bony, especially stepoffs/telescoping deformities.
  - Septal haematoma.
  - Septal perforations.
  - Nasal lining lacerations.
  - Bleeding points, if continued acute bleeding is present.
  - Overall nasal airway patency.

### 9. Radiographic Studies, Including CT

- If referred from the emergency room or a minor emergency clinic, patient may arrive with studies in hand.



**Figure 4.13**  
Spaying/widening of the nose.

- Do not add to diagnosis/treatment, and need not be obtained, unless associated facial fractures are suspected.

## 10. Photography

- Take full 6-view series with standard composition, lighting, technique, and background: front, both laterals, both obliques, base.
- Take photos prior to any manipulation or surgical intervention, usually at the time the decision is made to intervene, if not when initially consulted.

## D. MANAGEMENT

The central consideration in the management of nasal fractures is whether to offer closed reduction or open reduction (or no intervention at all). When and in what setting the decided-upon treatment should be rendered is an additional, but closely related, consideration. These decisions are based upon the findings at examination, and the desires of the patient. The surgical treatment of even obvious, severe deformity and high-grade nasal obstruction is, after all, elective, and may be undertaken, delayed, or refused by patient choice.

The decision of closed versus open reduction has been the subject of discussion and controversy in the otolaryngologic literature, and outcomes have been shown to be similar with regard to appearance, function, and patient satisfaction, when the treatment approach is well matched to the specific characteristics of the injury. Therefore, both treatment options will be presented with the setting in which they are best employed, according to this author's opinion and experience.

### 1. Closed Reduction

- Characterized by manipulation of fractured bones (and often cartilages), either with the fingers or with blunt instruments, without making incisions.
- Fast, safe, direct, minimally invasive.
- Good choice for simple deformities involving, in the main, just the nasal bones.
- Likelihood of successful reduction is greatest when not only deformity, but also mobility of fractured segments, can be demonstrated at examination.
- May be carried out under local anesthesia in the consulting rooms if a competent, well-informed, and properly motivated patient desires this direct, time- and money-saving intervention. With other patients, general anesthesia in the operating room may be best.
- May be employed as an initial, trial maneuver at operation when open reduction has been decided upon.

## CHAPTER 4: Midfacial Trauma

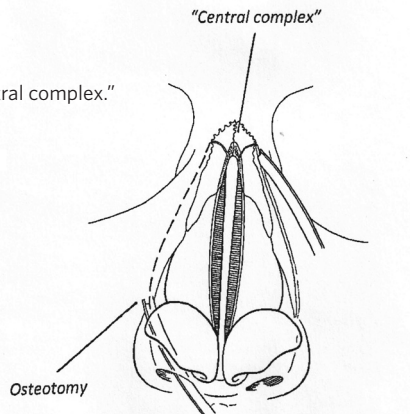
- Closed reduction of a fractured septum may also be attempted, but complex septal deformities may require open, operative treatment.
- Often the best choice for pediatric nasal fractures, but usually requires general anesthesia in the operating room.
- Often sufficient for comminuted nasal fractures.
- Should be undertaken as soon after accurate assessment is available, optimally within 3 weeks of injury.
- Securely tape and splint postreduction—no other fixation is employed.

### 2. Open Reduction (Figure 4.14)

- Characterized by operative manipulation of nasal fractures, with open access to fractured segments through incisions, usually intranasal.
- Requires general or local and monitored sedation anesthesia in the operating room.
- Ordinarily, fractured bony segments are made fully mobile by means of aggressive manipulation or osteotomies.
- More complex septal deformities, including perpendicular plate fractures, may be addressed and reconstructed simultaneously through a septoplasty approach.
- Good choice with complex, immobile, post-traumatic nasal deformities.
- Good choice for late treatment of post-traumatic deformities, where bony union has begun or progressed.
- Dorsal irregularities may be addressed with rasp or osteotome.
- Upper lateral cartilages may be released from the septum if the middle vault is deviated or twisted.
- Open rhinoplasty approach may be selected to address deformities of alae and tip.

**Figure 4.14**

Osteotomies and “central complex.”



- Since full operative mobilization of fractured segments will be carried out, procedure may be delayed. Treatment within 2 months of injury is advised, so mobilization may be done prior to full bony union.
- Securely tape and splint postreduction—no other fixation is employed.

## **E. GENERAL CONSIDERATIONS**

### **1. Internal Fixation**

In most cases of treatment of isolated nasal fractures, internal fixation is not employed.

### **2. Nasal Packing**

Nasal packing is neither necessary nor desired in most cases. However, it may be judiciously employed under depressed fractures or concave deformities that cannot otherwise be maintained in reduction. Traditional nasal packing with ½-inch x 6-foot petrolatum gauze may be used, or a single cotton dental roll placed in a supportive position with an attached retrieval suture may work as well.

### **3. Lacerations of the Nasal Skin**

Carefully close lacerations of the nasal skin as soon as possible. Lacerations may be reopened and used as access incisions.

### **4. Septal Hematomas**

Septal hematomas, when identified, should be incised and drained. Clots may require direct irrigation and suctioning. Septal mucosa elevated by the haematoma may be reapproximated with an absorbable trans-septal quilting suture.

### **5. Lacerations of the Nasal Lining**

If accessible, close lacerations of the nasal lining closed with absorbable sutures. Inaccessible lacerations that approach the full circumference of the nasal cavity may require stenting or packing to avoid nasal stenosis, but may otherwise require no closure.

### **6. Perioperative Antibiotics**

Perioperative antibiotics are generally not necessary even in open fractures. However, postoperative broad-spectrum antibiotics, such as a first-generation cephalosporin, are indicated if nasal packing or internal splints are used, until they are removed.

### **7. Splints**

Splints may be removed in a week. Retaping and resplinting may be considered.

### 8. Rest, Elevation, Ice, and Anodynes

Rest, head elevation, local ice application, and anodynes are indicated for the first 48–72 hours postreduction.

### 9. Postreduction Photos

Immediate postreduction photos are useful. Full 6-view photography is done at 6 weeks and at 6 and 12 months. Follow-up at 6 and 12 months is highly desirable.

## F. COMPLICATIONS

The most important and frequently seen complication of treatment of nasal fractures is failure to achieve effective reduction and the desired improvement of the deformity and/or nasal obstruction, with subsequent need for revision. This outcome may be kept to a minimum by proper selection and timely application of a well-executed reduction technique, but cannot be altogether avoided. Care should be taken to clearly inform the patient *preoperatively* of this possibility. The postoperative appearance of this result may range from minimal residual irregularity, through no apparent improvement, to significantly worsened deformity.

Healing should be allowed to proceed for 6–12 months before being judged to be unsatisfactory. Often, the early appearance of irregularity or asymmetry will resolve as swelling subsides. That said, sometimes it may become apparent that reduction has failed, and significant external deformity or anatomic airway obstruction persists. In this case, reoperation may be undertaken at any time. Early reoperation *may* be associated with more mobile fractured segments, but full remobilization (open reduction) with osteotomies or cartilage incision or excision will likely be needed. Reoperation under these circumstances, therefore, may be scheduled according to patient and surgeon preferences.

Other infrequently seen complications include:

- Epistaxis.
- Septal perforation.
- Synechiae formation.
- Nasal obstruction.
- CSF rhinorrhea.
- Nonunion of fractures.
- Wound infection.
- Nasal skin sensory disturbances (numbness).
- Injury to sinuses and their outflow tracts (frontal, maxillary, ethmoid).
- Unfavorable scar formation of lacerations or surgical scars.



## G. SUMMARY

The aim of the treatment of nasal fractures is to provide the patient afflicted with this injury the best aesthetic and functional result with a single procedure, if one is indicated. Careful examination under optimal circumstances sets the stage for precise selection of the best treatment, even though a daunting and often controversial array of options exists.

## III. References

Agur AMR, Dalley AF. *Grant's Atlas of Anatomy*. 13th ed. Baltimore, MD: Lippincott Williams & Wilkins; 2005.

Colton JJ, Beekhuis GJ. Management of nasal fractures. *Otolaryngology Clinics of North America*. 1986;19:73-85.

Kellman RM. Maxillofacial Trauma. In: Flint et al. *Cummings Otolaryngology: Head and Neck Surgery*. 5th ed. Philadelphia, PA: Mosby Elsevier; 2010:318-341.

Kellman RM, Marentette LJ. *Atlas of Craniomaxillofacial Fixation*. New York, NY: Raven Press; 1995.

Kellman RM, Schmidt C. The paranasal sinuses as a protective crumple zone for the orbit. *Laryngoscope*. 2009;119(9):1682-1690.

Le Fort R. Étude expérimentale sur les fractures de la mâchoire supérieure. *Rev Chir Paris*. 1901;23:208, 360, 479.

Manson PN, Hoopes JE, Su CT. Structural pillars of the facial skeleton: An approach to the management of Le Fort fractures. *Plastic and Reconstructive Surgery*. 1980;66(1):54-61.

Ondik MP, Lipinski L, Dezfoli S, Fedok FG. The treatment of nasal fractures. *Arch Facial Plastic Surgery*. 2009;11(5):296-302.

Rhee JS, Weaver EM, Park SS, et al. Clinical consensus statement: Diagnosis and management of nasal valve compromise. *Otolaryngol Head Neck Surg*. Jul 2010;143(1):48-59.

Staffel JG. Optimizing treatment of nasal fractures. *Laryngoscope*. 2002;112:1709-1718.

Stanley RB Jr, Nowak GM. Midfacial fractures: Importance of angle of impact to horizontal craniofacial buttresses. *Otol Head Neck Surg*. 1985;93(2):186-192.

## Chapter 5: Mandibular Trauma

Vincent D. Eusterman, MD, DDS

Mandible fractures are among the most common skeletal injuries in man due to blunt or penetrating trauma. They are often associated with other craniofacial, cervical, and systemic trauma. Mandibular fractures may destabilize the airway and may create malocclusion, joint dysfunction, pain, infection, and paresthesia. In facial trauma management, emergent consideration must be given to secure the airway and obtain hemostasis before initiating definitive treatment of any fracture.

Historically, treatment of the fractured mandible dates to 1650 BC on Egyptian papyrus detailing the examination, diagnosis, and treatment. Since then, many ingenious methods and devices for fracture treatment have included the facial bandage,<sup>1,2</sup> extraoral and intraoral appliances,<sup>3</sup> arch bars,<sup>4,5</sup> and wire and plate osteosynthesis.<sup>6-8</sup>

Mandibular fractures are sites described as in the horizontal mandible or the dentoalveolar fractures and the vertical mandible with fractures of the mandibular angle, ramus, condyle, and coronoid processes. The mandible is an active mobile articulation with the maxillary dentition. Fracture treatment concerns include malocclusion, infection, joint dysfunction, growth retardation, nonunion, and facial nerve injury. Pediatric mandibular fractures are managed differently due to the mixed dentition, anatomic differences in teeth, and intrinsic makeup of the pediatric mandible.

### I. Mandibular Bone, Muscle, and TMJ Anatomy

#### A. MANDIBULAR BONE

This vulnerable, v-shaped cartilaginous bone articulates at each at the temporomandibular joint (TMJ). The horizontal mandible is divided structurally into basal bone and alveolar (tooth bearing) bone, and consists of the symphysis, parasymphysis, body, and alveolar bone. The vertical mandible consists of the angle, ramus, condylar, and coronoid processes.

#### B. MANDIBULAR MUSCLE

Paired lateral pterygoid muscles open the jaw. The upper head originates on the infratemporal surface and crest of the greater wing of the sphenoid bone and inserts onto the articular disc and fibrous capsule of the TMJ. The lower head originates on the lateral surface of the lateral

pterygoid plate and inserts onto the neck of the mandibular condyle. Fractures of the condyle are pulled anterior-medially by this muscle.

Three paired muscles close the mandible. The medial pterygoid muscle from the medial portion of the lateral pterygoid plate and the masseter muscle from the zygomatic process of the maxilla, and anterior two-thirds of the lower border of the zygomatic arch, insert on the medial and lateral vertical mandible forming a tendinous “pterygomasseteric sling.” The temporalis muscle arises from the temporal fossa and the deep part of temporal fascia and passes medial to the zygomatic arch and inserts onto the coronoid process of the mandible.

### **C. TEMPOROMANDIBULAR JOINT**

The TMJ’s articular eminence and superior condyle are covered with fibrocartilage. The articular disk is dense collagenous connective tissue and is without sensation. The retrodiscal loose connective tissue that anchors the disk posteriorly is well innervated, and when torn, allows the disk to displace anteriorly.

The jaw opens in two steps: (1) the condyle rotates in the inferior joint space for an interincisor opening of 20–24 millimeters (mm), and (2) the condyle and disk translate down the articular eminence, allowing the interincisor opening to exceed 40 mm.

## **II. Indications of the Presence of Mandibular Fracture**

### **A. SYMPTOMS (SUBJECTIVE)**

- Pain.
- Bite abnormality.
- Numbness.
- Bleeding.
- Swelling.
- Dyspnea.

### **B. SIGNS (OBJECTIVE)**

#### **1. Deformity**

External deformity is often difficult to see clinically due to swelling. Intraoral exam may show displacement creating a step deformity, open bite deformity, and malocclusion. Many patients can have significant preexisting malocclusion, which must be documented in preoperative notes and considered during treatment planning.

## CHAPTER 5: Mandibular Trauma

### 2. Pain

Fracture sites are tender to palpation and sometimes to compression. Tapping the chin will compress the fracture and may elicit pain at the site. TMJ pain under compression may identify a fractured condyle or a contused and inflamed joint.

### 3. Tooth and Bone Fragment Hypermobility

Tooth and bone fragment hypermobility are signs of mandibular fracture. Airway compromise can occur with either posterior tongue displacement in bilateral mandibular fractures producing “flail mandible” or with traumatic tongue muscle avulsion.

### 4. Bleeding, Hematoma, and Swelling

Tearing of the periosteum and muscles attached to the mandible can cause significant bleeding, producing visible hemorrhage, sublingual hematoma, swelling, and life-threatening airway compromise. Urgent intubation, and infrequently tracheostomy, may be required to maintain respiration.

### 5. Crepitus

Crepitus is the sound produced by the grating of the rough surfaces when the bony ends come into contact with each other.

### 6. Restricted Function

Restricted functions include lateral deviation on opening to the side of fracture, inability to chew, loss of opening (lockjaw) due to muscle splinting, trismus, joint dysfunction, or impingement by zygomatic fractures.

### 7. Sensory Disturbances

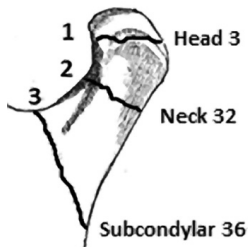
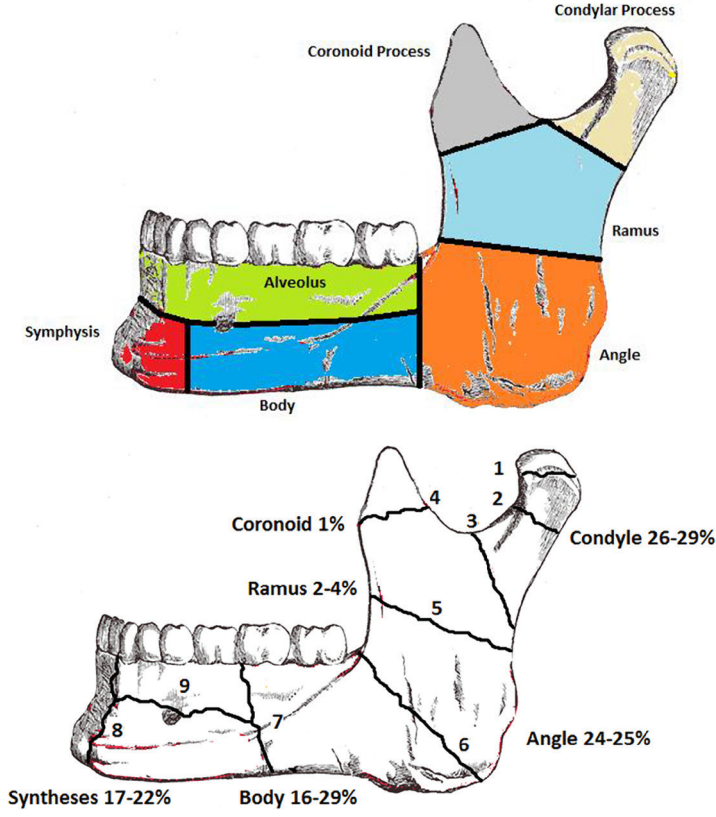
The inferior alveolar nerve (V3) courses through the mandibular body and angle. Fractures of the bony canal can cause temporary or permanent anesthesia of the lip, teeth, and gingiva. The lingual nerve (V3) lies close to the lingual cortex near the mandibular third molar. Injury may cause temporary or permanent anesthesia to the ipsilateral tongue and gingiva.

## III. Classification of Mandibular Fractures

Mandibular fractures are most commonly referred to their anatomic location as symphyseal, parashymphyseal, body, angle, ramus, alveolar, condyle, or coronoid (Figures 5.1 and 5.2). Table 5.1 provides additional descriptors regarding severity and displacement that can help in treatment planning.

**Figure 5.1**

Top: anatomic regions of the mandible. Bottom: mandibular fracture sites, condylar head (1), condylar neck (2), subcondylar (3), coronoid (4), ramus (horizontal or vertical) (5), angle (6), body (7), syntheses (synthesis and parasynthesis) (8), alveolar (9), and most common fracture locations.



**Figure 5.2**

Mandibular condyle with classification and distribution of fractures—condylar head, condylar neck, subcondylar.<sup>9-12</sup>

**Table 5.1. Descriptors Regarding the Severity and Displacement of Mandibular Fractures**

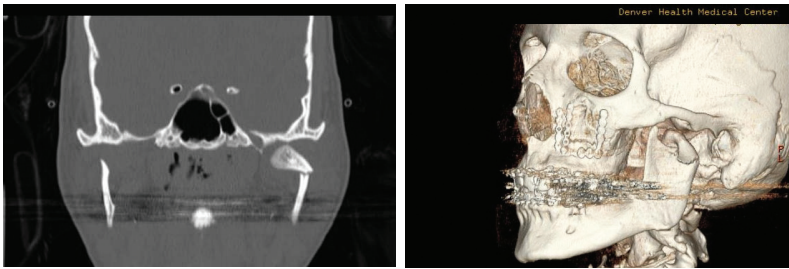
Fracture Terminology	Fracture Description
Compound or open fractures	Exposed to contaminated oral secretions usually involving erupted teeth.
Simple or closed fractures	Not exposed to oral secretions; usually nontooth-bearing bone.
Favorable fracture	Not distracted by muscle pull; requires less fixation.
Unfavorable fracture	Distracted by muscle pull; may require greater fixation to resist muscle pull.
Comminuted fracture	Crushed, fragmented, or splintered.
Complicated or complex fracture	Associated with significant injury to the adjacent soft tissues.
Multiple fractures	Two or more noncommunicating fractures on the same bone.
Indirect fracture	Located at a point not in alignment with or distant from the site of injury.
Impacted fracture	One fragment is driven firmly into the other fragment.
Greenstick fracture	One bony cortex is broken, and the other cortex is bent.
Pathologic fracture	Occurs through bone weakened by preexisting disease.
Atrophic fracture	From bone atrophy by loss of supporting alveolar bone in edentulous mandibles.

### A. CONDYLE FRACTURES

Condyle fractures are considered the most common fracture of the mandible. They are divided into the head, neck, and subcondylar regions (Figures 5.1 and 5.2).

Lindahl, Spiessl and Schroll, Krenkel, and Neff proposed complex condyle fracture classifications.<sup>10,11,13-15</sup> Ellis et al. classified condylar fractures as condylar head fracture (intracapsular fracture located at the border between the condylar head and neck), condylar neck fracture (located below the condylar head but on or above the lowest point of the sigmoid notch), and condylar base fracture (the fracture line isolated below the lowest point of the sigmoid notch).<sup>16</sup>

Most condylar fractures are currently treated closed (Figures 5.3). Evidence supporting open reduction of condylar fractures is growing, specifically subcondyle fractures and endoscopic techniques. Zide and Kent list absolute and relative indications for open reduction of the fractured mandibular condyle.<sup>17</sup> Palmieri and Throckmorton<sup>18</sup> and De Riu et al.<sup>19</sup> demonstrated better long-term range of motion and occlusion in patients with condylar fractures treated with open reduction and internal fixation (ORIF) versus closed reduction and maxillomandibular fixation (MMF). Absolute and relative indications are listed below under section V, Surgical Management.



**Figure 5.3**

Coronal and 3-D image of a left condyle fracture. In addition, the patient had a Le Fort I fracture and was treated with midface plating and MMF. She recovered mandibular range of motion and pretraumatic occlusion without open reduction of the condyle.

### **1. Condylar Head or Intracapsular Fractures**

Condylar head fractures are rarely encountered in adults. Prevalent clinical judgment is that MMF is generally contraindicated because of the high risk for TMJ ankylosis. Computed tomography (CT) scanning provides the most information about intracapsular fractures.

### **2. Condylar Neck and Subcondylar Fractures**

Condylar neck and subcondylar fractures are the most common mandibular fractures in adults (Figure 5.1). Subcondylar fractures are below the condylar neck. Fractures here enter the sigmoid notch and may be considered “high or low,” depending on the site of exit of the posterior extension of the fracture.

Most subcondylar fractures are also treated conservatively, using a closed approach to avoid complications. Subcondylar fractures offer sufficient bone stock for ORIF.

### B. FRACTURES OF THE MANDIBULAR ANGLE

The mandibular angle is the pie shaped area with its apex at the distal 3<sup>rd</sup> molar, also the site of the masseter attachment (Figure 5.1).

Fractures of this angle are common. They occur in 25 percent of adult fractures and result from the area weakened by the third molar tooth.

### C. FRACTURES OF THE MANDIBULAR BODY

The mandibular body is the horizontal mandible from distal symphysis to a vertical line distal to the 3<sup>rd</sup> molar tooth (Figure 5.1). Mandibular body fractures, such as symphyseal fractures, involve the dentition and require special attention to ensure an adequate occlusal reconstruction as well as bony repair.

Body fractures and angle fractures will be affected by muscle pull, which can produce a favorable fracture by reducing the fracture or an unfavorable fracture if the depressors and elevator muscles distract the fracture.

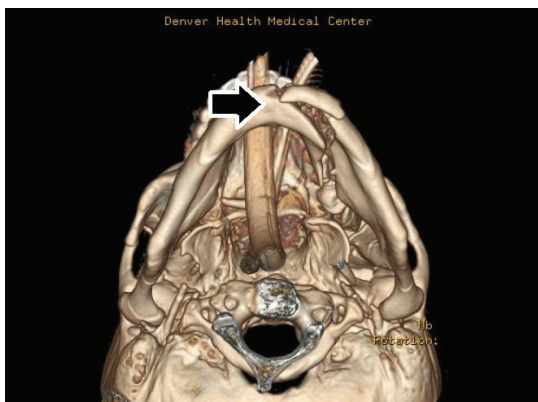
### D. FRACTURES OF THE SYMPHYSIS AND PARASYMPHYSIS

The symphysis is the area between vertical lines drawn distal to the mandibular canine teeth. Symphyseal and parasymphyseal fractures are usually caused by direct trauma to the chin, such as a fall that bends the mandible.

- A *symphyseal fracture* is a midline mandibular fracture between the central incisors.
- A *parasymphyseal fracture* is a non-midline fracture occurring within the symphysis.
- *Masseter muscle pull* will cause lingual displacement and rotation of the teeth. It will distract the fracture site, often causing a lingual splay, which requires overbending of the plate to adequately reduce the fracture (Figure 5.4).

#### Figure 5.4

A submental view of a comminuted parasymphyseal fracture (black arrow) and loss of v-shaped mandible and lingual splaying. Repair must include overbending of the buccal bone plates to reduce the lingual splay.





- *Canine area fractures* follow the bone weakened by the long canine tooth.
- *Bilateral fractures* may cause posterior displacement of the tongue and airway compromise. They may also involve the contralateral condyle fractures in up to 37 percent of the cases.<sup>20</sup>
- Children often have a *greenstick fracture* of the mandibular cortex.

### E. FRACTURES OF THE RAMUS

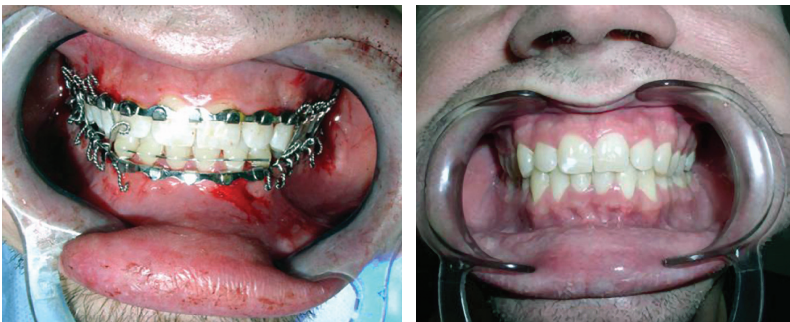
The ramus is the vertical portion of the mandible above the horizontal plane of the alveolar ridge, ending at the sigmoid notch. Fractures in the ramus are rare. They can be vertical, but are more often horizontal.

### F. FRACTURES OF THE CORONOID

The coronoid process is anterior-superior to the ramus. It serves as the attachment of the temporalis muscle. Coronoid fractures are rare and usually do not require treatment, unless they are involved in an impingement from a zygomatic fracture.

### G. ALVEOLAR (DENTOALVEOLAR) FRACTURES

The alveolar bone houses the dentition. This bone atrophies in the absence of teeth. Dentoalveolar fractures are common, but isolated alveolar fractures are rare. Dental luxation and alveolar segments may be fixated in the MMF, by separate ligatures, or by wire composite splinting, as seen in Figure 5.5.



**Figures 5.5**

Left, mandibular incisors region dental alveolar fracture held in place with wire-composite splint between canine teeth and MMF. Right, post-treatment photograph of intact dentition and bite, with retained lower incisors following dentoalveolar fracture.

## H. EDENTULOUS FRACTURES

### 1. Closed Reduction

A patient's dentures can be used as a splint, secured by circummandibular wires, circumzygomatic wires, nasal pyriform wires, or palatal screws.<sup>21</sup> When the denture is not available, a Gunning splint can be fabricated with built-in arch bars, as well as an anterior opening for feeding. This is secured in the same fashion as wiring the patient's denture to the mandible.

Biphasic external pin fixation or Joe Hall Morris appliance may be indicated for a discontinuity defect, for severely comminuted fractures, or when maxillomandibular or rigid fixation cannot be used.

### 2. Open Reduction

The complication rate for open reduction of the edentulous mandible is significant when the load is shared with small bone plates. To minimize the complication rate, the atrophic mandible requires a load-bearing repair using strong plates with multiple fixation points using bicortical screws.

Ellis and Price advocate an aggressive protocol of ORIF with rigid fixation and acute bone grafts. They demonstrated no complications with this approach, despite the advanced age and medical comorbidities of this patient population.<sup>21</sup>

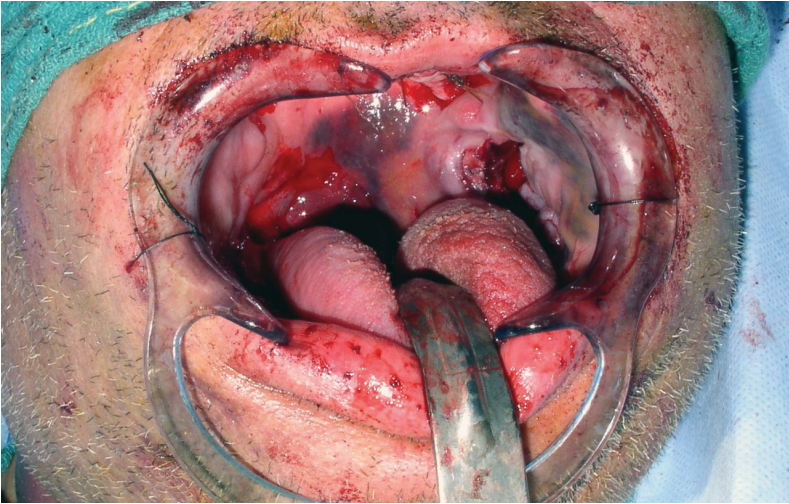
## IV. Diagnostic Evaluations

### A. FULL-BODY TRAUMA ASSESSMENT

Mandibular fractures are too often a small portion of a larger trauma picture. The traumatized patient is best served from a trauma team approach. Once the advanced trauma life-support protocols have been instituted, the airway has been stabilized, and breathing, circulation, and neurological status have been addressed, the secondary surveys can be initiated. The intact mandible supports the airway by anterior tongue attachment. The fractured mandible may risk the support of the tongue, and hemorrhage into the sublingual and submandibular spaces can cause the loss of the airway (Figures 5.6 and 5.7).

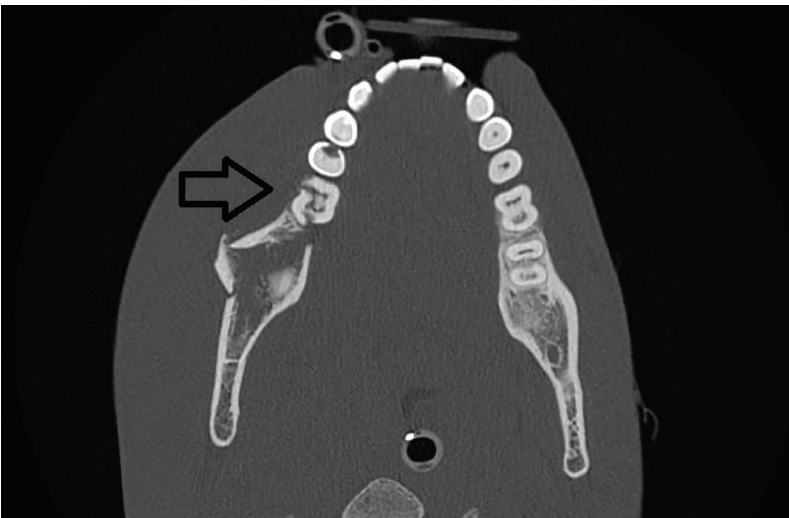
### B. TRAUMA HISTORY

A complete medical and psychiatric history is important for diagnosis and treatment planning. Medical history should include identification of the following prior to surgery: previous mandibular trauma, occlusal abnormalities, TMJ disease, and bleeding, endocrine, neurological,



**Figure 5.6**

Large progressive submandibular hemorrhage from a fractured mandible required urgent airway management.



**Figure 5.7**

Comminuted body and tooth fractures following a blow with a metal pipe. Mandibular fractures generally correspond to the "type of injury," in this case producing comminuted bone and tooth fractures from a hard object. This patient required urgent intubation due to loss of the airway from submandibular hemorrhage.

## CHAPTER 5: Mandibular Trauma

bone, and collagen disorders. The site (chin, body), direction and size, and source (fist, pipe) of the traumatic force are very helpful in identifying direct and indirect fractures of the mandible.

### C. HEAD AND NECK EXAMINATION

Evaluate the entire head and neck for facial lacerations, swellings, and hematomas. A common site for a laceration is under the chin. This should alert the clinician to the possibility of an associated subcondylar or symphysis fracture.

From behind the supine or seated patient, bimanually palpate the inferior border of the mandible from the symphysis to the angle on each side. Note areas of swelling, step deformity, or tenderness. Note areas of anesthesia along the distribution of the inferior alveolar nerve. Numbness in this region is almost pathognomonic of a fracture distal to the mandibular foramen.

Standing in front of the patient, palpate the movement of the condyle through the external auditory meatus. Pain elicited through palpation of the preauricular region should alert the clinician to a possible condylar fracture.

### D. ORAL EXAMINATION

Identify deviation on opening of the mouth. Deviation on opening is toward the side of a mandibular condyle fracture. Record inter-incisor opening.

Identify limited opening (trismus) from reflex muscle, TMJ edema, or coronoid impingement from a depressed zygomatic fracture. Changes in occlusion are highly suggestive of a mandibular fracture. A change in occlusion may be due either to a displaced fracture, fractured teeth, and alveolus or to injury to the TMJ.

Tears in the unattached mucosa or attached gingiva and ecchymosis in the floor of the mouth usually indicate a mandibular symphyseal or body fracture. If a mandibular fracture is suspected, grasp the mandible on each side of the suspected site and gently manipulate it to assess mobility.

### E. OCCLUSAL EVALUATION

#### 1. Angle Class I Occlusion

Angle Class I occlusion is the normal anteroposterior relationship of the mandible to the maxilla. The mesiobuccal cusp of the permanent

maxillary first molar occludes in the buccal groove of the permanent mandibular first molar (Figure 5.8).

## 2. Angle Class II Occlusion

Angle Class II occlusion is the posterior relationship of the mandible to the maxilla. The mesiobuccal cusp of the permanent maxillary first molar occludes *mesial* to the buccal groove of the permanent mandibular first molar.

## 3. Angle Class III Occlusion

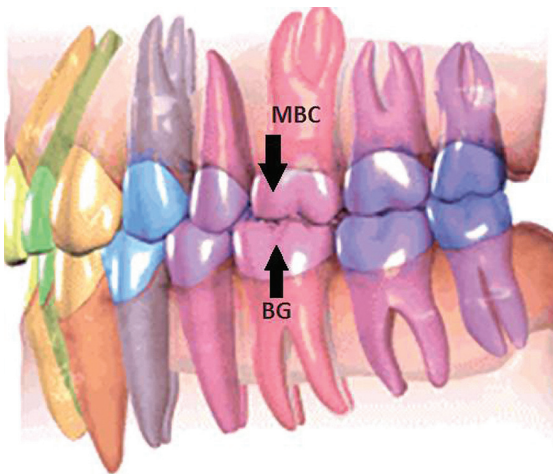
Angle Class III occlusion is the anterior relationship of the mandible to the maxilla. The mesiobuccal cusp of the permanent maxillary first molar occludes *distal* to the buccal groove of the permanent mandibular first molar.

## 4. Maximum Intercuspatation

Maximum intercuspation refers to the occlusal position of the mandible in which the cusps of the teeth of both arches fully interpose themselves with the cusps of the teeth of the opposing arch. This position is the goal in repositioning the teeth in proper occlusion during MMF.

## 5. Wear Facets

A wear facet is a highly polished wear pattern or spot on a tooth produced by an opposing tooth from chewing or grinding. It is useful in repositioning teeth into premorbid occlusion when a pre-existing malocclusion was present (crowding, spacing, midline misalignment).



**Figure 5.8**

Molar relationship in Class I occlusion, mesiobuccal cusp (MBC) of the upper first molar occludes with the buccal groove (BG) of the lower first molar.

## CHAPTER 5: Mandibular Trauma

### 6. Overjet and Overbite

Overjet is anterior vertical overlap, and overbite is anterior horizontal overlap. Both are measured in millimeters.

### 7. Skeletal Malocclusion

Skeletal disharmony of the maxillary and mandibular relationship, as identified on cephalometric assay, produces malocclusion of the upper and lower dentition. Most skeletal malocclusions can only be treated by orthognathic surgery.

### 8. Dental Malocclusion

Dental malocclusion is the misalignment of teeth or incorrect relation between the teeth of the maxilla and mandible. This term was coined by Edward Angle, the “father of modern orthodontics,” as a derivative of occlusion, which refers to the way opposing teeth meet. Most dental malocclusions are treated by orthodontic movement.<sup>22</sup>

### 9. Mesial

Mesial refers to the direction toward the anterior midline in a dental arch. Each tooth can be described as having a mesial surface and, for posterior teeth, a mesiobuccal and a mesiolingual corner or cusp.

### 10. Distal

Distal refers to the direction toward the last tooth in each quadrant of a dental arch. Each tooth can be described as having a distal surface and, for posterior teeth, a distobuccal and a distolingual corner or cusp.

### 11. Crossbite

A crossbite is a malocclusion where a single tooth or a group of teeth has a more buccal or lingual position and can be classified in anterior or posterior and bilateral or unilateral. Anterior crossbite is seen in Angle Class III skeletal malocclusion, while posterior crossbite correlates to a narrow maxilla.

### 12. Centric Occlusion and Centric Relation

Centric occlusion is the occlusion of opposing teeth when the mandible is in centric relation to the maxilla. Centric occlusion is the first tooth contact and may or may not coincide with maximum intercuspation. It is also referred to as a person’s habitual bite position. Centric relation should not be confused with centric occlusion, which is the relationship between the maxilla and mandible.

### 13. Vertical Dimension of Occlusion

This term is used in dentistry to indicate the superior-inferior relationship (height) of the maxilla and the mandible when the teeth are



situated in maximum intercuspation. Loss of facial and dental vertical dimension occurs with the loss of teeth.

#### 14. Identification of Adult and Pediatric Teeth

Adult teeth are numbered from 1 to 32, from the upper right to the lower right. Teeth that are in malocclusion or that have been lost to trauma should be identified, along with all missing teeth.

Pediatric teeth are lettered from A to T (20 teeth), also from the upper right to the lower right.

### F. IMAGING STUDIES

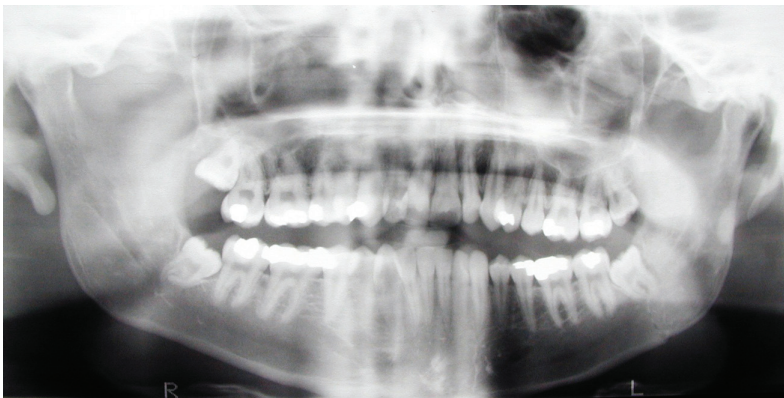#### 1. Mandible Series

Three films are used for isolated mandibular fractures:

- A posteroanterior (PA) showing a PA view of angle and ramus fractures.
- A reverse Towne of a PA view, showing medial/lateral displacement of condyle and subcondylar fractures.
- Bilateral oblique views for body and angle fractures.

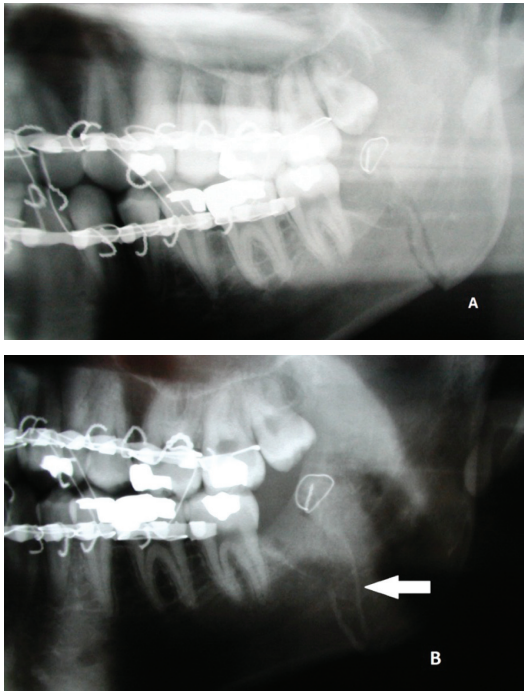
#### 2. Panorex

Panorex is a panoramic tomographic scan that shows the entire mandible, including condyles, on one film. It is an excellent screening evaluation study for the patient who is able to stand or sit upright without motion. Panorex offers low radiation, low cost, and excellent detail, and is excellent for follow-up evaluation (Figures 5.9 and 5.10).



**Figure 5.9**

Panorex film demonstrates a planar view of dentition, mandible, and condyles. Patient has a left angle fracture and widening of the periodontal ligament space on tooth #17.



**Figure 5.10**

Follow-up Panorex films of left angle fracture from Figure 5.9. (A) After MMF and wire osteosynthesis. (B) Postoperative check at 4 weeks, showing excellent healing and callus formation (white arrow).

### 3. CT Scan

A CT scan is ideal when visualization is difficult, especially visualization of the condylar head and high condylar neck. CT is generally the preferred method of imaging for multiple mandibular fractures, and is especially helpful in the multiply traumatized patient requiring images of the cervical spine, cranium, and carotid arteries. Also, 3-D CT scanning capabilities add immeasurably to the diagnosis and treatment planning of complex facial fractures.

### 4. MRI Scan

Magnetic resonance imaging (MRI) is better for evaluating soft-tissue disease, such as hematoma and complications of trauma.

### 5. Occlusal View

An occlusal view will show symphysis fractures.

### 6. Periapical Radiographs

Periapical radiographs show dental root fractures next to mandible and alveolar fractures.



## V. Surgical Management

### A. INDICATIONS FOR SURGERY

All mandibular fractures require some form of treatment, from soft diet to open reduction, and internal fixation with bone grafting. The type of treatment will depend on the severity of the fracture and whether additional facial bone fractures are present. The general treatment decision will be between open or closed fracture reduction.

The ability to treat fractures with ORIF has changed dramatically in recent years. Traditional 6-week treatment of closed reduction with MMF or open reduction with wire osteosynthesis and MMF has given way to early mobilization and restoration of jaw function, improved airway control, improved nutrition, improved patient comfort and hygiene, and an earlier return to work.<sup>23-25</sup> Some studies have shown that it may be more cost-effective to treat patients “at risk for” mandibular fracture with closed reduction treatment.<sup>26,27</sup> It has been our experience that the “at risk” unpredictable patient may be better off by not having removable hardware that can be removed or poorly maintained.

#### 1. Indications for Closed Reduction

##### **a. Nondisplaced Favorable Fractures**

Nondisplaced favorable fractures should be treated by the simplest method to reduce and fixate.

##### **b. Pediatric Fractures**

In pediatric fractures involving the developing dentition, open reduction can injure developing tooth buds or partially erupted teeth.<sup>28</sup> Pediatric condyle fractures are best managed by closed reduction and early mobilization after 2–3 weeks of MMF.

##### **c. Grossly Comminuted Fractures**

Grossly comminuted fractures can be treated by closed reduction to minimize periosteal stripping of bone fragments.

##### **d. Coronoid Fractures**

Coronoid fractures are rarely treated, unless there is impingement on the zygomatic arch.

##### **e. Adult Condyle Fractures**

Adult condyle fractures are controversial topics in maxillofacial trauma. Closed treatment is generally the appropriate choice, unless the patient

## CHAPTER 5: Mandibular Trauma

meets Valiati et al.'s criteria for open treatment.<sup>29</sup> If condylar fractures do not fall within these criteria, the patient can be treated with closed reduction for 2–3 weeks. When a condylar fracture is in association with other fractures of the mandible, the other fractures should be treated with ORIF, and the condylar fracture should be treated with closed reduction.

### 2. Contraindications to Closed Reduction

Contraindications to closed reduction MMF include patients with compromised pulmonary function with severe asthma or severe chronic obstructive pulmonary disease, poorly controlled seizures, psychiatric or neurologic disorders, and severe nausea or eating disorders.

### 3. Indications for Open Reduction

- Displaced unfavorable fractures through the angle of the mandible.<sup>30</sup>
- Atrophic edentulous mandibles, minimal cancellous bone, and poor osteogenesis and healing potential.
- Complex facial fractures requiring a stable mandibular base. These fractures require the mandibular segments to be reconstructed first with open reduction and fixation.
- Condylar fractures. While condylar fractures are generally treated with closed reduction, a specific group of individuals benefits from surgical intervention. Table 5.2 lists the absolute and relative indications for open reduction of the fractured mandibular condyle.<sup>17</sup> The relative indications remain a choice between surgical expertise and the desires of the patient.

## B. TIMING OF SURGICAL PROCEDURES

Mandibular fractures involving teeth are considered open, and should be treated in the preoperative period with antibiotics to reduce the risk of infection.<sup>32,33</sup> Traditional teaching recommends treatment within 24 hours of injury.<sup>34</sup> However more recent studies have shown no increase in complications due to delays in repair beyond 24 hours, although there may be an increase in technical complications of the repair.<sup>35–40</sup>

## C. SURGICAL EXPOSURE OPTIONS

Surgical exposure of the mandible is determined by the fracture type and location.

**Table 5.2. Absolute and Relative Indications for Open Condyle Reduction**

Absolute Indications	Relative Indications
Displacement of the condyle into the middle cranial fossa or external auditory canal.	Bilateral condylar fractures in an edentulous patient when splints are unavailable or impossible because of alveolar ridge atrophy.
Inability to obtain adequate occlusion. <sup>20</sup>	Bilateral or unilateral condylar fractures when splinting is not recommended because of concomitant medical conditions or when physiotherapy is not possible.
Lateral extracapsular dislocation.	Bilateral fractures associated with comminuted midface fractures.
Contaminated open joint wound.	Bilateral subcondylar fractures with associated: <ul style="list-style-type: none"> <li>▪ retrognathia or prognathism,</li> <li>▪ open bite with periodontal problems or lack of posterior support,</li> <li>▪ loss of multiple teeth and later need for reconstruction,</li> <li>▪ unstable occlusion due to orthodontics, and</li> <li>▪ unilateral condylar fracture with unstable fracture base.</li> </ul>

Source: Zide and Kent.<sup>17</sup>

The primary objectives of surgical reconstruction of the mandible are that access and reconstruction be tailored to meet the demand of the fracture repair. Simple fractures demand little or no access and should be treated in a simple closed fashion. More complex fractures that demand ORIF with plate osteosynthesis require careful planning to avoid cranial nerve injury, periosteal loss, and facial scarring. Reduction and fixation are adequate for the site to reduce the risk of nonunion, malunion, and malocclusion.

The mandible is separated into multiple areas anatomically (Figure 5.1). Each fractured region has unique qualities, depending on the extent of the fracture, the stresses placed on the fractured bone by muscles, the size and strength and healing ability of the bone at that site, oral contamination, and the overlying structures complicate a repair approach. Treatment of mandible fractures will be divided into closed and open fracture reduction and soft tissue approaches to the mandible.

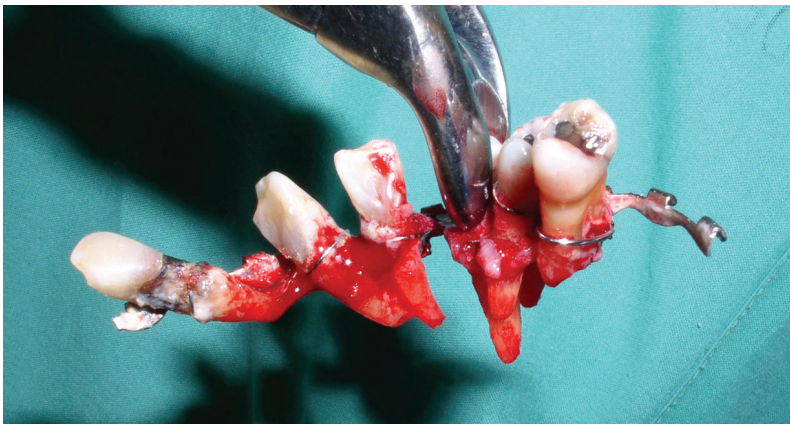## CHAPTER 5: Mandibular Trauma

### 1. Closed Reduction

Closed reduction can be accomplished with a variety of techniques with and without the dentition. When teeth are present, circumdental wire, arch bars, IMF screws, acid etch brackets are used.

#### *a. Erich Arch Bars*

Arch bars are considered the standard in MMF. These are cut and fitted on both dentitions. If intended for long term use, patients must be aware of the risks to teeth and periodontum and have adequate follow-up care (Figure 5.11).



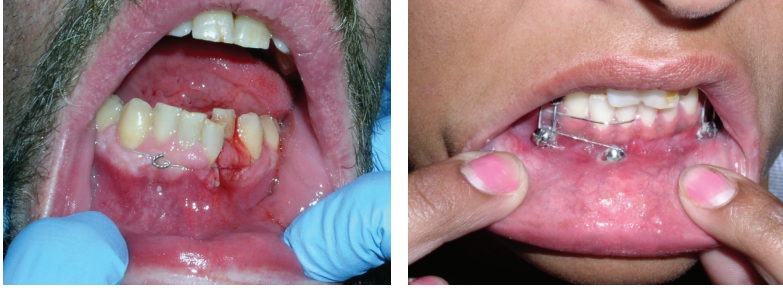**Figure 5.11**

Photo of arch bars retained in a patient for 4 years who had forgotten to make a follow-up appointment.

- Start by counting 18 lugs.
- Position the bars so the lugs open away from the crowns to allow MMF wires.
- Use 24-gauge stainless steel circumdental wires twisted closed in a clockwise rotation. Wires may be prestretched to lessen wire stretching and loosening after surgery. Factory-cut wires may be less sharp and may lessen the risk of puncture injury.
- Position the patient into maximum intercuspation, and place MMF wires or elastics.

### **b. Bridle Wire**

Bridle wire is a single ligature placed for temporary stabilization of mobile fractures (Figure 5.12). Bridle wire is often placed under local anesthesia. Teeth adjacent to the fracture should be avoided.

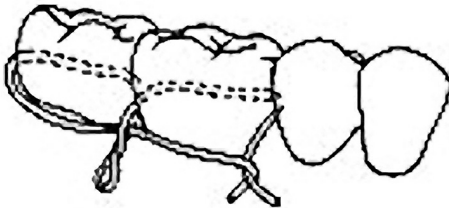


**Figure 5.12**

Bridle wire placed to reduce discomfort is stabilizing a parasymphyseal fracture (left). Bridle wire and IMF screws are stabilizing a nondisplaced parasymphyseal fracture (right).

### **c. Ivy Loops**

Ivy loops are used for MMF for minimally displaced fractures when the full patient has a full dentition. The loop is constructed with 24-gauge wire. A small loop is made in the center of the wire (Figure 5.13). The loose ends are passed through the interproximal of two stable teeth, brought around the mesial and distal interproximal of each tooth. The distal wire is brought under (or through) the loop and anchored to the mesial wire with a clockwise twist. An opposing loop is then created to make a pair. The loop produced is then used to pass a third 24-gauge wire to anchor the MMF wire. A minimum of two sets of Ivy loops is recommended bilaterally.



**Figure 5.13**

Ivy loop passed between the interproximal space of #30 and #31.

## CHAPTER 5: Mandibular Trauma

### **d. IMF Screws**

IMF screws are 2.5-mm stainless steel self-drilling and -tapping screws in 8- and 12-mm lengths. These temporary screws are used for minimally displaced fractures when the patient has a full dentition. They are placed in the anterior jaw in the unattached mucosa on either side of the canine teeth roots. Care is taken not to compress the gingiva or damage tooth roots. If placing the screws posteriorly on the mandible, the mental nerve must be avoided. Also, the infraorbital nerves may be injured if the screws are placed too high on the maxilla.

## **2. Open Reduction**

Surgical approaches must be tailored to meet the demand of the soft tissue and bony fracture repair. The ideal osteosynthesis system of mandibular fractures must meet hardness and durability criteria to handle functional changes and allow bone healing.

### **a. Use of Existing Lacerations**

Soft tissue injuries often accompany facial fractures and can be used to directly access the fractured bone for open repair.

### **b. Intraoral Approach**

Advantages of an interoral approach include expediency, no facial scar, low risk to facial nerve, and performed under local anesthesia.

#### *i. Labial Sulcus Incision*

Symphysis and parasymphysis fractures are easily accessed through a labial sulcus incision. The mental nerve is identified between the roots of the first and second bicuspid.

Labial sulcus incision can be made on the lip vestibular mucosa through the mentalis muscle then to the bone. This incision improves a watertight closure and reduces saliva contamination by having the closure out of the sulcus. In addition, postoperative chin tape can compress the dead space over the chin.

#### *ii. Vestibular Incision*

Body, angle, and ramus fractures can be accessed through a vestibular incision that may extend past the external oblique line to the mid-ramus. The ramus and the subcondylar region can be exposed by stripping and elevating the buccinator muscle and temporalis tendon at the coronoid process with a lighted notched ramus retractor.

### **c. Submental and Submandibular Approach**

The submental approach is used to treat fractures of the anterior mandibular body and symphysis.

The submandibular approach was described by Risdon in 1934.<sup>41,42</sup>

- Make the incision 2 centimeters (cm) below the angle of the mandible in a natural skin crease.<sup>43</sup>
- Dissect through skin, subcutaneous fat, and superficial cervical fascia to expose platysma muscle.
- Dissect the platysma, identify the superficial layer of the deep cervical fascia. The marginal mandibular nerve is deep to this layer.<sup>44</sup>
- Dissect through deep cervical fascia with the aid of a nerve stimulator/monitor to the mandibular bone.
- Dissect down to the level of the pterygomassitric sling, dividing it to expose bone.

#### **d. Retromandibular Approach**

The retromandibular approach was described by Hinds in 1958.<sup>45,46</sup>

- Make a vertical incision 0.5 cm below the lobe of the ear, and continue it inferiorly 3.0–3.5 cm. It should be behind the posterior mandibular border and should extend to the level of the angle.
- Dissect through the platysma and superficial musculoaponeurotic layer and parotid capsule.
- Consider using the aid of a nerve stimulator or facial nerve monitor, as the marginal mandibular branch and the cervical branch of the facial nerve may be encountered here.
- The retromandibular vein runs vertically in the parotid and should be identified and ligated or retracted to gain access to the lateral mandible.
- Sharply incise the pterygomasseteric sling and elevate the muscle off the lateral surface of the mandible superiorly. This will give access to the ramus and subcondylar region of the mandible.

#### **e. Preauricular Approach**

The preauricular approach is excellent for exposure to the TMJ.<sup>47,48</sup>

- Make the incision in the preauricular fold 2.5–3.5 cm in length, as described by Thoma<sup>48</sup> and Rowe.<sup>49</sup> Take care not to extend the incision inferiorly, since it may encounter the facial nerve as it enters the posterior border of the parotid gland.
- Carry the incision and dissection along the lateral perichondrium of the tragal cartilage.
- Superiorly, if the temporal fascia is encountered, the dissection should be carried deep through the superficial temporal fascia or the temporoparietal fascia. The aid of a nerve stimulator or facial nerve monitor should be considered if the dissection approaches the orbital or frontal branch of the facial nerve.

## CHAPTER 5: Mandibular Trauma

- Make an incision through the outer layer of the temporalis fascia from the root of the zygomatic arch anterosuperiorly toward the upper corner of the retracted flap. Through this temporalis fascia incision and deep to the fascia, insert the periosteal elevator approximately 1 cm and sweep the elevator back and forth.
- Following the periosteal elevator dissection, sharply release the intervening tissue posteriorly along the plane of the initial incision, and retract this flap anteriorly, exposing the joint capsule.
- Avoid opening the joint capsule, unless it is required for fracture repair.

### **f. Facelift (Rhytidectomy) Approach**

The facelift approach provides the same exposure as the retromandibular and preauricular approaches combined. However, the skin incision is placed in a more esthetic location.

### **g. Intraoral Approach to the Condyle**

The ramus and condyle region can be exposed via an intraoral approach by extending the standard vestibular incision in a superior direction up the ascending ramus. Transoral endoscopic techniques through this incision are broadening the indications for open reduction of condylar fractures by protecting the facial nerve and offering the patient minimal facial scarring.<sup>50-53</sup>

## **3. Osteosynthesis**

Osteosynthesis is the reduction and fixation of a bone fracture with implantable devices.

### **a. Wire Osteosynthesis**

Wire osteosynthesis is used for limited definitive fixation and is helpful in alignment of fractures prior to rigid fixation. Though wire osteosynthesis is now rarely used for definitive fixation since the advent of rigid fixation,<sup>54</sup> it is useful for helping to align fractured segments prior to rigid fixation.

Wire osteosynthesis may be placed by an intraoral or extraoral route. The wire should be a prestretched soft stainless steel to reduce stretching and loosening postoperatively. The direction of the pull of the wire should be placed perpendicular to the fracture site.

A figure-of-eight wire can produce increased strength over the straight wire when used at the inferior or superior border of the mandible.

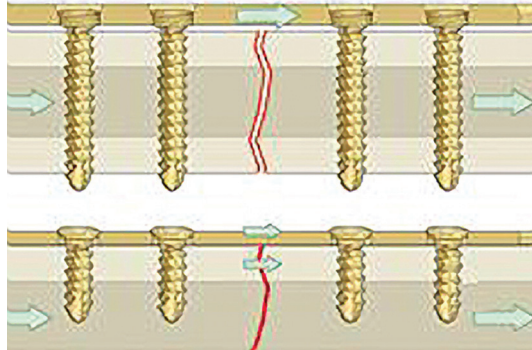


### **b. Plate Osteosynthesis**

Plate fixation can be a “load-bearing” or “load-sharing” osteosynthesis (Figure 5.14).<sup>55</sup>

**Figure 5.14**

The upper image demonstrates a load-bearing plate used when the bone cannot bear the functional forces. In the lower image, the bone stock is sufficient to help a smaller load-sharing plate bear these forces.



#### *i. Load-Bearing Osteosynthesis*

Load-bearing osteosynthesis requires a rigid plate to bear the entire force of movement at the fracture during function. Load-bearing plates are indicated for comminuted fractures and fractures of atrophic edentulous.

#### *ii. Load-Sharing Osteosynthesis*

Load-sharing osteosynthesis creates fracture stability with shared buttressing by significant bone contact and the plate used for fixation. This requires adequate bone stock at the fracture site to create resistance to movement. Examples of load-sharing osteosynthesis include lag-screw fixation,<sup>56</sup> compression plating, and a miniplate fixation technique popularized by Champy.<sup>34</sup> Load-sharing osteosynthesis cannot be used in comminuted or atrophic edentulous fractures because of lack of bone buttressing at the site.

Ellis demonstrated that load-sharing miniplate fixation had markedly less major complications than a rigidly fixated load-bearing fixation.<sup>37,56</sup> Singh found no significant difference in incidence of complications in mandible fractures treated with the Champy miniplate technique or 3-dimensional miniplate fixation.<sup>57</sup>

## **4. Surgical Treatment**

Information about surgical treatment can be found on the AO Foundation’s (Davos, Switzerland) Web site<sup>55</sup> and other sites.

## CHAPTER 5: Mandibular Trauma

### **a. Symphysis and Parasymphysis**

- Mandibular symphysis undergoes twisting (torsion) forces. Simple fractures can be treated with arch bars and 6 weeks of MMF alone.
- Wire osteosynthesis requires using 24-gauge (0.5-mm) inferior border wire and MMF.
- Plate osteosynthesis requires two straight plates or a reconstruction plate. The farther apart (superior/inferior) the plates, the more stable the fracture site.
- Reduction can be assisted by inferior border wire or monocortical screws/clamp.
- Mental nerve and tooth root injury must be avoided.

### **b. Body**

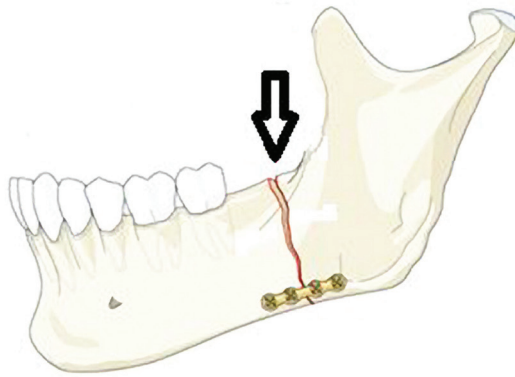
- Simple body fractures can be treated with arch bars and 6 weeks of MMF alone. They can also be treated with MMF with miniplate fixation.
- Wire osteosynthesis requires using 24-gauge (0.5-mm) superior border wire and MMF.
- Utilize multiple lag screw fixation of fractures in a sagittal plane with appropriate overlap.
- Plate osteosynthesis requires two straight plates or a reconstruction plate.
- Complex fractures and edentulous fractures require reconstruction plate fixation.

### **c. Angle**

- Simple fractures can be treated with arch bars and 6 weeks of MMF alone.
- Wire osteosynthesis requires using 24-gauge (0.5-mm) superior border wire and MMF.
- Champy showed that functional loading of a simple angle fracture creates tension (distraction) on the upper border of the fracture and is treated by a tension band. Failure to do this allows the fracture to open (Figure 5.15). In the same regard, compression occurs on the lower border during functional loading and stabilizes this portion of the fractured bone. The Champy miniplate fixation technique extends medial to lateral over the external oblique ridge. For additional stability, a second inferior border plate via transcutaneous trocar technique can be added to the Champy technique or to a superior border plate.
- Complex fractures may require reconstruction plate fixation.

**Figure 5.15**

Insufficient fixation of a mandibular fracture can result in fixation failure, infection, malocclusion, and nonunion. Lack of a tension band here allows muscle pull and occlusal forces to open the site.



**d. Condyle**

- All condylar fractures can be treated closed with MMF and/or with functional therapy using immediate function with elastics.
- Open access may be external, transoral, or transoral endoscopic-assisted ORIF. The endoscopic-assisted technique is similar in fixation, but requires a learning curve for fragment manipulation and one and two plate reduction strategies.
- Open techniques may require facial nerve protection using a facial nerve stimulator, or monitoring before induction of muscle relaxants during general anesthesia.
- Two techniques for plating are a single 2.0 mandibular plate with two screws on each side of the fracture, or two miniplates in triangular fashion, one below the sigmoid notch and one along the posterior border.
- Reduction and manipulation of the fracture are best accomplished with a mobile jaw.

**e. Additional Considerations**

*i. Locking versus Nonlocking Plates*

Tightening screws on a malformed nonlocking plate will draw the bone segments toward the plate, which may affect the occlusion. Locking plates do not do this. They also preserve cortical bone perfusion and are unlikely to loosen from the plate.

*ii. Comminuted Fractures*

Reduce the main fragments by fixing them into occlusion with MMF. Then using miniplates, realign the comminuted fragments to establish bony continuity before placing the reconstruction plate if indicated.

## CHAPTER 5: Mandibular Trauma

### *iii. External Fixator or Alternative Biphasic Pin Fixation*

External fixator or alternative biphasic pin fixation can be used for bone healing. However, neither provides the same degree of stability as reconstruction plates. Therefore, they should be considered temporary, rather than definitive.

## **VI. Prevention and Management of Complications**

### **A. INFECTION PREVENTION**

Antibiotics reduce the risk of infection when given in the preoperative period, especially in open fractures.<sup>32,33</sup> However, antibiotics may not improve infection rate in the postoperative period.<sup>58,59</sup>

Infections are generally oral flora, which are mixed infections containing streptococci and anaerobes. Treatment is surgical drainage and debridement and prolonged antibiotic therapy.

Systemic factors include alcoholism, immunocompromised patients, and poorly controlled diabetes. Local factors include poor reduction and immobilization, poorly closed oral wounds, fractured teeth in the line of fracture, diminished blood supply, devitalized tissue, and comminuted fractures.

### **B. TEETH IN LINE OF FRACTURE**

Removal of teeth in the line of fracture should be evaluated for retention first, as studies have shown that most teeth will recover function. Teeth with crown fracture and pulp exposure may be retained if emergency endodontics is planned.

Tooth removal is recommended if the tooth is luxated from its socket or interfering with fracture reduction, if the tooth or root is fractured, or if the tooth has nonrestorable caries or advanced periodontal disease or damage.

A bony impacted third molar can be retained when it stabilizes the fracture, but should be removed if partially erupted and associated with pericoronitis or follicular cyst formation.<sup>60-62</sup>

### **C. DELAYED UNION AND NONUNION**

Delayed union is a temporary condition that may progress to nonunion without adequate reduction and immobilization.

Nonunion is the failure of bone healing between the fractured segments. It is characterized by pain and abnormal mobility at the fracture site following treatment, and occurs in 3-5 percent of fractures. The most common cause of nonunion is inadequate reduction and

immobilization. Other causes include infection, inaccurate reduction, and lack of contact between fragments, traumatic ischemia, and periosteal stripping.

Alcoholism is a major contributor to both delayed union and nonunion, combined with poor compliance, poor nutrition, poor oral hygiene, and tobacco abuse.

Treatment of delayed union and nonunion includes identifying the cause, controlling infection, surgically debriding devitalized tissues, removing existing hardware, refreshing the bone at fracture ends, reestablishing correct occlusion, stabilizing segments with a 2.4 locking plate, and grafting autogenous bone.

#### **D. MALUNION**

Malunion is the improper alignment of the healed bony segments. It is caused by improper reduction, inadequate occlusal alignment during surgery, imprecise internal fixation, or inadequate stability of the fracture site.

Not all malunions are clinically significant. When teeth are involved in the malunion, a malocclusion may result.

Treatment of malunion often requires identification of the cause, and then orthodontics for small discrepancies or an open surgical approach with standard osteotomies, refracturing, or both.<sup>63</sup>

#### **E. TMJ ANKYLOSIS**

Ankylosis is a process where the mandibular condyle fuses to the glenoid fossa. It results from intra-articular hemorrhage, which leads to joint fibrosis and eventual ankylosis. Ankylosis may also cause underdevelopment due to injury of the mandibular growth center.

Ankylosis can be prevented by using shorter periods of MMF (2-3 weeks) and physiotherapy. Treatment may require additional surgery in the form of a gap arthroplasty or total alloplastic joint replacement.

#### **F. TRIGEMINAL (FIFTH) NERVE INJURY**

The fifth nerve, or inferior alveolar nerve and its branches, is the most commonly injured nerve in mandibular fracture. The deficit is numbness or other sensory changes in the lower lip and chin. Most of the sensory and motor functions of these nerves improve and return to normal with time. Iatrogenic injury must be avoided when treating fifth nerve injury.

#### **G. FACIAL (SEVENTH) NERVE INJURY**

Seventh nerve assessment in the severely traumatized patient may be difficult if the patient is obtunded and facial nerve testing is limited to

## CHAPTER 5: Mandibular Trauma

observing grimacing with painful stimulation. The nerve can be injured anywhere throughout its course.

Three major areas of concern for facial nerve injury is to the main trunk in the region of the condylar neck, marginal mandibular nerve injury in the submandibular approach, and frontal branch injury in the preauricular approach to the condyle.

Facial nerve monitoring should be considered on open approaches to avoid further injury.

### H. FIXATION FAILURE

Fixation failure results in fracture mobility that can lead to nonunion, malunion, or infection. Causes include insufficient fixation, fracture of the plate, loosening of the screws, and devitalization of the bone around the screws (Figure 5.15).

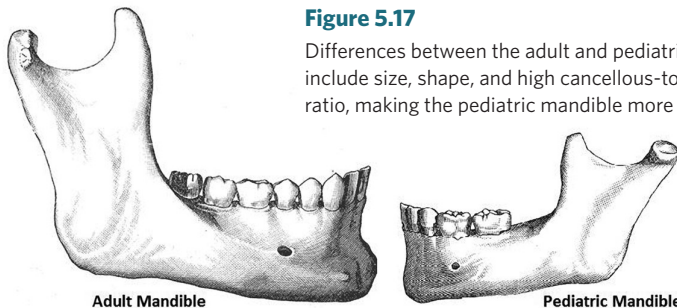
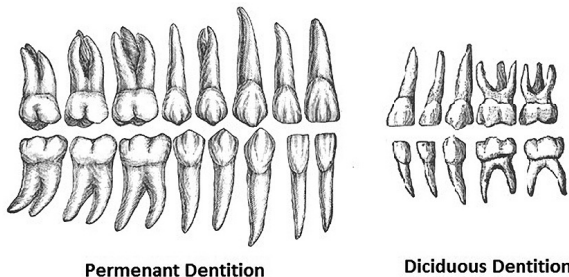
## VII. Pediatric Mandibular Fractures

### A. PEDIATRIC DENTAL AND SKELETAL ANATOMY

The dentition (Figure 5.16) and mandible (Figure 5.17) in children are very different from those in adults. Pediatric teeth have poor retentive

**Figure 5.16**

Differences in crown and root structure between permanent and deciduous teeth.



**Figure 5.17**

Differences between the adult and pediatric mandible include size, shape, and high cancellous-to-cortical ratio, making the pediatric mandible more flexible.

qualities, the roots are short and narrow, and the crowns have reduced retention contours, making them poor candidates for circumdental wire fixation. The pediatric mandible fracture patterns are due to mixed dentition developing permanent tooth buds, and to high greenstick pathologic fractures due to the high cancellous-to-cortical-bone ratio, giving the pediatric mandible more elasticity.<sup>64-66</sup>

A child's condyle is the growth center for the mandible. Thus, trauma or iatrogenic injury may cause growth retardation, malocclusion, and facial asymmetry.

## **B. FREQUENCY OF PEDIATRIC MANDIBULAR FRACTURES**

Although less frequent than in adults and second to nasal fractures, mandibular fractures are the most common facial fracture reported in hospitalized pediatric trauma patients.<sup>67-70</sup> The impact is usually absorbed by the large skull.

Children ages 6-15 have a higher percentage of luxation, avulsion, fractures, and dislocations. Mandibular fractures are rare in children under 5 years. MacLennan has shown under 6 years at 1 percent,<sup>67</sup> children aged 6-11 at 5 percent,<sup>68</sup> and under 16 years 7.7 percent.<sup>69</sup>

The distribution between the sexes is similar to a 2:1 male predominance for all mandibular fractures and an 8:1 predominance for condylar fractures.

## **C. MANAGEMENT OF PEDIATRIC MANDIBULAR FRACTURES**

Closed reduction is recommended for mandibular fractures to prevent damage to the developing permanent dentition.<sup>71</sup> Dental impressions and dental model surgery may be necessary to build a lingual splint to reduce and immobilize pediatric mandibular fractures. If wire osteosynthesis is required, it should be limited to the inferior border of the mandible.

Condyle fractures in children are best managed by closed reduction to avoid joint injury and growth retardation sequella.<sup>72</sup> Early physiotherapy in 7-10 days will avoid restriction of joint movement.<sup>73</sup>

### **1. Imaging Pediatric Mandibular Fractures**

#### **a. Mandibular Series**

- *Lateral oblique*—View from the condyle to the mental foramen.
- *Posteroanterior (PA)*—View of the ramus, angle, and body.
- *Reverse Towne (PA)*—Medial/lateral displacement of condylar fractures. Better than Panorex in acute care setting.

## CHAPTER 5: Mandibular Trauma

### **b. Panorex**

Panorex is difficult in the critically injured and uncooperative. It is the study of choice for mandible fractures.

### **c. CT Scanning**

CT scanning provides a thin cut with three-dimensional and multiplanar reconstructions. It is especially useful for TMJ evaluation.

### **d. Occlusal Views**

Occlusal views are used for evaluating symphyseal displacement.

### **e. Periapical Radiographs**

Periapical radiographs are used for evaluating root and alveolar fractures.

## **2. Treating Pediatric Mandibular Fractures**

The general management principles for treating pediatric mandibular fractures are similar to those for adults, but differ because of the mixed dentition. Restoration of occlusion, function, and facial balance is required for successful treatment. The developmental growth of the child's face must be taken into consideration.<sup>74-77</sup> Proper treatment may prevent complications, such as growth disturbance and infection.

- *Younger than 2 years*—Before age 2, a child's jaws are often edentulous. Mandibular fracture would require an acrylic splint fixed with circummandibular wires. If immobilization of the jaw is necessary, the splint may be fixed to both occlusive surfaces, with both circummandibular wires and wires through the pyriform aperture.<sup>78,79</sup>
- *6-12 years*—At ages 2-5 years, deciduous teeth are present and conical in shape (Figure 5.17). Interdental wiring may be used for fixation. Arch bars are difficult to secure below the gum line, and may require resin to attach wire for fixation.
- *6-12 years*—In this age group, the mixed dentition, primary teeth are resorbing and often are loose. In children 5-8 years, deciduous molars may be used for fixation, and in children 7-11 years, the primary molars and incisors may be used for fixation. When dentition is not available, splints may be used.
- *9-12 years*—In this age group, MMF using arch bars is possible, because enough permanent dentition is present.

Healing in children is rapid and often requires 10-20 days of immobilization. Delay in treatment may require callus removal for proper reduction. When ORIF is necessary the use of monocortical screws should be considered at the inferior mandibular border to prevent damage to developing permanent dentition. Resorbable polylactic and



polyglycolic acid plates and screws may reduce the long-term implant related complications.<sup>44,80-82</sup>

### 3. Treating Pediatric Condylar Fractures

Pediatric condylar fractures are rare, occurring in 6 percent of children younger than 15 years.<sup>81</sup>

Condylar fractures are classified into three groups: (1) Intracapsular (articular cartilage) condylar fractures; (2) high condylar fractures, which occur above the sigmoid notch; and (3) low subcondylar fractures, which usually are greenstick fractures in children and are the most common type of pediatric mandibular fracture overall.

- *Younger than 3 years*—In children younger than 3 years, the condylar neck is short and thick (Figure 5.17). Traumatic forces generally concentrate on the articular cartilage. Injuries to the articular cartilage may cause hemarthrosis, subsequent bony ankylosis, and affects mandibular growth. Early range of motion is important in preventing this complication.
- *Younger than 5 years*—In children younger than 5 years, crush injuries to the articular disk are more common.
- *Over 5 years*—In children over 5 years, simple neck fractures are more common. Most are treated nonoperatively with early treatment, including analgesics, soft diet, and progressive range-of-motion exercise.

#### **a. Immobilization in MMF**

Comminuted and displaced fractures of the head and condyle are immobilized in MMF for 2 weeks. Bilateral fractures causing open bite, severe movement limitation, or deviation are immobilized in MMF for 2-3 weeks. This is followed by 6-8 weeks of guiding elastics to counteract posterior ptergomasseteric muscle sling pull that shortens the posterior mandible and opens the bite anteriorly.

#### **b. Open Reduction**

With similar indications as adults, open reduction is indicated for (1) dislocation of the mandibular condyle into the middle cranial fossa, (2) condylar fractures prohibiting mandibular movement, and (3) in some cases, bilateral condylar fractures causing reduced ramus height and anterior open bite. However, for most bilateral condylar fractures, immobilization only is recommended. Depending on the fracture site, the open surgical approach to the pediatric condyle is similar to that of the adult condyle.

## CHAPTER 5: Mandibular Trauma

### 4. Treating Pediatric Body and Angle Fractures

- Greenstick fractures are managed with soft diet and pain control.
- Minimal to moderate displacement is treated with MMF with or without elastics.
- Angle fractures cannot be treated with dental splints.
- An extraoral open reduction approach may be indicated for severe displacement.

### 5. Treating Pediatric Dentoalveolar Fractures

Dentoalveolar injuries range from 8 percent to 50 percent of pediatric mandibular fractures.

#### a. Primary Teeth

Replacement of primary teeth is unnecessary. Primary teeth act as space holders for the permanent dentition. Space-holding appliances may be needed after the premature loss of primary teeth in trauma.

#### b. Permanent Teeth

- Permanent teeth should be reinserted within 2 hours. The teeth may be transported in saline or milk.
- Single or multiple teeth may be fixated with wire-acid etch composite splinting using stainless steel wire. Care should be taken to avoid the gingiva and the opposing teeth (Figure 5.12).
- The fractured segment may be reduced, and the patient is placed in MMF.
- Large fractured segments may require plate-screw fixation, if this is possible without injuring the teeth.

## VIII. References

1. Peltier J, Ryan MW. Mandible fractures. Grand Rounds Presentation. Galveston, Texas: University of Texas Medical Branch, Department of Otolaryngology; May 26, 2004. Accessed at: <http://www.utmb.edu/otoref/grnds/Mandible-fx-040526/Mandible-fx-040526.htm>.
2. Barton JR. A systemic bandage for fractures of the lower jaw. *Am Med Recorder Phila.* 1819;2:153.
3. Gunning TB. Treatment of fracture of the lower jaw by interdental splints, I. *Amer J Dent Sci.* 1868;2:53-55.
4. Gilmer TL. A case of fracture of the lower jaw with remarks on treatment. *Arch Dent.* 1887;43(4):388.

5. Erich JB, Austin LT. *Traumatic Injuries of the Facial Bones: An Atlas of Treatment*. Philadelphia, PA: WB Saunders Co; 1944:203 ff.
6. Gilardino MS, Chen E, Bartlett SP. Choice of internal rigid fixation materials in the treatment of facial fractures. *Craniomaxillofac Trauma Reconstr*. 2009;2(1):49-60.
7. Moon H. Mechanical appliances for treatment of fracture of the jaws. *Br J Dent Sci*. 1874; 17:303.
8. Spiessl B. Rigid internal fixation of fractures of the lower jaw. *Reconstr Surg Traumatol*. 1972;13:124-40.
9. MacLennan WD. Consideration of 180 cases of typical fractures of the mandibular condylar process. *Br J Plast Surg*. 1952;5:122-128.
10. Lindahl L. Condylar fractures of the mandible; I. Classification and relation to age, occlusion, and concomitant injuries of the teeth and teeth-supporting structures, and fractures of the mandibular body. *Intl J Oral Surg*. 1978;6(1):12-21.
11. Bradley PF. Injuries of the condylar and coronoid processes. In: Rowe NL, Williams JL, eds. *Maxillofacial Injuries*. Edinburgh, Scotland: Churchill Livingstone; 1985:337-362.
12. Luc MH, Smets PA, Van Damme PJ, Stoelinga W. Non-surgical treatment of condylar fractures in adults: A retrospective analysis. *Journal of Cranio-Maxillofacial Surgery*. June 2003;31(3):162-167.
13. Spiessl B, Schroll K. Gesichtsschadl. In: Nigst H, ed. *Spezielle Fracturen- und Luxationslehre*. Vol. I, Ch. 1. Stuttgart, Germany: Thieme; 1972.
14. Krenkel C. Treatment of mandibular condylar fractures. *Atlas Oral Maxillofac Surg Clin North Am*. 1997;5(1):127-155.
15. Neff A, Mühlberger G, Karoglan M, et al. Stability of osteosyntheses for condylar head fractures in the clinic and biomechanical simulation. *Mund Kiefer Gesichtschir*. 2004;8(2):63-74 [German].
16. Ellis E 3rd, Moos KF, el-Attar A. Ten years of mandibular fractures: An analysis of 2,137 cases. *Oral Surg Oral Med Oral Pathol*. Feb 1985;59(2):120-129.
17. Zide MF, Kent JN. Indications for open reduction of mandibular condyle fractures. *J Oral Maxillofac Surg*. Feb 1983;41(2):89-98.

## CHAPTER 5: Mandibular Trauma

18. Palmieri C, Ellis E 3rd, Throckmorton G. Mandibular motion after closed and open treatment of unilateral mandibular condylar process fractures. *J Oral Maxillofac Surg.* Jul 1999;57(7):764-75; discussion 775-776.
19. De Riu G, Gamba U, Anghinoni M, Sesenna E. A comparison of open and closed treatment of condylar fractures: A change in philosophy. *Int J Oral Maxillofac Surg.* Oct 2001;30(5):384-389.
20. Olson RA, Fonseca RJ, Zeitler DL, Osbon DB. Fractures of the mandible: A review of 580 cases. *J Oral Maxillofac Surg.* Jan 1982;40(1):23-28.
21. Ellis E 3rd, Price C. Treatment protocol for fractures of the atrophic mandible. *J Oral Maxillofac Surg.* Mar 2008;66(3):421-435.
22. Gruenbaum, Tamar. Famous figures in dentistry mouth. *JASDA.* 2010;30(1):18.
23. Schneider M, Erasmus F, Gerlach KL, Kuhlisch E, Loukota RA, Rasse M. Open reduction and internal fixation versus closed treatment and mandibulomaxillary fixation of fractures of the mandibular condylar process: A randomized, prospective, multicenter study with special evaluation of fracture level. *J Oral Maxillofac Surg.* Dec 2008;66(12):2537-2544.
24. Sorel B. Open versus closed reduction of mandible fractures. *Oral and Maxillofacial Surgery Clinics of North America.* 1998;10:553.
25. Manson PN. Facial fractures. Chapter 66 in: Mathes SJ. *Plastic Surgery.* Vol. 3. 2nd ed. Philadelphia, PA: Saunders Elsevier; 2006:77-380.
26. Schmidt BL, Kearns G, Gordon N, Kaban LB. A financial analysis of maxillomandibular fixation versus rigid internal fixation for treatment of mandibular fractures. *J Oral Maxillofac Surg.* Nov 2000;58(11):1206-1210; discussion 1210-1.
27. Shetty V, Atchison K, Leathers R, Black E, Zigler C, Belin TR. Do the benefits of rigid internal fixation of mandible fractures justify the added costs? Results from a randomized controlled trial. *J Oral Maxillofac Surg.* Nov 2008;66(11):2203-2212.
28. Marshall MD, Buchbinder D. Pediatric mandibular injury. *Facial Plast Surg.* May 1999;7(2):195-203.

29. Valiati R, Ibrahim D, Abreu ME, Heitz C, de Oliveira RB, Pagnoncelli RM. The treatment of condylar fractures: To open or not to open? A critical review of this controversy. *Int J Med Sci.* 2008;5(6):313-318.
30. Baker S, Betts NJ. Mandibular angle fractures. *Oral and Maxillofacial Surgery Knowledge Update.* 1998;2:25.
31. Ellis E 3rd, Palmieri C, Throckmorton G. Further displacement of condylar process fractures after closed treatment. *J Oral Maxillofac Surg.* Nov 1999;57(11):1307-1316; discussion 1316-7.
32. Zallen RD, Curry JT. A study of antibiotic usage in compound mandibular fractures. *J Oral Surg.* Jun 1975;33(6):431-434.
33. James RB, Fredrickson C, Kent JN. Prospective study of mandibular fractures. *J Oral Surg.* Apr 1981;39(4):275-281.
34. Champy M, Loddé JP, Schmitt R, Jaeger JH, Muster D. Mandibular osteosynthesis by miniature screwed plates via a buccal approach. *J Maxillofac Surg.* Feb 1978;6(1):14-21.
35. Smith WP. Delayed miniplate osteosynthesis for mandibular fractures. *Br J Oral Maxillofac Surg.* Apr 1991;29(2):73-76.
36. Tuovinen V, Nørholt SE, Sindet-Pedersen S, Jensen J. A retrospective analysis of 279 patients with isolated mandibular fractures treated with titanium miniplates. *J Oral Maxillofac Surg.* Sep 1994;52(9):931-935; discussion 935-6.
37. Ellis E 3rd. Treatment methods for fractures of the mandibular angle. *J Craniomaxillofac Trauma.* Spring 1996;2(1):28-36.
38. Biller JA, Pletcher SD, Goldberg AN, Murr AH. Complications and the time to repair of mandible fractures. *Laryngoscope.* May 2005;115(5):769-772.
39. Webb LS, Makhijani S, Khanna M, Burstein MJ, Falk AN, Koumanis DJ. A comparison of outcomes between immediate and delayed repair of mandibular fractures. *Can J Plast Surg.* 2009;17(4):124-126.
40. Barker DA, Oo KK, Allak A, Park SS. Timing for repair of mandible fractures. *Laryngoscope.* Jun 2011;121(6):1160-1163.
41. Risdon F. Ankylosis of the temporomandibular joint. *J Am Dent Assoc.* 1934;21:1933.
42. Ellis 3rd E, Zide MF. Transfacial approaches to the mandible. Section 5 in: Ellis 3rd E, Zide MF. *Surgical Approaches to the Facial Skeleton.* 2nd ed. Philadelphia, PA: Lippincott Williams & Wilkins; 2005:151-189.

## CHAPTER 5: Mandibular Trauma

43. Dingman RO, Grabb WC. Surgical anatomy of the mandibular ramus of the facial nerve based on the dissection of 100 facial halves. *Plast Reconstr Surg Transplant Bull.* Mar 1962;29:266-272.
44. Khatri A, Kalra N. A conservative approach to pediatric mandibular fracture management: Outcome and advantages. *Indian J Dent Res.* Nov 2011;22(6):873-876.
45. Hinds EC. Correction of prognathism by subcondylar osteotomy. *J Oral Surg (Chic).* May 1958;16(3):209-214.
46. Hinds EC, Girotti WJ. Vertical subcondylar osteotomy: A reappraisal. *Oral Surg Oral Med Oral Pathol.* Aug 1967;24(2):164-170.
47. Kempers KG, Quinn PD, Silverstein K. Surgical approaches to mandibular condylar fractures: A review. *J Craniomaxillofac Trauma.* Winter 1999;5(4):25-30.
48. Thoma KH. Treatment of condylar fractures. *J Oral Surg (Chic).* Apr 1954;12(2):112-120.
49. Rowe NL. Surgery of the temporomandibular joint. *Proc R Soc Med.* Apr 1972;65(4):383-388.
50. Chen CT, Lai JP, Tung TC, Chen YR. Endoscopically assisted mandibular subcondylar fracture repair. *Plast Reconstr Surg.* Jan 1999;103(1):60-65.
51. Lee C, Forrest CR. Endoscopic facial fracture management: Techniques. Chapter 68 in: Mathes SJ. *Plastic Surgery.* Vol. 3. 2nd ed. Philadelphia, PA: Saunders Elsevier; 2006:463-4579.
52. Martin M, Lee C. Endoscopic mandibular condyle fracture repair. *Atlas Oral Maxillofac Surg Clin North Am.* Sep 2003;11(2):169-178.
53. Kellman RM, Cienfuegos R. Endoscopic approaches to subcondylar fractures of the mandible. *Facial Plast Surg.* Feb 2009;25(1):23-28.
54. Theriot BA, Van Sickels JE, Triplett RG, Nishioka GJ. Intraosseous wire fixation versus rigid osseous fixation of mandibular fractures: A preliminary report. *J Oral Maxillofac Surg.* Jul 1987;45(7):577-582.
55. Buchbinder D, Ellis E, Figari M, Sánchez G, Aniceto G, Shimozato K, eds. *CMF Surgery Reference.* AO Foundation. Accessed 7/12/12 at: <https://www2.aofoundation.org/wps/portal/surgery?showPage=diagnosis&bone=CMF&segment=Overview&showCMF=true>.

56. Ellis E 3rd. Management of fractures through the angle of the mandible. *Oral Maxillofac Surg Clin North Am.* May 2009;21(2):163-174.
57. Ellis 3rd E, Zide MF. Transoral approaches to the facial skeleton. Section 4 in: Ellis 3rd E, Zide MF. *Surgical Approaches to the Facial Skeleton*. 2nd ed. Philadelphia, PA: Lippincott Williams & Wilkins; 2005:109-150.
58. Abubaker AO, Rollert MK. Postoperative antibiotic prophylaxis in mandibular fractures: A preliminary randomized, double-blind, and placebo-controlled clinical study. *J Oral Maxillofac Surg.* Dec 2001;59(12):1415-1419.
59. Miles BA, Potter JK, Ellis E 3rd. The efficacy of postoperative antibiotic regimens in the open treatment of mandibular fractures: A prospective randomized trial. *J Oral Maxillofac Surg.* Apr 2006;64(4):576-582.
60. Neal DC, Wagner WF, Alpert B. Morbidity associated with teeth in the line of mandibular fractures. *J Oral Surg.* Nov 1978;36(11):859-862.
61. de Amaratunga NA. The effect of teeth in the line of mandibular fractures on healing. *J Oral Maxillofac Surg.* Apr 1987;45(4):312-314.
62. Shetty V, Freymiller E. Teeth in the line of fracture: A review. *J Oral Maxillofac Surg.* Dec 1989;47(12):1303-1306.
63. Moore GF, Olson TS, Yonkers AJ. Complications of mandibular fractures: A retrospective review of 100 fractures in 56 patients. *Nebr Med J.* Apr 1985;70(4):120-123.
64. Tanaka N, Uchide N, Suzuki K. Maxillofacial fractures in children. *J Craniomaxillofac Surg.* Oct 1993;21(7):289-293.
65. Martins C. Prognosis of mandibular fracture in pediatric population. *Int Congr Ser.* 2003;1254:473-475
66. Lida S, Matsuya T. Pediatric maxillofacial fractures: Their etiological characters and fracture patterns. *J Cranio Maxillofac Surg.* 2002;30:237-241.
67. MacLennan WD. Fractures of the mandible in children under the age of six years. *Br J Plast Surg.* 1956;9:125.

## CHAPTER 5: Mandibular Trauma

68. Rowe NL. Fractures of the jaws in children. *J Oral Surg.* Jul 1969;27(7):497-507.
69. Thoren H, Iizuka T, Hallikainen D. Different patterns of mandibular fractures in children. An analysis of 220 fractures in 157 patients. *J Craniomaxillofac Surg.* Oct 1992;20(7):292-296.
70. Kaban LB. Facial trauma I. Midface fracture. In: Kaban LB, ed. *Pediatric Oral and Maxillofacial Surgery*. 2nd ed. Philadelphia, PA: WB Saunders Co.; 1990:210-212.
71. Marshall MD, Buchbinder D. Pediatric mandibular injury. *Facial Plast Surg.* May 1999;7(2):195-203.
72. Ferreira PC, Amarante JM, Silva PN, et al. Retrospective study of 1251 maxillofacial fractures in children and adolescents. *Plast Reconstr Surg.* May 2005;115(6):1500-1508.
73. Güven O, Keskin A. Remodelling following condylar fractures in children. *J Craniomaxillofac Surg.* Aug 2001;29(4):232-237.
74. Kaban LB, Mulliken JB, Murray JE. Facial fractures in children: An analysis of 122 fractures in 109 patients. *Plast Reconstr Surg.* Jan 1977;59(1):15-20.
75. Posnick JC, Wells M, Pron GE. Pediatric facial fractures: Evolving patterns of treatment. *J Oral Maxillofac Surg.* Aug 1993;51(8):836-844; discussion 844-845.
76. Myall RW. Management of mandibular fractures in children. *Oral Maxillofac Surg Clin North Am.* May 2009;21(2):197-201, vi.
77. Cole P, Kaufman Y, Izaddoost S, Hatfeg DA, Hollier L. Principles of pediatric mandibular fracture management. *Plast Reconstr Surg.* Mar 2009;123(3):1022-1024.
78. Kushner GM, Tiwana PS. Fractures of the growing mandible. *Atlas Oral Maxillofac Surg Clin North Am.* Mar 2009;17(1):81-91.
79. Goth S, Sawatari Y, Peleg M. Management of pediatric mandible fractures. *J Craniofac Surg.* Jan 2012;23(1):47-56.
80. Hegab A. Management of mandibular fractures in children with a split acrylic splint: A case series. *Br J Oral Maxillofac Surg.* Dec 5 2011.



81. Eppley BL. Use of resorbable plates and screws in pediatric facial fractures. *J Oral Maxillofac Surg.* Mar 2005;63(3):385-391.
82. Poore MC, Penna KJ. The use of resorbable hardware for fixation of pediatric mandible fracture. Case report. *N Y State Dent J.* Jun-Jul 2008;74(4):58-61.

## Chapter 6: Temporal Bone Fractures

Mitchell Jay Ramsey, MD, Lt Colonel, MC, USA

Although temporal bone fractures are relatively uncommon, they present many complex diagnostic and therapeutic challenges. A large volume of force is required to fracture the temporal bone. These fractures rarely occur in isolation. According to Nosan, 5 percent of patients with significant head trauma will also sustain temporal bone fractures. Most often, treatment of temporal bone trauma can be delayed, after life-threatening injuries are treated.

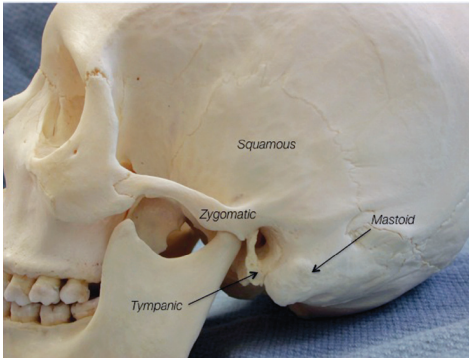
The evaluation of the temporal bone in a patient with multiple traumatic injuries can often be incomplete or overlooked, delaying diagnoses and management. A quick otoscopy examination is an excellent screening exam that usually indicates evidence of a temporal bone injury and can guide additional diagnostic testing. In an awake patient, evaluation of the facial nerve is also critically important. Establishing baseline facial nerve function can aid in the prognosis and guide the decision to explore, decompress, or repair the facial nerve.

The management of temporal bone fractures is generally aimed at restoring functional deficits, rather than reducing and fixating bone fragments. Common injuries requiring surgical management include hearing loss, facial nerve dysfunction, and cerebrospinal fluid (CSF) leaks. The temporal complex is a non-weight-bearing region. Thus, displaced fractures, in and of themselves, rarely have any cosmetic sequelae. However, the fractures can involve the 7th cranial nerve and can cause devastating cosmetic and functional injuries. The extent of the injuries, based on physical examination and imaging studies, will determine the urgency and type(s) of surgical interventions required.

The mechanism of trauma can be divided into blunt trauma, with motor vehicle accidents accounting for the majority, and penetrating trauma, which is far less common, but can result in a much more serious injury, depending on the characteristics of the projectile. Penetrating temporal bone injury is uncommon and may result from a variety of projectiles. High-velocity gunshot wounds can result in massive vascular and neurologic injury and may require urgent intervention.

## I. Anatomic Structures of the Temporal Bone

The anatomy of the temporal bone is quite complex, as several critical neurovascular structures are associated with the petrous region. Furthermore, the temporal bone is a collection of bones with variable characteristics resulting from bone density, sutures, aerated spaces, and foramen. The temporal bone articulates with the occipital, parietal, sphenoid, and zygomatic bones and contributes to the middle cranial fossa, posterior cranial fossa, and skull base (Figure 6.1). Sequelae of temporal bone fractures are primarily related to the structures housed in the temporal bone, which include the cochlea, vestibular system, ossicles, tympanic membrane (TM), facial nerve, petrous carotid artery, sigmoid sinus, and jugular bulb. Although the 9th, 10th, and 11th cranial nerves have a close association with the temporal bone and exit the jugular foramen, they are rarely involved in temporal bone fractures.



**Figure 6.1**

Lateral view of the left temporal showing the squamous, mastoid, and tympanic portions in relation to surrounding structures. The petrous portion is not visible from this view.

### A. COMPONENTS AND IMPORTANT RELATIONSHIPS OF THE TEMPORAL BONE

The temporal bone is a complex bone composed of four portions, each with important relationships. Relevant associations and structures housed in the temporal bone appear in bold in Table 6.1.

## CHAPTER 6: Temporal Bone Fractures

**Table 6.1. Components of the Temporal Bone and Important Relationships**

Bone Components	Important Relationships
Squamous	Lies adjacent to the temporal lobe comprising the lateral wall of the <b>middle cranial fossa</b> . Extends anteriorly, forming the linea temporalis and the posterior aspect of the zygomatic arch.
Tympanic	An incomplete ring of bone that comprises the majority of the <b>external auditory canal</b> and frequently is involved in the fracture path.
Mastoid	Comprises the aerated portion of the mastoid and middle ear and houses portions of the <b>fallopian canal</b> , <b>sigmoid sinus</b> , and <b>ossicles</b> . It is adjacent to the <b>middle cranial fossa</b> (superior) and <b>posterior cranial fossa</b> (posterior), and may be a pathway for <b>CSF leak</b> .
Petrous	Comprises the medial aspect and houses several critical structures, including the <b>otic capsule</b> containing the cochlea, vestibule, semicircular canals (inner ear labyrinth); the <b>internal auditory canal</b> containing portions of the 7th and 8th cranial nerves; several portions of the seventh cranial nerve, including the <b>perigeniculate region of the facial nerve</b> , located between the labyrinthine and tympanic segments, which is the most common location of facial nerve injury; and <b>petrous carotid artery</b> .

### B. FACIAL NERVE CHARACTERISTICS

The facial nerve innervates the muscles of facial expression. Microscopically the nerve consists of myelinated axons surrounded by endoneurium. The axons are gathered into groups of fascicles, which are surrounded by perineurium. The epineurium surrounds the fascicles and condenses into an external nerve sheath.

The facial nerve exits the pontomedullary junction and traverses the cerebellopontine cistern, entering the internal auditory canal (IAC) where it takes a superior and anterior position. The facial nerve exits the IAC, entering the meatal foramen, which is the narrowest portion of the fallopian canal. The labyrinthine portion constitutes the portion of the nerve from the meatal foramen to the geniculate ganglion. The tympanic segment of the facial nerve extends from the geniculate to the second genu, near the horizontal semicircular canal. The mastoid segment of the facial nerve extends from the second genu to the stylomastoid foramen.

## II. Indications of Temporal Bone Injury

In general, the subjective symptoms and objective signs of temporal bone injuries will reflect the specific structures that are injured.

### A. SUBJECTIVE SYMPTOMS

- Hearing loss.
- Vertigo/imbalance.
- Tinnitus.
- Autophony (hearing oneself speak, or other internal noises, more prominently).
- Aural fullness/pressure.
- Facial weakness.
- Drainage from ear.

### B. OBJECTIVE SIGNS

#### 1. Hearing Loss

Hearing loss is one of the most common findings associated with temporal bone fractures. Hearing loss can result from damage to the inner ear or middle ear, or a combination may be categorized as sensorineural hearing loss (SNHL), a conductive hearing loss (CHL), or a mixed loss, depending on the location of the fracture as well as the intensity of the impact. Most fractures lead to a CHL, resulting from injury of the TM, ossicular subluxation or discontinuity, hemotympanum, or any combination of these. Hearing loss can be evaluated at the bedside with a tuning fork, which is described in section IV.C of this chapter.

#### 2. Hemotympanum

Injury to the temporal bone and mucosa of the middle ear and mastoid frequently leads to accumulation of visible blood or serosanguinous fluid in the middle ear space. The volume of blood or fluid in the middle ear reflects the extent of the injury and function of the Eustachian tube. If the injury is severe enough or drainage through the Eustachian tube is impaired, the entire middle ear may be filled with blood, resulting in dark discoloration of the TM.

#### 3. Otorrhea

When a TM perforation is present, fluid that accumulates in the middle ear space may pass through the perforation and manifest as otorrhea. The fluid may be hemorrhage, exudates from trauma, CSF fluid from a leak, or a combination of all of these. CSF may drain down the

## CHAPTER 6: Temporal Bone Fractures

Eustachian tube and manifest as rhinorrhea. This can occur in the presence or absence of a TM injury.

### 4. Imbalance

Although balance and vestibular function are difficult systems to evaluate acutely at the bedside, injury to the otic capsule can result in severe vestibular damage, which may produce nystagmus. Peripheral nystagmus is typically a jerk nystagmus, usually horizontal or rotatory, and is suppressed with visual fixation. Another useful test is the fistula test, performed by applying positive or negative pressure with pneumotoscopy. Increasing nystagmus with pressure is a positive fistula test and can indicate a perilymphatic or inner ear fistula.

### 5. Facial Nerve Dysfunction (Paralysis or Paresis)

Early assessment of the facial nerve is very important, and baseline function should be established as soon as possible. Determining the presence of a facial nerve injury in a cooperative patient is generally straightforward. Comparing the function bilaterally reveals any subtle asymmetry. Assessment of each distal branch should be performed to determine if paresis or paralysis is present. Attention to eye closure is also important, as incomplete eye closure requires careful management to avoid exposure keratitis.

Often the facial nerve cannot be evaluated acutely because patients are uncooperative, unconscious, or sedated. In an uncooperative patient, one method of stimulating facial movement is to induce pain. This can be accomplished by a sternal rub, or by placing a Q-tip or instrument in the nose and stimulating the septum. Often this will generate a grimace, which can allow comparison of the right and left facial functions.

### 6. Auricular Ecchymosis, Lacerations, and Hematomas

The soft tissue exam may demonstrate bruising, lacerations, or hematomas and can suggest temporal bone injury.

## III. Classification of Temporal Bone Fractures

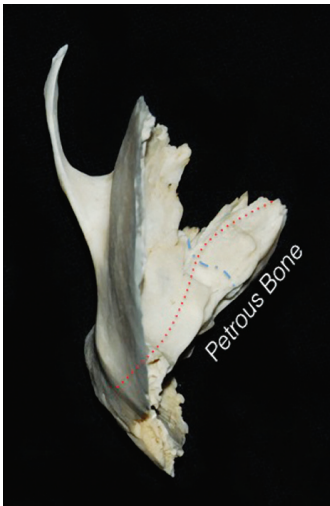Several classification systems have been proposed, each with advantages and disadvantages. They are generally complimentary and help clarify the anatomical involvement and functional sequelae of a fracture. The injury can be best identified on imaging studies.

### A. LONGITUDINAL VERSUS TRANSVERSE CLASSIFICATION

This classification system was based on the anatomic pathway of the fracture. According to Cannon, it used the long axis of the petrous apex as a reference and classified fractures as longitudinal or transverse.

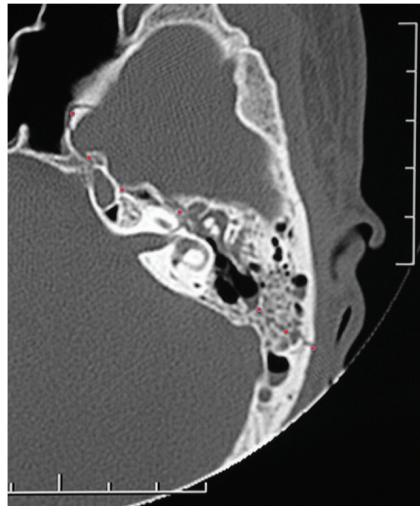
## 1. Longitudinal Injuries

Longitudinal injuries are much more common and account for 70–90 percent of fractures. They follow a course through the external auditory canal (EAC) and TM, progressing along the axis of the petrous apex, following the path of least resistance, which often involves aerated regions, foramina, and suture lines. Longitudinal injuries classically result from a blow to the temporal parietal region. They are frequently associated with a CHL, and may have an associated facial nerve injury in the perigeniculate region. Figure 6.2 illustrates the path of a longitudinal and transverse fracture relative to the long axis of the petrous bone. Figure 6.3 represents the radiologic appearance of a longitudinal fracture. This patient sustained a fracture in a motor vehicle accident and had complete facial paralysis, requiring decompression.



**Figure 6.2**

Superior view of the left temporal bone in isolation. This image illustrates the long axis of the temporal bone and the course of longitudinal (red dashed line) and transverse (blue-dashed line) patterns of fractures. The petrous portion of the temporal bone is seen best in this view. It houses the otic capsule, internal auditory canal, petrous carotid, and portions of the facial nerve and forms the petrous apex.



**Figure 6.3**

Axial view of the left temporal bone, with longitudinal fracture (red dotted line) extending through the petrous apex into the sphenoid.

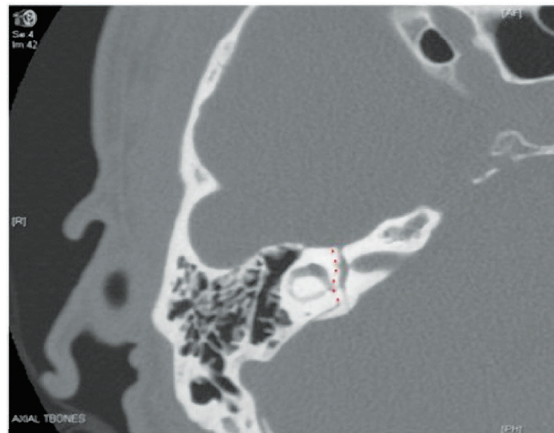
## CHAPTER 6: Temporal Bone Fractures

### 2. Transverse Fractures

Transverse fractures cross the petrous ridge and have a higher incidence of otic capsule involvement. These fractures require more energy and classically result from a blow to the occipital region. Transverse fractures are more often associated with inner ear injury, resulting in SNHL, and have a higher incidence of facial nerve injury. Figure 6.4 demonstrates the radiologic appearance of a transverse fracture. This patient sustained his fracture in a motor vehicle accident and had normal facial nerve function but lost all hearing. Although this system is simple and easy to understand, many fractures have mixed patterns, limiting this system's utility.

#### Figure 6.4

Axial view of the right temporal bone with a transverse fracture (red dashed line) crossing the petrous bone and involving the lateral aspect of the IAC.



### B. OTIC CAPSULE-SPARING VERSUS OTIC CAPSULE-INVOLVING CLASSIFICATION

This classification system is based on the presence or absence of involvement of the otic capsule. This system was introduced to emphasize the functional sequelae of the fracture. Results from the two series proposing this classification scheme indicate that 2.5–5.8 percent of fractures involve the otic capsule. Figure 6.3 illustrates an otic capsule-sparing fracture, while figure 6.4 illustrates an otic capsule-involving fracture.



## **IV. Diagnostic Evaluations**

### **A. FULL-BODY TRAUMA ASSESSMENT**

Most patients with temporal bone trauma will be evaluated by the trauma team, which will stabilize and clear the patient from more serious injuries before the full evaluation and decision-making process on the temporal bone trauma takes place. This includes the full-body trauma assessment, particularly of the airway, breathing, circulation, and neurological status, as well as the remainder of the body assessment. During the secondary survey, the cervical spine should be evaluated and cleared if possible. If not, the patient is assumed to have a cervical spine injury until further definitive evaluation is performed.

It is helpful and highly educational for the otolaryngology resident to be present for this total-body trauma assessment, as positive findings will impact the evaluation and treatment of temporal bone fractures. Additionally, after the primary and secondary assessments, the otolaryngology resident will be able to focus specifically on a detailed head and neck examination.

### **B. HEAD AND NECK EXAMINATION**

Since isolated temporal bone fractures are not common, the entire facial skeleton must be fully evaluated during the head and neck examination. Particularly pertinent to temporal bone injuries, the head and neck examination will obviously assess any otologic damage, to include facial nerve function, hearing deficits, bedside vestibular function testing, neurological status, and in particular facial nerve function and otoscopic examination. Postauricular ecchymosis (Battle's sign) can be an indicator of a basilar skull fracture. Soft tissue should be inspected for lacerations, which should be cleaned and reapproximated, and auricular hematoma, which should be drained and treated with a bolster dressing. Otoloscopic examination may reveal a step-off in the canal where the fracture is, blebs and ecchymosis, or a perforation.

### **C. HEARING EVALUATION**

Bedside evaluation with a 512-Hertz tuning fork is a reliable method to screen for a CHL or SNHL.

#### **1. Weber Exam**

The Weber exam is performed by activating the tuning fork and placing it firmly on the forehead or another portion of the skull. The patient is asked if the stimulus is louder on the right or left or similar on both

## CHAPTER 6: Temporal Bone Fractures

sides. When a stimulus is louder on one side, the Weber is said to lateralize to that side. The Weber lateralizes towards an ear with a CHL or away from one with SNHL.

### 2. Rinne Testing

Rinne testing is a method that compares air conduction to bone conduction. The tuning fork is activated and held near the meatus, conducting sound through air. Then the fork is applied firmly to the mastoid region, conducting sound through bone. This is performed separately for the right and left ears. The patient is asked to indicate if air conduction (tuning fork near meatus) or bone conduction (tuning fork applied to mastoid) is louder. A patient with a moderate CHL will indicate that bone conduction is stronger than air on the affected side. A patient with a normal-hearing ear will indicate the signal from air conduction is greater than bone conduction (termed a positive Rinne).

### 3. Combined Weber, Rinne, and Audiogram Testing

A CHL is indicated by a combination of a Weber test that lateralizes to the affected ear and a negative Rinne. If a tuning fork is not available and the patient is cooperative, ask the patient to hum strongly for several seconds and identify in which ear the sound seems more intense. In a patient with a CHL, the hum will sound louder on the involved side. If a CHL is identified, an audiogram can be obtained when convenient. The audiogram should be repeated prior to ossiculoplasty or tympanoplasty surgery to determine residual hearing loss.

Tuning fork findings in a patient with SNHL can vary widely. A Weber that lateralizes away from the affected ear suggests SNHL. Unless there is profound loss, the Rinne is usually positive. A fracture involving the otic capsule generally results in a profound SNHL. This may be manifested by severe tinnitus and vestibular signs. An audiogram should be obtained as soon as possible. If a mixed hearing loss or SNHL is identified, steroids should be considered.

## D. VESTIBULAR EVALUATION

Imbalance or vertigo may be present in patients with temporal bone trauma resulting from inner ear injury or neurologic injury. The otic capsule is very dense, and fractures involving the otic capsule are

uncommon. Neurologic injuries include concussion and injuries to the brainstem and vestibular/cerebellar pathways, and may co-exist with inner ear injuries. The evaluation of a patient with dizziness should include a detailed neurologic evaluation and a bedside vestibular evaluation. Further testing with audiogram and vestibular function tests is useful, but are usually obtained when the patient can be tested in the office setting with appropriate equipment

In trauma patients, a cervical spine injury should be ruled out before performing the vestibular evaluation. Bedside assessment of the peripheral vestibular system should include evaluation for spontaneous or gaze-evoked nystagmus, gait abnormalities, positive fistula test, Dix-Hallpike test to evaluate for benign paroxysmal positional vertigo (BPPV), head thrust looking for refixation saccade, and assessment for post-head-shaking nystagmus. A fracture of the otic capsule generally results in a severe vestibular injury, but injuries can occur in the absence of a fracture. The most common vestibular abnormalities include BPPV and evidence of vestibular hypofunction.

#### **E. FACIAL NERVE EVALUATION**

The intratemporal facial nerve is subject to injuries from compression, shearing, traction, or disruption. The nerve travels through a tunnel consisting of the IAC and facial (fallopian) canal. The course of the nerve is irregular, and has been divided into the IAC, labyrinthine, geniculate, tympanic, and mastoid segments. The narrowest portion of the canal is the meatal foramen, through which the labyrinthine portion passes, and is thought to be a frequent site of compression injury. Furthermore, the nerve is tethered at various points. The most important point is the perigeniculate region, where the nerve is tethered by the genu and the greater superficial petrosal branch. This complex anatomy and narrow bony pathway make the facial nerve highly susceptible to injury in temporal bone fractures.

## CHAPTER 6: Temporal Bone Fractures

### 1. Sunderland Classification of Nerve Injury

As shown in Table 6.2, facial nerve injuries range from mild (first degree) to severe (fifth degree) injuries, according to the Sunderland classification.

**Table 6.2. Sunderland Classification of Nerve Injury**

Degree of Injury	Injury Terminology	Effect of Injury	Recovery Potential
First	Neuropraxia	Results in a conduction blockade in an otherwise anatomically intact nerve.	Lesions tend to recover completely.
Second	Axonotmesis	Results in axonal injury, but the endoneurium is intact.	Injuries have good recovery.
Third	Neurotmesis	Results in axon and endoneurium injury, but the perineurium is preserved.	Aberrant regeneration occurs and can leave patients with some weakness and synkinesis.
Fourth	Neurotmesis	Transects the entire nerve trunk, but the epineurial sheath remains intact.	Some recovery is possible, but will be incomplete.
Fifth	Neurotmesis	Completely transects the entire nerve trunk and epineurium.	Nerve graft interposition, cross-facial nerve grafting, or partial hypoglossal nerve reinnervation may be considered.

### 2. Evaluating Facial Paralysis and Paresis

Facial nerve injury results in asymmetry of facial movement. Temporal bone fractures involve the intratemporal nerve rather than the peripheral branches, producing generalized hemifacial weakness. Asking patients to raise their eyebrows, close their eyes, smile, snarl, or grimace allows comparison of volitional movement that will highlight asymmetry. Marked edema limits facial expression and can give the impression of reduced facial movement. Furthermore, highly expressive movement on the normal side will cause some passive movement on the paralyzed side near the midline.

A patient with paralysis may appear to have limited function that is actually passive movement resulting from the uninvolved side. When

this is suspected, the examiner should physically restrict movement on normal side by pressing on the facial soft tissue and reassess for any movement on the injured side. Different grading scales are available, but the important factor is to assess if there is paralysis (no movement) or paresis (weakness) of facial motor function. Sometimes terms like complete paralysis (indicating no movement) and incomplete paralysis (meaning weakness or paresis) are used.

Although temporal fractures produce hemifacial involvement, it is best to record function for all five distal regions (forehead, eye closure, midface, mouth, and neck), as there may be some variation in the degree of dysfunction. Any patient with partial residual motor function is likely to have a good long-term outcome with conservative management.

A partial facial nerve injury can progress to a complete paralysis over the course of a few days. Increased swelling leads to compression of the nerve in the fallopian canal. Patients who present with a paresis rather than a paralysis, who later progress to a complete paralysis, generally have a good prognosis for spontaneous recovery.

Patients who present immediately with a complete facial paralysis generally fall into a poor prognostic category. These patients typically have much more severe facial nerve injuries and are more likely to benefit from facial nerve exploration and repair. This is why early clinical evaluation to establish baseline facial nerve function is so important.

Sometimes a patient's condition prevents initial facial nerve evaluation. A diagnostic challenge arises when this occurs and the patient is later found to have a complete facial paralysis. In this scenario, the clinician does not know if an initial paresis existed that progressed to paralysis, or if the patient had paralysis immediately after the injury. The management is determined by the electrophysiologic testing and guided by the radiologic interpretation and clinical features of the injury.

### **3. Evaluation with Electromyography and Electroneuronography**

Electrophysiologic testing can provide prognostic information in a patient with complete facial paralysis. However, if the patient retains some movement, this testing is of very little value. Several other tests are available. The two most commonly used tests are electromyography (EMG) and electroneuronography (ENOG). These tests help differentiate a neuropraxic injury from a neural degenerative injury and assess the proportion of degenerated axons.

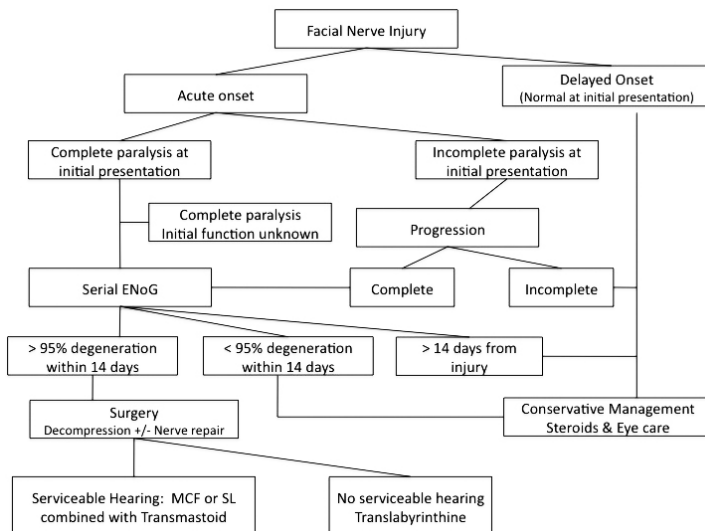
## CHAPTER 6: Temporal Bone Fractures

EMG is a volitional test performed by intramuscular recording electrodes to assess for voluntary action potentials, which correlate with a good prognosis. The EMG patterns can also include fibrillation potentials, indicating degeneration and polyphasic potentials, which in turn indicate recovery. ENOG is an evoked test that compares the compound action potential of the two sides of the face to determine the percentage of degeneration on the affected side. Wallerian degeneration, progressive nerve degeneration distal to the site of injury, occurs over 3–5 days post-injury. Early testing may produce erroneous results if Wallerian degeneration is not complete. This is why serial electrophysiologic testing is performed.

Controversy exists regarding the indications for facial nerve exploration and decompression. Data regarding prognostic ENOG use in traumatic facial nerve injury are limited. Data on ENOG use, steroids, and decompression in Bell's palsy are more extensive, and traumatic facial nerve management principles have been partly extrapolated from the data. It is generally accepted that patients with >95 percent severe degeneration have a poor prognosis and should be considered for surgery. Figure 6.5 presents an algorithm for evaluating and managing patients with facial nerve injury.

**Figure 6.5**

Algorithm for evaluating and managing patients with facial nerve injury.



## F. EVALUATION OF CEREBROSPINAL FLUID LEAKS

CSF leaks result from disruption of the meninges in the IAC, temporal region, or posterior fossa. According to Brodie and Thompson, they occur in 17 percent of temporal bone fractures. Diagnosing and treating a CSF leak is important to minimize the risk of meningitis. A CSF leak can result in middle ear effusion, rhinorrhea, or otorrhea, depending on the integrity of the TM and Eustachian tube.

The large majority of CSF leaks heal spontaneously with conservative measures. A persistent CSF leak places the patient at risk for meningitis. Otic capsule-disrupting fractures have a higher incidence of CSF leaks, which result from injury in the IAC or posterior fossa. Otic capsule-sparing fractures can also be associated with CSF leaks, which result from disruption of the dura in the region of the tegmen tympani or tegmen mastoidea.

### 1. Diagnostic Tests

Diagnostic tests can help differentiate CSF otorrhea or rhinorrhea.

- *Fluid samples*—Copious clear fluid is certainly suggestive of a CSF leak, but often the presentation is not obvious. A sample of fluid can be obtained and tested. CSF has a higher glucose content and lower protein and potassium content than mucosal secretions.
- *Beta-2 transferrin*—This is another test specific for CSF, but requires a discrete volume for analysis.
- *Intrathecal contrast with CT imaging*—Intrathecal contrast can be combined with high-resolution computed tomography (CT) imaging to assess for the presence of contrast in the mastoid.
- *Intrathecal fluorescein*—Intrathecal fluorescein can also be administered in a dilute manner to stain the CSF. Otorrhea or rhinorrhea can be assessed for gross discoloration or collected on a pledget and evaluated with a woods lamp to detect fluorescein staining.

## G. IMAGING STUDIES

Imaging studies are indicated in patients with temporal bone injuries, and CT is the modality of choice. Frequently, the trauma team has performed a head CT, but it is important to assess the temporal bone and skull base with a dedicated fine-cut CT reformatted in various planes. CT windowed for bone allows identification of the fracture path and involved structures and allows for fracture classification. A detailed review of the CT should be performed to assess for involvement of the facial nerve, carotid artery, intracranial injury, displacement of the ossicles, EAC involvement, and potential for epithelial entrapment.

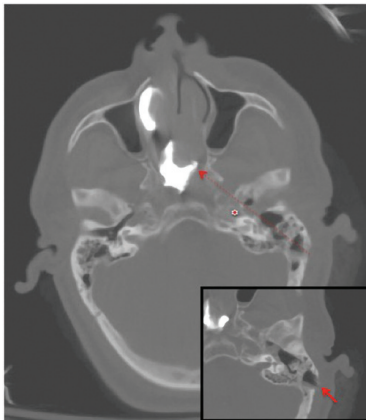
## CHAPTER 6: Temporal Bone Fractures

Figures 6.4 and 6.5 are examples of otic capsule-sparing and -involving fractures. These images also demonstrate the longitudinal and transverse fracture patterns.

Occasionally, CT demonstrates temporal bone fractures that involve the carotid canal. An asymptomatic patient with a fracture involving the carotid canal does not warrant additional studies. However, a patient with transient or persistent neurologic deficits should have additional vascular studies, such as CT angiography.

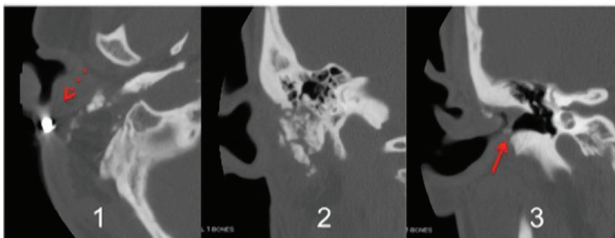
Penetrating temporal bone injuries are usually more complex, with greater involvement of regional structures. Penetrating injuries have a greater incidence of facial nerve, vascular, and intracranial injury.

Figures 6.6 and 6.7 demonstrate, respectively, the radiologic



**Figure 6.6**

Axial view demonstrating the path of a gunshot wound through the left temporal bone (red dashed line) and the proximity of the projectile path to the carotid artery (red star). Fragments from the projectile are seen in the nasopharynx and palate. This patient sustained facial nerve paralysis, but remarkably his carotid artery was uninvolved. The inset image is from a slightly more superior level, and shows the entry point in the mastoid bone (red solid arrow).



**Figure 6.7**

Composite of images from penetrating shrapnel injury of the right temporal bone. Panel 1 is an axial view demonstrating a residual fragment of shrapnel (red dashed arrow) and injury to the mastoid tip. Panel 2 is a coronal view of the highly comminuted mastoid fracture. Panel 3 is a coronal view through the EAC demonstrating soft tissue stenosis (red solid arrow). This patient developed late complications of entrapment cholesteatoma and EAC stenosis. Although the fracture did not involve the otic capsule, the patient developed a profound SNHL.



appearances of penetrating injuries of the temporal bone from a gunshot wound and shrapnel injury.

Plain radiographs of the temporal bone are rarely helpful and have been replaced by high-resolution CT imaging.

## **V. Surgical Management**

### **A. INDICATIONS FOR SURGERY**

Indications for surgery include:

- Persistent conductive hearing loss.
- Persistent tympanic membrane perforation.
- Severe facial nerve injury.
- CSF otorrhea or rhinorrhea due to a fracture.
- Severe comminuted injury requiring debridement or risking entrapment cholesteatoma.
- Injury of the external auditory canal leading to stenosis.

### **B. TIMING OF SURGICAL PROCEDURES**

Surgery for temporal bone fractures is performed to restore function or manage a complication. The temporal bone is a non-weight-bearing structure; therefore, reduction and fixation principles relevant to weight-bearing structures do not apply. Furthermore, temporal bone fractures rarely result in significant cosmetic deficits, unless the facial nerve is involved. Fortunately, with complex fractures, there is usually sufficient time before repair to adequately assess the patient's injuries, initiate intravenous antibiotic therapy, observe the patient for neurologic signs, and properly prepare the operating room.

### **C. SURGICAL EXPOSURE OPTIONS**

#### **1. General Requirements for Surgery of the Temporal Bone**

General requirements for surgery of the temporal bone include availability of:

- Operating microscope.
- Drill system.
- Appropriate otologic micro instruments.
- Facial nerve monitor.

#### **2. Primary Surgical Objectives and Indications in Temporal Bone Fractures**

The primary objectives of surgical reconstruction include:

- Repair ossicular injuries resulting in conductive hearing loss.
- Repair injuries of the tympanic membrane.
- Decompress or repair injuries of the facial nerve.

## CHAPTER 6: Temporal Bone Fractures

- Repair or contain CSF leak.
- Re-establish the patency and diameter of the external auditory canal.
- Remove entrapped fragments of skin to prevent future cholesteatoma.
- Repair any lacerations or drain auricular hematoma.

### 3. Surgical Approaches for Accessing Injuries

There are multiple surgical approaches for accessing the middle ear, TM, areas of the mastoid, and various regions of the facial nerve. Frequently more than one approach is required, and selection depends on the extent of the injuries and the goals of treatment. Surgery is frequently indicated for the following reasons: conductive hearing loss (resulting from ossicular injury or TM injury), residual TM perforation, severe facial nerve injury, CSF leak, concern for entrapment of skin and debris, or injury of the EAC resulting in stenosis. Most approaches include a combination of a soft tissue and osseous access.

#### **a. Transcanal Approach**

A transcanal approach provides access to the TM, middle ear space, and limited exposure of the EAC. This approach is used most commonly to repair ossicular abnormalities resulting in CHL. It is also very useful for TM perforations repaired through a medial graft technique. This approach is direct and simple, but exposure can be limited. Surgery is performed through a speculum placed into the EAC and allows for elevation of a tympanomeatal flap to access the mesotympanum. This approach is not used for facial nerve decompression or repair of a CSF leak.

#### **b. Postauricular Approach**

A postauricular approach provides access to the EAC, TM, and middle ear, and is frequently combined with an osseous approach (i.e., canal-wall-up mastoidectomy) for access to the mastoid. This approach provides greater exposure than a transcanal, and requires a postauricular incision. It can be used for the same indications as the transcanal approach when greater access is required. It can also be used to access the mastoid and deeper structures within the temporal bone for extended procedures, such as a transmastoid, supralabyrinthine and translabyrinthine approach to the facial nerve.

If a canal plasty is required for access or to reconstruct an injured EAC, this is the preferred soft tissue approach. The operation includes incisions in the EAC and postauricular region, allowing the auricle to be

freed from the mastoid bone and mobilized anteriorly. This is the basic soft tissue approach for the majority of osseous approaches, with the exception of a middle cranial fossa approach.

### ***c. Mastoidectomy Approach***

Mastoidectomy is an osseous approach with several variations, but the basic approach allows access to several spaces, including the mastoid air cell system, antrum, epitympanum, and mesotympanum through the facial recess. Mastoidectomy also allows for extended access to various structures housed in the temporal bone, such as the semicircular canal, IAC, and portions of the facial nerve. It is indicated in cases requiring debridement of entrapped skin, facial nerve decompression, CSF and leak exploration/repair, and when maximal access to the middle ear is required. The portions of the facial nerve accessible through a basic mastoidectomy approach include the majority of the tympanic and all of the mastoid portions.

### ***d. Combined Middle Cranial Fossa and Transmastoid Approach***

A combined middle cranial fossa and transmastoid approach is used when facial nerve decompression and/or repair is required. The middle cranial fossa approach provides access to the IAC, labyrinthine, and geniculate portions of the facial nerve. The procedure involves a craniotomy to remove a window of bone in the squamous temporal bone and extradural elevation of the temporal lobe. Bone is removed from the superior petrous ridge to access relevant structures. This is a technically challenging procedure that is combined with a mastoidectomy for access to the tympanic and mastoid segments of the facial nerve. In a patient with an intact ossicular chain, the incus will have to be removed to allow access to the tympanic portion of the facial nerve. Many surgeons advocate decompression of the labyrinthine facial nerve, even when the primary injury appears distal. Evidence suggests there is retrograde degeneration of the nerve, and the labyrinthine portion is the narrowest portion of the fallopian canal.

### ***e. Translabyrinthine Approach***

A translabyrinthine approach is used for decompression of the facial nerve when no serviceable hearing is present. When hearing is lost or not serviceable, the translabyrinthine approach provides excellent access to all portions of the facial nerve. The advantages of this approach over the combined middle cranial fossa and transmastoid approach include a more direct approach, less brain retraction, and easier access.

## CHAPTER 6: Temporal Bone Fractures

### ***f. Supralabyrinthine Approach***

A supralabyrinthine approach is used for decompression of the facial nerve when serviceable hearing is present along with a well-aerated mastoid. The technique involves a mastoidectomy, which allows access to the mastoid and tympanic portions of the facial nerve, and more extensive dissection in the epitympanum. Bone is removed to identify the superior semicircular canal and access the labyrinthine and geniculate portions of the facial nerve. This approach allows access to the labyrinthine portion of the facial nerve and may allow for decompression. However, if nerve repair is indicated in the IAC or labyrinthine segment, this approach does not provide sufficient exposure.

## **D. RECONSTRUCTIVE OPTIONS**

The repair of temporal bone injuries usually involves an attempt at restoring functional deficits associated with the injury, rather than classic reduction of displaced bones.

### **1. Tympanic Membrane Repair**

Multiple techniques exist to repair the TM. Most of them involve using some type of autologous tissue as the material to repair a perforation. By far the most common material used is temporalis fascia. Two general techniques that constitute the majority of techniques are medial graft tympanoplasty and lateral graft tympanoplasty.

#### ***a. Medial Graft Tympanoplasty***

In a medial graft technique, the rim of the perforation is freshened, and the native TM is elevated by making some incisions in the medial EAC skin and elevating the skin and annulus together as a tympanomeatal flap. The medial graft technique can be performed through either a transcanal or a postauricular approach. Fascia is harvested and prepared and placed medial to the native TM, and is supported by some type of material. Gelfoam<sup>®</sup>, a dissolvable preparation of protein, is frequently used. The Gelfoam<sup>®</sup> supports the graft, keeping it approximated to the native TM until the two heal together or the native TM grows across the fascia, which serves as a biologic scaffold.

#### ***b. Lateral Graft Tympanoplasty***

The lateral graft technique is another successful technique that is used for larger perforations, total perforations, or anterior perforations.

### **2. Ossicular Reconstruction**

Fractures of the temporal bone may result in subluxation or dislocation of the ossicles, which impede sound transmission and result in a CHL.

After the patient has recovered from associated injuries, an elective middle ear exploration is performed to identify the cause of CHL, which is repaired through an ossiculoplasty.

Ossiculoplasty can be performed in a variety of ways. Because injuries of the ossicles rarely can be fixed by open reduction and fixation of the native ossicles, other techniques have been developed using autologous or synthetic prosthesis to restore a functional ossicular chain. This restoration requires coupling the TM to the stapes footplate. Depending on the ossicular injury, one of five types of tympanoplasty (an operation designed to restore hearing) is performed. Common materials for synthetic ossicular prosthesis include titanium, hydroxy appetite, and plastics, or some combination of these materials.

### **3. Facial Nerve Repair**

Surgical treatment of the facial nerve involves surgical exploration and decompression. The majority of explorations reveal an intact nerve, with focal compression injury resulting from bone fragments or ossicles that have been displaced into the nerve. Explorations will occasionally reveal severe injury of a nerve segment or disruption of the nerve.

Options for repair include rerouting the nerve or interposition grafting. Because rerouting is technically challenging, interposition grafting is often the easiest and best option. Typically, the defects are short and the great auricular nerve serves as a good option. The interposition graft is laid into the fallopian canal that has been decompressed, and a microvascular anastomosis can be performed to augment the approximation.

Regardless of the repair technique, a tensionless closure is key. Rarely is the proximal portion of the nerve unavailable. So such options as 12-7 interposition are generally not necessary.

## **VI. Prevention and Management of Complications**

### **A. INDICATIONS FOR ANTIBIOTICS**

In the absence of a CSF leak, systemic prophylactic antibiotics are not indicated in temporal bone fractures. Brodie and Thompson found a 1 percent incidence of meningitis in patients without a CSF leak. Conflicting data exist regarding prophylactic antibiotics used in patients with a suspected or known CSF fistula. The vast majority of patients with a CSF fistula will resolve with conservative measures, and antibiotics may not provide any benefit. However, patients who have a

## CHAPTER 6: Temporal Bone Fractures

persistent CSF leak have a significantly higher risk of meningitis. Therefore, patients who have failed conservative therapy with a persistent CSF leak may benefit from systemic prophylactic antibiotics. A short course of ototoxic antibiotics is routinely prescribed for traumatic perforation. In addition to the antibiotic properties, ofloxacin otic solution drops may help clean the ear and limit crusting and debris buildup, making future assessment easier.

### **B. HEARING LOSS**

Temporal bone injury can result in a CHL, SNHL, or mixed loss. Patients with a unilateral hearing loss following temporal bone injury will have difficulty communicating, localizing sounds, and hearing a noise. A persistent CHL can be managed successfully with amplification or surgery.

Surgery for CHL related to temporal bone trauma is generally associated with good results, unless the Eustachian tube is obstructed as a result of the fracture. A variety of tympanoplasty and ossiculoplasty techniques exist for repairing the middle ear structures and reestablishing acoustic coupling between the TM and stapes. Systemic steroids should be considered for patients with SNHL or mixed hearing loss. Persistent mild, moderate, or severe mixed losses can be managed with the use of amplification. Single-sided deafness can be managed with a cross hearing aid or a bone-anchored hearing aid.

### **C. FACIAL NERVE INJURY**

According to Brodie and Thompson, facial nerve injury occurs in 7 percent of temporal bone injuries. The facial nerve is most often injured at the perigeniculate region. The most important prognostic indicator is the presence or absence of immediate onset of complete facial paralysis. Patients who present with normal or incomplete facial paralysis rarely will require facial nerve decompression and exploration. Establishing early baseline function is critical for identifying the small subset of patients with severe injury who may benefit from facial nerve surgery. The early use of steroids may benefit recovery in certain patients who have complete paralysis. Poor prognostic indicators include otic capsule-involving fractures, radiologic indication of severe facial nerve injury, complete facial paralysis at presentation, and evidence of degeneration on ENOG.

Aggressive eye protection with lubricants, moisture chambers, or surgery can prevent exposure keratitis in patients with facial nerve paralysis. In patients who recover some motor function but have some

sequelae of facial nerve injury, such as residual weakness or synkinesis, Botox® injections can be useful in improving symmetry. Patients who do not recover facial motor function may benefit from a variety of facial reanimation techniques.

#### **D. CSF LEAKS**

Most CSF leaks will spontaneously resolve after the fractures are repaired. CSF leaks that persist after conservative measures and lumbar drain increase the risk of meningitis and require surgical exploration for closure. Because identifying the exact location of a CSF fistula can be challenging, intrathecal fluorescein is a useful adjunct during exploration. Small leaks may be treated with autologous tissue (such as fascia, pericranium, bone paté, or dural substitutes), glues, or hydroxyapatite formulations to patch or plug defects.

Most leaks are approached via the mastoid. A large tegmental defect of CSF leak through the tegmen may be best approached with a combined mastoid and middle cranial fossa technique. Most CSF leaks requiring surgical treatment will benefit from continued lumbar drainage for several days after the repair. Larger leaks may require tympanomastoid obliteration, which involves transection of the EAC, plugging of the Eustachian tube, and obliteration of the mastoid and middle ear with abdominal fat. This is an excellent method in patients with associated hearing loss. In a normal-hearing individual, this treatment will result in a CHL, but for large or multiple leaks it may be necessary. Transnasal techniques to close the Eustachian tube have also been described, but are not widely employed.

#### **E. CHOLESTEATOMA AND EXTERNAL AUDITORY CANAL INJURY**

Entrapment of epithelium can occur with blunt trauma, but is more often associated with penetrating temporal bone trauma. Over time, a small fragment of epithelium buried in soft tissue can lead to a cholesteatoma. Unless a patient has gross evidence of epithelial entrapment, identifying risk for this injury is frequently difficult,

Patients with penetrating or severe injury of the EAC are at risk for developing an entrapment cholesteatoma. Patients with obvious entrapment should undergo mastoidectomy and/or canalplasty techniques to debride, remove epithelium, and reconstruct. Other patients should undergo serial clinical observation with the use of CT as indicated for monitoring of late development of entrapment cholesteatoma. Extensive injury to the EAC may also result in stenosis. Once the

## CHAPTER 6: Temporal Bone Fractures

patient is stable and hearing has been evaluated, a canalplasty and split thickness skin graft may be considered and performed.

Figure 6.6 is a series of radiographs from a soldier with a penetrating shrapnel injury of the right temporal bone. He sustained a comminuted fracture of the mastoid tip and EAC and later developed entrapment cholesteatoma and EAC stenosis. Although his fracture did not involve the otic capsule, he developed a profound SNHL on the right side.

### F. LATE MENINGOCELE AND/OR ENCEPHALOCELE DEVELOPMENT

Severe injury of the tegmen can result in late development of a meningocele or encephalocele. The weight of the temporal lobe, intracranial pressure, and gravity can slowly cause encephaloceles or brain herniation into the epitympanum or mastoid. These usually present as a late CSF leak, meningitis, or a CHL. Diagnosis is confirmed on CT demonstrating a tegmen defect and nondependent soft tissue. Magnetic resonance imaging can be confirmatory, demonstrating disruption of the meninges or brain herniation into the mastoid. Management is usually surgical, consisting of a combined middle cranial fossa and transmastoid repair.

### G. LATE MENINGITIS

Several factors can contribute to the development of late meningitis. Disruption of normal barriers between the ear and intracranial cavity may allow spread of an episode of acute otitis media. This can occur in the presence of a meningocele and encephalocele, as well as an otic capsule-involving fracture. The otic capsule heals through a fibrous, rather than osseous, process, the former of which allows the spread of middle ear infection into the otic capsule and, ultimately, the intracranial space. Persistent episodes of meningitis in the presence of chronic otitis media may require tympanomastoid obliteration for management.

## VII. Summary

Temporal bone fractures most often result from blunt trauma. They can result in a number of serious injuries and complications, including soft tissue injury, lacerations, hematoma, hearing loss, CSF leak, facial nerve injury, vestibular injury, and carotid injury. Late complications can include encephalocele, entrapment cholesteatoma, EAC stenosis, and meningitis.

Most patients with temporal bone fractures have associated injuries, which often take management priority. The early evaluation and management of these patients includes a team of emergency room



physicians, trauma surgeons, radiologists, neurosurgeons, and otolaryngologists. After the patient is stabilized, the sequelae of the temporal bone fractures can undergo further evaluation and management. The otolaryngology evaluation should establish baseline facial nerve function and assess for the presence of a CSF leak, in addition to identifying hearing and balance deficits related to the fracture. Once the patient is stabilized, a thorough head and neck and neurological examination should be performed, along with a dedicated temporal bone noncontrast CT and audiogram or bedside hearing assessment. Confirming a CSF leak and deciding the optimal therapy for facial nerve dysfunction are the primary challenges faced during the evaluation of temporal bone fractures.

### **VIII. References and Suggested Readings**

- Brodie HA, Thompson TC. Management of complications from 820 temporal bone fractures. *Am J Otol.* 1997;18:188-197.
- Cannon CR, Jahrsdoerfer RA. Temporal bone fractures: Review of 90 cases. *Arch Otolaryngol.* 1983;109:285-288.
- Chang JCY, Cass S. Management of facial nerve injury due to temporal bone trauma. *Am J Otol.* 1999;20:96.
- Dahiya R, Keller JD, Litofsky NS, Bankey PE, Bonassar LJ, Megerian CA. Temporal bone fractures: Otic capsule sparing versus otic capsule violating clinical and radiographic considerations. *J Trauma.* 1999;47:1079-1083.
- Johnson F, Semaan MT, Megerian CA. Temporal bone fracture: Evaluation and management in the modern era. *Otolaryngology Clinics of North America.* 2008;41(3):597-618.
- Little SC, Kesser BW. Radiographic classification of temporal bone fracture: Clinical predictability using a new system. *Arch Otolaryngol Head Neck Surg.* 2006;132(12):1300-1304.
- Nosan DK, Benecke JE, Murr AH. Current perspective on temporal bone trauma. *Otolaryngol Head Neck Surg.* 1997;117(1): 67-71.

# Chapter 7: Penetrating and Blunt Neck Trauma

Nathan L. Salinas, MD, Captain, MC, USA  
Joseph A. Brennan, MD, Colonel, MC, USAF

## I. Penetrating Neck Trauma

### A. INTRODUCTION

Penetrating neck trauma has historically carried a high mortality rate, ranging as high as 16 percent during World War I when nonsurgical management was performed.<sup>1</sup> During World War II, when mandatory neck exploration was instituted, the mortality fell to 7 percent and remained 4-7 percent during the Vietnam War.

Surgical management has evolved over the last two decades, based on the advent of advanced radiographic studies and endoscopic techniques. Most civilian centers currently practice selective neck exploration, with mortality rates ranging 3-6 percent for low-velocity penetrating neck trauma (LVPNT).<sup>2-6</sup> Most recently, U.S. military surgeons have treated high-velocity penetrating neck trauma (HVPNT) patients with selective neck exploration and have reported mortality rates equivalent to civilian mortality rates for LVPNT.<sup>6</sup>

### B. PROJECTILES, BALLISTICS, AND MECHANISMS OF INJURY

Different types of projectiles are associated with different ballistics and mechanisms of injury, since the severity of projectile injury is directly related to the kinetic energy that the missile imparts to the target tissue (Box 7.1).<sup>7</sup>

#### Box 7.1. Formula for the Relationship Between Projectile Injury and Kinetic Energy

The formula for the relationship between the severity of projectile injury and the kinetic energy that the missile imparts to the target tissue is as follows:

$$KE = \frac{1}{2} M (v_1 - v_2)^2$$

KE = kinetic energy of the missile

M = missile mass

V1 = entering velocity

V2 = exiting velocity<sup>7</sup>

### 1. The Most Lethal Missiles

The most lethal missiles are high-velocity projectiles that impart all of their energy into the tissues without exiting ( $V_2 = 0$ ). These types of projectiles include:

- Tumbling missiles.
- Expanding bullets.
- Explosive bullets.

### 2. Temporary and Permanent Bullet Cavities

Given the above understanding of kinetic energy of missiles, a single projectile will form two bullet cavities upon tissue impact:

- The permanent cavity follows the injury tract due to the direct disruption of tissue from the missile.
- The temporary cavity is proportional to the kinetic energy of the missile, and may be up to 30 times the cross-section of the missile along the injury tract.<sup>7</sup>

### 3. Historical Categorization, Types, and Treatment of Penetrating Neck Wounds

High-velocity projectiles cause significantly more damage and tissue destruction when compared to low-velocity projectiles. Table 7.1 presents the categories of missiles resulting in penetrating neck trauma and the types of wounds they cause. Historically, these wound types have been divided into low- and high-velocity trauma.

**Table 7.1. Historical Categories of Missiles and Types of Penetrating Neck Wounds**

Categories of Missiles Resulting in Penetrating Neck Wounds	Types of Penetrating Neck Wounds	
	Low Velocity (<610m/s)	High Velocity (>610m/s)
<b>Knives</b> <b>Single Projectiles</b> <ul style="list-style-type: none"> <li>• Handguns</li> <li>• Rifles</li> </ul> <b>Multiple Projectiles</b> <ul style="list-style-type: none"> <li>• Shotgun pellets</li> <li>• Improvised explosive devices (IEDs)</li> <li>• Grenades</li> <li>• Mortars</li> <li>• Rocket</li> </ul>	<ul style="list-style-type: none"> <li>• Stab wounds</li> <li>• Handgun wounds</li> <li>• Long-range (&gt;5 m victim-to-weapon range) birdshot wounds</li> <li>• Long-range buckshot wounds</li> </ul>	<ul style="list-style-type: none"> <li>• Close-range (&lt;5 m victim-to-weapon range) birdshot wounds</li> <li>• Close-range buckshot wounds</li> <li>• Rifle wounds</li> <li>• Wounds from bombs, IEDs, grenades, mortars, and rockets</li> </ul>

< = less than; > = more than; m/s = meters per second.

## CHAPTER 7: Penetrating and Blunt Neck Trauma

### 4. Historical Treatment of Penetrating Neck Wounds

Since World War II, surgeons have stratified management of penetrating neck trauma based on mortality rates and the rates of pathology discovered during neck exploration.<sup>4</sup>

#### **a. Low-Velocity Penetrating Neck Trauma**

LVPNT was typically managed with selective neck dissection, since the overall mortality rate was 3–6 percent with less than 50 percent of patients having major pathology found on neck exploration.

#### **b. High-Velocity Penetrating Neck Trauma**

On the other hand, HVPNT was historically treated with mandatory neck exploration, since those patients had mortality rates greater than 50 percent with 90–100 percent major pathology found on neck exploration due to the tremendous amount of kinetic energy (up to 3,000 foot-pounds) imparted to the tissue. However, as previously discussed, selective neck dissection is currently used by combat surgeons to treat HVPNT in both Iraq and Afghanistan, with resulting low morbidity and mortality similar to rates seen in civilian trauma centers managing LVPNT.<sup>6</sup>

## C. EMERGENCY ROOM MANAGEMENT

### 1. Initial Orderly Assessment

Initial orderly assessment, using the Advanced Trauma Life Support protocol as developed by the American College of Surgeons, is appropriate in any trauma. This protocol includes rapid assessment of the “A, B, Cs” of trauma. Accordingly, airway management is the first priority in penetrating neck trauma.<sup>8</sup>

#### **a. Airway Management**

- Approximately 10 percent of patients present with airway compromise, with larynx or trachea injury.<sup>5,9</sup> While endotracheal intubation may be performed in these patients, nasotracheal intubation, cricothyroidotomy, or tracheostomy may be required in the presence of spinal instability.
- To avoid air embolism, the patient should be supine or in Trendelenburg’s position.
- Direct pressure without indiscriminate clamping should be used to control active hemorrhage in the neck.
- Deeply probing open neck wounds below the platysma muscle should be avoided in the emergency room, as this may lead to clot dislodgement and subsequent hemorrhage.
- Two large-bore intravenous lines should be placed to establish access for fluid resuscitation. Subclavian vein injuries should be suspected in

Zone I injuries (as discussed below), and intravenous access should be placed on the contralateral side of the penetrating injury to avoid extravasation of fluids.

- Spinal stabilization should be maintained until cleared clinically and/or radiographically.
- Tetanus toxoid should be administered if the status is unknown or outdated.
- If possible, initial radiographic survey in the trauma bay should include chest x-ray and cervical spine x-rays.
- Prophylactic antibiotics and nasogastric tube suction placement should also be considered.

## D. ANATOMY

### 1. Vital Structures in the Neck

To organize primary assessment, secondary survey, and surgical approaches to penetrating neck injuries, four types of vital structures in the neck must be considered:

- Airway (pharynx, larynx, trachea, and lungs).
- Blood vessels (carotid arteries, innominate artery, aortic arch vessels, jugular veins, and subclavian veins).
- Nerves (spinal cord, brachial plexus, cranial nerves, and peripheral nerves).
- Gastrointestinal tract (pharynx and esophagus).

### 2. Skeletal Anatomy

Skeletal anatomy should be considered as well:

- Mandible.
- Hyoid.
- Styloid process.
- Cervical spine.

### 3. Muscular Landmarks

Muscular landmarks are also important:

- *Platysma muscle*—Penetration of the platysma muscle defines a deep injury in contrast to a superficial injury.
- *Sternocleidomastoid muscle*—The sternocleidomastoid muscle also serves as a valuable landmark, since this large, obliquely oriented muscle divides each side of the neck into anterior and posterior triangles.
- *Anterior triangle*—The anterior triangle contains airway, major vasculature, nerves, and gastrointestinal structures, while the posterior triangle contains the spine and muscle.

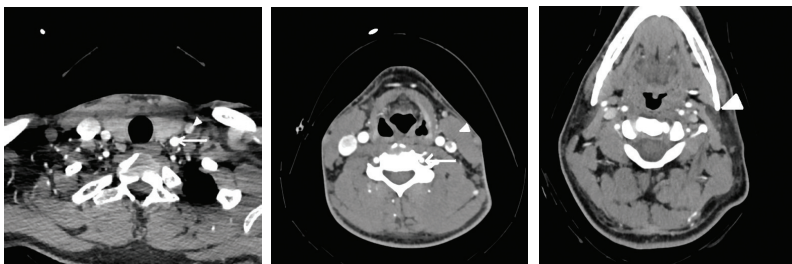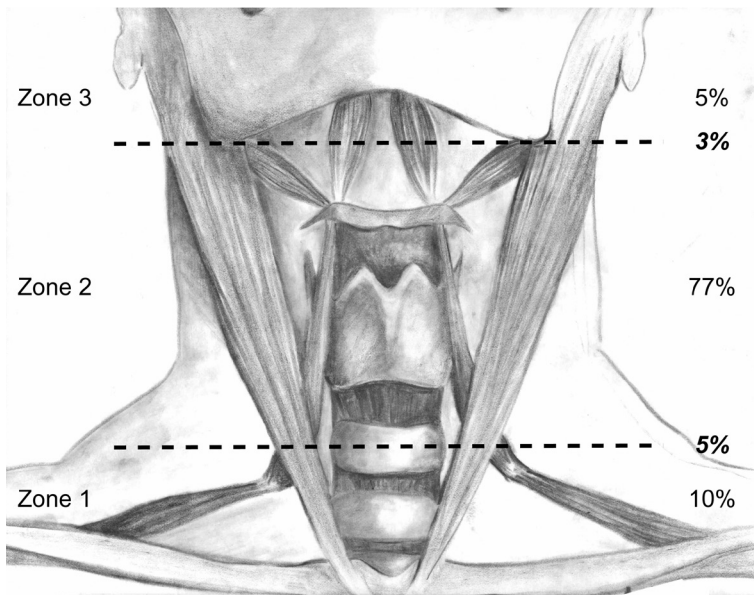
## CHAPTER 7: Penetrating and Blunt Neck Trauma

### 4. Neck Zones

The neck is commonly divided into three distinct zones, which facilitates initial assessment and management based on the limitations associated with surgical exploration and hemorrhage control unique to each zone (Figure 7.1).

**Figure 7.1**

The neck is divided into Zones 1, 2 and 3. The axial computed tomographic (CT) images below correspond to Zone 1, Zone 2, and Zone 3.



Zone 1

Zone 2

Zone 3

### **a. Zone 1**

Zone 1, the most caudal anatomic zone, is defined inferiorly by the clavicle/sternal notch and superiorly by the horizontal plane passing through the cricoid cartilage. Structures within this zone include the:

- Proximal common carotid arteries.
- Vertebral and subclavian arteries.
- Subclavian, innominate, and jugular veins.
- Trachea.
- Recurrent laryngeal and vagus nerves.
- Esophagus.
- Thoracic duct.

Vascular injury management is challenging in Zone 1, and mortality is high. Due to the sternum, surgical access to Zone I may require sternotomy or thoracotomy to control hemorrhage.

### **b. Zone 2**

Zone 2, the middle anatomic zone, is between the horizontal plane passing through the cricoid cartilage and the horizontal plane passing through the angle of the mandible. Vertically or horizontally oriented neck exploration incisions provide straightforward surgical access to this zone, which contains the:

- Carotid arteries.
- Jugular and vertebral veins, pharynx, and larynx.
- Proximal trachea.
- Recurrent laryngeal and vagal nerves.
- Spinal cord.

### **c. Zone 3**

Zone 3, the most cephalad anatomic zone, lies between the horizontal plane passing through the angle of the mandible and the skull base. Anatomic structures within Zone 3 include the:

- Extracranial carotid and vertebral arteries.
- Jugular veins.
- Spinal cord.
- Cranial nerves IX–XII.
- Sympathetic trunk.

Because of the craniofacial skeleton, surgical access to Zone 3 is difficult, making surgical management of vascular injuries challenging with a high associated mortality at the skull base. Surgical access to Zone 3 may require craniotomy, as well as mandibulotomy or maneuvers to anteriorly displace the mandible.

## CHAPTER 7: Penetrating and Blunt Neck Trauma

### 5. Vascular Injuries

The incidence of vascular injuries is higher in Zone 1 and Zone 3 penetrating neck trauma injuries. This occurs because the vessels are fixed to bony structures, larger feeding vessels, and muscles at the thoracic inlet and the skull base. Consequently, when the primary and temporary cavities are damaged, these vessels are less able to be displaced by the concussive force from the penetrating missile. However, in Zone 2, the vessels are not fixed; therefore, they are more easily displaced by concussive forces, and the rate of vascular injury is lower.

Also, in Zone 1, the esophagus is at risk for injury. Missed esophageal injuries occur because up to 25 percent of penetrating esophageal injuries are occult and asymptomatic.<sup>10</sup> These missed esophageal injuries may be devastating, with reported mortality rates approaching 25 percent.<sup>10</sup> Therefore, for Zone 1 and for some Zone 2 penetrating neck injuries, it is imperative that esophageal injuries be ruled out with endoscopic examination and, possibly, swallow studies.

## E. DIAGNOSTIC EVALUATION AND SURGICAL TREATMENT

### 1. Selective Neck Exploration

Selective neck exploration may be utilized to manage penetrating neck trauma when two important conditions are present at the trauma facility: reliable diagnostic tests that exclude injury and appropriate personnel to provide active observation.<sup>6,11</sup> In the setting of these two conditions, contemporary penetrating neck trauma management is selective neck exploration.

#### a. Patient's Symptoms at Presentation

The decision whether to explore the penetrating neck wound is determined based on the patient's symptoms at presentation, regardless of the missile velocity.

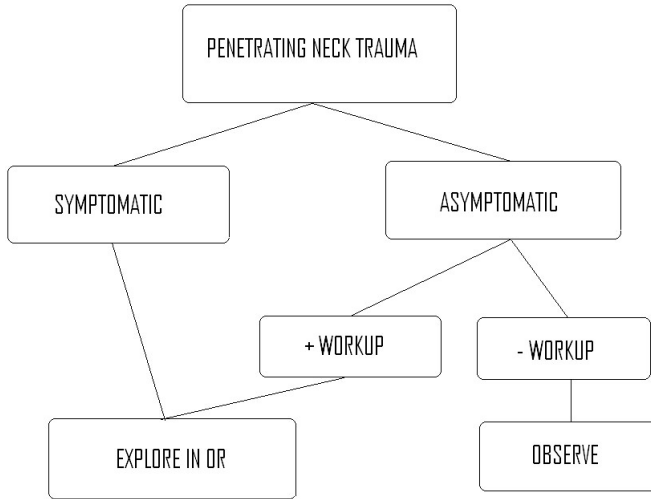
- *Symptomatic patients* are explored in the operating room. If symptomatic patients are stable, computed tomographic angiography (CTA) may be obtained before exploration, since this study may better define anatomic approaches to Zone 1 and Zone 3 of the neck.
- *Asymptomatic patients* are evaluated with diagnostic studies and, if pathologic findings are discovered during this workup, are taken to the operating room for neck exploration (Figure 7.2). If asymptomatic patients have a negative diagnostic workup showing no neck pathology, then they will be observed.

Significant symptoms from penetrating neck trauma will occur, depending on which of the four groups of vital structures in the neck are injured.



**Figure 7.2**

Management algorithm based on symptoms if computed tomographic angiography (CTA), panendoscopy, and appropriate personnel are available.



- *Vascular injury* may result in active hemorrhage, expanding hematoma, vascular bruit, and pulse deficit.
- *Airway injury* may cause subcutaneous emphysema, hoarseness, stridor, and respiratory distress.
- *Esophageal injury* is often asymptomatic and may result in leakage of saliva, subcutaneous emphysema, bleeding from the esophageal inlet, and ultimately neck or mediastinal abscess.
- *Nerve injury* may result in cranial nerve deficits or hemiparesis. These fixed neurologic deficits may not require immediate neck exploration in an otherwise stable patient.

## 2. Mandatory Neck Exploration

If appropriate diagnostic testing and personnel are not available, then penetrating neck trauma patients should undergo mandatory neck exploration, or if stable, should be immediately transferred to a facility with those capabilities.

## 3. Computed Tomographic Angiography

Computed tomographic angiography (CTA) is generally considered the initial procedure of choice to evaluate cervical vasculature in asymptomatic penetrating neck trauma. In the past, formal neck angiography via groin catheters was the procedure of choice. However, since CTA

## CHAPTER 7: Penetrating and Blunt Neck Trauma

has a sensitivity ranging between 90 percent and 100 percent, along with a specificity ranging between 93 percent and 100 percent, this procedure is currently used to evaluate neck vessels.<sup>3,12-14</sup>

### **a. Signs of Probable Injury on CTA**

Signs of probable injury on CTA include:

- Hematoma.
- Subcutaneous air adjacent to the carotid sheath.
- Intravenous contrast extravasation.
- Missile tracts in close proximity to vital structures.<sup>14</sup>

### **b. Nondiagnostic Studies on CTA**

CTA may have a 1.2-2.2 percent incidence of nondiagnostic studies due to the artifact from bullet fragments and metallic foreign bodies.<sup>5,15</sup> CTA is also useful in evaluating the trajectory of the missile tract and may help select patients who will benefit from further workup of the aerodigestive tract.

## **4. Evaluation of Aerodigestive Tract Injuries**

Aerodigestive tract injuries, especially those involving the cervical esophagus, should be identified and repaired within 12-24 hours after injury to minimize associated morbidity and mortality. Evaluation of asymptomatic aerodigestive tract injuries includes contrast swallow studies and endoscopy (rigid and flexible esophagoscopy, bronchoscopy, and laryngoscopy).

### **a. Endoscopy**

Endoscopy is more reliable than contrast swallow studies to identify injuries to the hypopharynx and cervical esophagus. Several authors have demonstrated that endoscopy will identify 100 percent of digestive tract injuries, whereas contrast swallow studies are less sensitive, especially for hypopharyngeal injuries.<sup>16,17</sup>

### **b. Rigid and Flexible Esophagoscopy, Rigid and Flexible Bronchoscopy, and Rigid Direct Laryngoscopy**

Rigid and flexible esophagoscopy, rigid and flexible bronchoscopy and rigid direct laryngoscopy are performed in the operating room under general anesthesia. It is recommended that both rigid and flexible esophagoscopy be performed to rule out occult esophageal injuries.

### **c. Rigid and Flexible Esophagoscopy**

Rigid esophagoscopy may provide a better view of the proximal esophagus near the cricopharyngeal muscle, while flexible esophagoscopy, with its magnification on the viewing screen and ability to insufflate, gives excellent visualization of more distal esophageal anatomy.

#### **d. Swallow Studies**

Finally, swallow studies with either gastrograffin or barium may not be available in austere environments to rule out occult esophageal injuries and, as noted above, are less accurate than endoscopy.<sup>6</sup> Missed esophageal injuries, which may be occult in 25 percent of patients, can be devastating, with mortality rates ranging up to 25 percent.<sup>10</sup>

### **F. CONCLUSION**

Penetrating neck trauma patients can be divided into two categories on presentation: symptomatic and asymptomatic. Symptomatic patients are taken to the operating room for neck exploration. Asymptomatic patients undergo workup with CTA, panendoscopy, and possibly swallow studies. If the workup shows occult neck pathology, then those patients are taken to the operating room for neck exploration. Asymptomatic patients with a negative diagnostic workup are observed.

## **II. Blunt Neck Trauma**

### **A. INTRODUCTION**

Although the same anatomic structures described in penetrating neck trauma (airway, vascular structures, nerves, and gastrointestinal tract) may be impacted during blunt neck trauma. The laryngotracheal airway and cervical spine are the most clinically susceptible to injury. Vascular injuries are potentially devastating but are uncommon overall, occurring in 0.08–1.5 percent of blunt neck trauma, depending on how aggressively asymptomatic patients are screened.<sup>18,19</sup> Despite the widespread use of advanced safety mechanisms, such as shoulder harness seatbelts and airbags, motor vehicle collisions remain the most common etiology for blunt neck trauma. Other mechanisms include blunt object impact sustained in assault, and sports injuries, crush injuries, and hanging or clothesline trauma.

### **B. PRESENTING SIGNS AND SYMPTOMS**

As in penetrating neck trauma, the presenting signs and symptoms of blunt neck trauma injuries are based on the dysfunction of the anatomic structures in the neck. Therefore, evaluation of the blunt neck trauma patient should follow the rapid, orderly process of trauma assessment, starting with the airway.

#### **1. Initial Diagnostic Airway Evaluation**

Initial diagnostic airway evaluation with flexible laryngoscopy is helpful in documenting endolaryngeal findings as well as post-injury changes, since significant edema may occur during the first 12–24 hours.<sup>20</sup>

## CHAPTER 7: Penetrating and Blunt Neck Trauma

- Computed tomographic (CT) imaging may be considered for surgical planning in symptomatic patients or in asymptomatic patients with suspected laryngeal injury.
- Securing the airway is advocated in the setting of acute airway symptoms, such as stridor or respiratory distress, prior to considering imaging.

### 2. Hemodynamic Instability or Signs of Vascular Injury

Hemodynamic instability or signs of vascular injury, such as bruit, expanding/pulsating hematoma, hemorrhage, or loss of pulse, warrant surgical exploration, as described in the Penetrating Neck Trauma section (Section I) of this chapter.

### 3. Hemodynamically Stable Patients Showing Risk Factors

Hemodynamically stable patients should undergo initial diagnostic imaging with CTA if at-risk factors are present, including severe cervical injury, anoxic brain injury from hanging, closed head injury with diffuse axonal injury, midface or complex mandibular fractures, marked neck soft tissue swelling injury, high-risk cervical spine fractures (such as vertebral body subluxation, C1-3 vertebral body fracture, and any fracture extending into the transverse foramen), or basilar skull fractures involving the carotid canal.<sup>21</sup>

### 4. Cervical Spine Injury Assessment

After clinical examination, cervical spine injury assessment should include initial lateral and anteroposterior plain x-ray films if possible. Further evaluation with imaging should be based on the individual patient's musculoskeletal and neurologic complaints, as well as physical exam findings.

## C. CONCLUSION

The laryngotracheal airway and the cervical spine are the two most integral structures that can be damaged in blunt trauma to the neck. Prior to any intervention, such as flexible fiberoptic evaluation of the airway, the neck must be stabilized securely in line. The status of the cervical spine takes evaluative precedence after the airway has been secured in a manner that does not compromise a potential cervical spine injury. Hemodynamic stability or instability will be an important guide to the urgency of intervention, including diagnostic CTA prior to exploration of the neck to control bleeding and secure the vascular elements. An excellent physical examination must always be performed and will be the clinical guide to the next steps in evaluation and treatment.

### III. References

1. Obeid FN, Haddad GS, Horst HM, et al. A critical reappraisal of a mandatory exploration policy for penetrating wounds of the neck. *Surg Gynecol Obstet.* 1985;160:517-522.
2. Brennan JA, Meyers AD, Jafek BW. Penetrating neck trauma: A 5-year review of the literature, 1983 to 1988. *Am J Otolaryngol.* 1990;11:191-197.
3. Osborn TM, Bell RB, Qaisi W, Long WB. Computed tomographic angiography as an aid to clinical decision making in the selective management of penetrating injuries to the neck: A reduction in the need for operative exploration. *J Trauma.* 2008;64:1466-1471.
4. Ordog GJ, Albin D, Wasserberger J, et al. Shotgun "birdshot" wounds to the neck. *J Trauma.* 1988;28:491-497.
5. Carducci B, Lowe RA, Dalsey W. Penetrating neck trauma: Consensus and controversies. *Ann Emerg Med.* 1986;15:208-215.
6. Brennan J, Lopez M, Gibbons MD, et al. Penetrating neck trauma in Operation Iraqi Freedom. *Otolaryngol Head Neck Surg.* 2011; 144(2): 180-185.
7. Holt GR, Kostohryz G Jr. Wound ballistics of gunshot injuries to the head and neck. *Arch Otolaryngol.* 1983;109:313-318.
8. Brennan J, Gibbons MD, Lopez M, et al. Traumatic airway management in Operation Iraqi Freedom. *Otolaryngol Head Neck Surg.* 2011;144(3): 376-380.
9. McConnell D, Trunkey D. Management of penetrating trauma to the neck. *Adv Surg.* 1994;27:97.
10. Shama DM, Odell J. Penetrating neck trauma with tracheal and oesophageal injuries. *Br J Surg.* 1984;71:534-536.
11. Biffi WL, Moore EE, Rehse DH, et al. Selective management of penetrating neck trauma based on cervical level of injury. *Am J Surg.* 1997;174: 678-682.
12. Munera F, Danton G, Rivas LA, Henry RP, Ferrari MG. Multidetector row computed tomography in the management of penetrating neck injuries. *Semin Ultrasound CT MRI.* 2009;30:195-204.

## CHAPTER 7: Penetrating and Blunt Neck Trauma

13. Inaba K, Munera F, McKenney, et al. Prospective evaluation of screening multislice helical computed tomographic angiography in the initial evaluation of penetrating neck injuries. *J Trauma*. 2006;61:144-149.
14. Mazolewski PJ, Curry J, Browder J, Fildes J. Computed tomographic scan can be used for surgical decision making in Zone II penetrating neck injuries. *J Trauma*. 2001;51:315-319.
15. Jurkovich GJ, Zingarelli W, Wallace J, Curreri PW. Penetrating neck trauma: Diagnostic studies in the asymptomatic patient. *J Trauma*. 1985;25:819-822.
16. Ahmed N, Massier C, Tassie J, Whalen J, Chung R. Diagnosis of penetrating injuries of the pharynx and esophagus in the severely injured patient. *J Trauma*. 2009;67:152-154.
17. Armstrong WB, Detar TR, Stanley RB. Diagnosis and management of external penetrating cervical esophageal injuries. *Ann Otol Rhinol Laryngol*. 1994;103:863-871.
18. Davis JW, Holbrook TL, Hoyt DB, et al. Blunt carotid artery dissection: Incidence, associated injuries, screening, and treatment. *J Trauma*. 1990;30:1514-1517.
19. Kerwin AJ, Bynoe RP, Murray J, et al. Liberalized screening for blunt carotid and vertebral artery injuries is justified. *J Trauma Inj Infect Crit Care*. 2001;51:308-314.
20. Stanley R, Hanson D. Manual strangulation injuries of the larynx. *Arch Otolaryngol*. 1983;109:344-347.
21. Schroeder JW, Baskaran V, Aygun N. Imaging of traumatic arterial injuries in the neck with an emphasis on CTA. *Emerg Radiol*. 2010;17: 109-122.

## Chapter 8: Laryngeal Trauma

Joseph C. Sniezek, MD, Colonel, MC, USA

Richard W. Thomas, MD, DDS, Major General, MC, USA

Traumatic injuries of the larynx are diverse, uncommon, and potentially life threatening. While each laryngeal injury is unique, an organized and appropriate management algorithm for the various types of laryngeal trauma results in increased patient survival as well as improved long-term functional outcomes. The management of laryngeal trauma can be complex, as the signs and symptoms are often variable and unpredictable, with severe injuries sometimes presenting with mild and innocuous symptoms. The immediate goal in managing laryngeal trauma is to obtain and maintain a stable airway for the patient. Once the airway is safely secured, the laryngeal injury is repaired in order to optimize the patient's long-term functional outcomes terms of breathing, speech, and swallowing.

Laryngeal trauma is often divided into two main groups—blunt trauma and penetrating trauma. Blunt laryngeal trauma most commonly results from motor vehicle accidents, personal assaults, or sports injuries. Knife, gunshot, and blast injuries account for most cases of penetrating laryngeal trauma. Both blunt and penetrating laryngeal injuries may present along a spectrum of severity ranging from mild to fatal. Laryngeal trauma may also affect children, though pediatric injuries to the larynx are much less common than adult injuries, since the pediatric larynx sits much higher in the neck than the adult larynx and is, therefore, better protected by the mandible.

### I. Physical Examination

The immediate goal of the examination of a patient with suspected laryngeal trauma is to ascertain the severity of injury, rapidly identifying patients who require immediate airway intervention. This can be a challenge, since relatively minimal signs or symptoms may mask a severe injury that has not yet reached a critical level of obstruction.

#### A. SYMPTOMS OF LARYNGEAL TRAUMA (SUBJECTIVE)

- Pain or tenderness over the larynx.
- Voice change or hoarseness.
- Odynophagia.
- Dysphagia.

## CHAPTER 8: Laryngeal Trauma

### B. SIGNS OF LARYNGEAL TRAUMA (OBJECTIVE)

- Dyspnea.
- Stridor—The type of stridor may indicate the location of injury:
  - Inspiratory stridor implies a supraglottic obstruction that may be caused by edema or a hematoma.
  - Expiratory stridor generally results from a subglottic source, such as a tracheal injury.
  - Biphasic stridor (inspiratory and expiratory) implies an injury at the level of the glottis.
- Hemoptysis.
- Ecchymosis of overlying cervical skin.
- Subcutaneous emphysema.
- Loss of normal thyroid prominence.
- Deviation of larynx.
- Loss of laryngeal crepitus—A “click” is generally palpated when the larynx is palpated and moved laterally. The loss of this “click” may occur due to laryngeal fixation or an injured larynx.

## II. Diagnosis, Imaging Studies, and Laboratory Assessment

### A. AIRWAY EVALUATION

Once the airway is deemed to be stable, further evaluation of the laryngeal injury is possible. Flexible fiberoptic laryngoscopy is a critical step in evaluating the status of the airway after laryngeal trauma. It can and should be performed promptly, safely, and carefully during the initial evaluation. During this period of evaluation, it is critical to closely observe the patient’s airway for any signs of compromise or impending airway instability. If the airway worsens, a tracheotomy should be performed immediately.

### B. TRAUMA EVALUATION

A complete trauma assessment must be performed due to the possibility of concurrent injuries associated with laryngeal trauma.

### C. RADIOLOGIC EVALUATION

- Cervical spine injuries must be ruled out in all cases of laryngeal trauma.
- Chest x-ray is often helpful to rule out a pneumothorax, tracheal deviation, or pneumoediastinum (suggesting an airway injury).
- A computed tomography (CT) scan is indicated and helpful in all but the most minor laryngeal injuries. CT scans diagnose laryngeal



fractures and aid in operative planning for the repair and reconstruction of the fractured larynx.

### III. Surgical Decision-Making Principles

While each laryngeal injury is unique and must be treated as such, division of laryngeal injuries into an organized classification scheme helps to guide treatment planning and patient management. Laryngeal injuries are generally divided into five categories, based on the Shaefer Classification System's severity of injury (Table 8.1).

**Table 8.1. Classification Scheme for Categorizing the Severity of Laryngeal Injuries**

Groups	Severity of Injury in Ascending Order
Group 1	Minor endolaryngeal hematomas or lacerations without detectable fractures.
Group 2	More severe edema, hematoma, minor mucosal disruption without exposed cartilage, or nondisplaced fractures.
Group 3	Massive edema, large mucosal lacerations, exposed cartilage, displaced fractures, or vocal cord immobility.
Group 4	Same as group 3, but more severe, with disruption of anterior larynx, unstable fractures, two or more fractures lines, or severe mucosal injuries.
Group 5	Complete laryngotracheal separation.

Source: Schaefer Classification System.

#### A. GROUP 1

##### 1. Evaluation

After a complete trauma evaluation, flexible fiberoptic laryngoscopy is performed to carefully evaluate the airway.

##### 2. Management

These mild injuries are generally managed medically and do not require surgical intervention. The following adjunctive medical treatments may be helpful:

- Steroids.
- Antibiotics.
- Anti-reflux medications.
- Humidification.
- Voice rest.

## CHAPTER 8: Laryngeal Trauma

### B. GROUP 2

#### 1. Evaluation

Direct laryngoscopy and esophagoscopy should be performed, as injuries may be more severe than expected after flexible fiberoptic laryngoscopy.

#### 2. Management

Patients with Group 2 injuries should be serially examined, since the injuries may worsen or progress with time. Occasionally, these injuries may require a tracheotomy. Medical adjuncts may also be helpful (steroids, anti-reflux medications, humidification, voice rest, antibiotics).

### C. GROUP 3

#### 1. Evaluation

Direct laryngoscopy or esophagoscopy should be performed in the operating room.

#### 2. Management

- Tracheotomy is often required.
- Exploration and surgical repair of the injury are generally required. The following injuries will require surgical repair:
  - Disruption of anterior commissure.
  - Major endolaryngeal lacerations.
  - Tear involving vocal cord.
  - Immobile vocal cord.
  - Cartilage exposure.
  - Displaced cartilage fractures.
  - Arytenoid subluxation or dislocation.

### D. GROUP 4

#### 1. Evaluation

Direct laryngoscopy and esophagoscopy must be performed.

#### 2. Management

- Tracheotomy is always required.
- Surgical repair of these injuries will require stent placement to maintain integrity of the larynx.

### E. GROUP 5

#### 1. Evaluation

Disruption of the airway occurs at the level of the cricoid cartilage, either at the cricothyroid membrane or cricotracheal junction. These patients will present with severe respiratory distress, necessitating urgent airway evaluation and management.

## 2. Management

Tracheotomy is necessary to secure the airway, but can be very difficult due to the altered anatomy. Complex laryngotracheal repair must be performed through a low cervical incision (see below) after the airway is secured.

## IV. Informed Consent

When possible, surgical consent should always be obtained prior to the performance of surgical procedures. In the case of laryngeal trauma, informed surgical consent of the patient is critical, as multiple procedures over an extended period of time are sometimes required to repair and rehabilitate patients who suffer these injuries. Likewise, the effects of laryngeal trauma can have long-term impacts on quality of life, affecting the functions of speech, swallowing, and breathing. When informed consent from the patient is not possible due to the emergent nature of the injury, every effort should be made to obtain informed consent from a reliable family member or guardian.

## V. Perioperative Care

The goal of perioperative management in laryngeal trauma is to prevent progression of the injury and promote rapid healing.

### A. AIRWAY OBSERVATION

Hospitalization with airway observation for 24 hours is recommended for mild injuries that are at risk for progression or airway compromise (edema, hematoma). More severe injuries will require longer periods of hospitalization and rehabilitation.

### B. ADJUNCTIVE MEASURES

The following adjunctive measures may be helpful during the treatment of patients who suffer laryngeal trauma:

- *Head-of-bed elevation*—May help to resolve laryngeal edema.
- *Voice rest*—Minimizes worsening of laryngeal edema.
- *Cool humidified air*—Prevents crust formation in the presence of mucosal damage and limits transient ciliary paralysis.
- *Systemic corticosteroids*—Supporting data are minimal, but steroids may help to reduce edema in the early hours after injury.
- *Anti-reflux medication*—Limits potential for laryngeal inflammation.

## CHAPTER 8: Laryngeal Trauma

### C. SPEECH THERAPY

Speech therapy may be helpful for all patients who suffer laryngeal trauma. Speech pathology consultation should be obtained as early as possible after the initial laryngeal injury.

## VI. Operative Management by Location

### A. INHALATION INJURY

Inhalation injury is the most frequent cause of death in burn patients. Airway manifestations of inhalation injury may be extremely severe, as the upper airway absorbs the bulk of the thermal injury suffered during inspiration. Since inhalation injuries may occur without skin burns or other external injuries, a high index of suspicion must be maintained. A history and careful description of possible inhalation injuries should be elicited from either the patient or a witness to the event.

The full extent of airway compromise after inhalation injury may not be evident until 12 to 24 hours after the injury, so symptomatic patients should be admitted and observed. The upper aerodigestive tract should be evaluated serially with flexible laryngoscopy to follow the evolution of the injury. If acute upper airway obstruction is impending or imminent, the most experienced clinician in airway management should intubate the patient and secure the airway. Once an inhalation injury is diagnosed, a multidisciplinary team consisting of otolaryngologists, pulmonologists, and respiratory therapists should be utilized to maximize pulmonary and respiratory care.

### B. ENDOLARYNGEAL TEARS

Tracheotomy placement will generally be necessary to adequately access and repair significant mucosal tears. During surgical repair, the endolarynx is generally best approached through a midline thyrotomy, along with a transverse incision through the cricothyroid membrane. If a concomitant median or paramedian vertical thyroid fracture happens to be present, it may also be used to gain access to the endolarynx. If the fracture is located more than 3 mm from the anterior commissure, however, a midline thyrotomy should still be performed.

All major endolaryngeal lacerations should be repaired with 5-0 or 6-0 absorbable suture. Even minor lacerations that involve the true vocal cord margin or anterior commissure should be closed. If the anterior attachment of the true vocal cord is severed, it should be resuspended by suturing the anterior end of the cord to the external perichondrium.

All exposed cartilage should be covered either primarily or with local mucosal advancement flaps. Displaced or subluxed arytenoid cartilages should also be carefully repositioned.

### **C. ENDOLARYNGEAL EDEMA**

Patients with significant laryngeal edema, particularly if it appears to be progressing, should undergo awake tracheotomy to prevent airway loss. After tracheotomy, the patient with significant laryngeal edema should be evaluated with direct laryngoscopy and esophagoscopy to uncover subtle injuries that may be masked by the edema and missed in initial flexible fiberoptic laryngoscopy. Adjunctive measures, such as head-of-bed elevation, corticosteroids, anti-reflux medications, and humidification should be strongly considered.

### **D. ENDOLARYNGEAL HEMATOMAS**

Patients with endolaryngeal hematomas should be admitted to the hospital for close airway observation, as even small hematomas may progress. Small, nonprogressing hematomas with intact mucosal coverage are likely to resolve spontaneously without significant sequelae. Adjunctive therapies, such as steroids, anti-reflux medication, humidification, and head-of-bed elevation are helpful. Large or expanding hematomas may lead to airway obstruction and necessitate placement of a tracheotomy.

### **E. RECURRENT LARYNGEAL NERVE INJURY**

Recurrent laryngeal nerve injury may occur after blunt or penetrating laryngeal injury. Recurrent laryngeal nerve injury after blunt laryngeal trauma may be due to either stretching of the nerve or nerve compression near the cricoarytenoid joint.

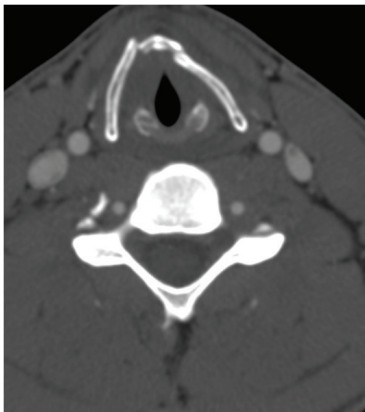
- If a vocal cord is persistently immobile after blunt trauma, the vocal fold should be observed for as long as one year to await the possible spontaneous regeneration of recurrent laryngeal nerve function.
- If a recurrent laryngeal nerve is severed, primary repair should be attempted. While vocal fold mobility will not be regained after even a successful repair due to the mixture of abductor and adductor fibers in the nerve, neural regeneration may prevent muscle atrophy, resulting in improved vocal cord tone and vocal strength in the long term.
- If primary re-anastomosis of the severed nerve is not possible, the ansa hypoglossi may be redirected and sutured to the distal stump of the recurrent laryngeal nerve to improve vocal cord muscle tone.

**F. LARYNGEAL FRACTURES**

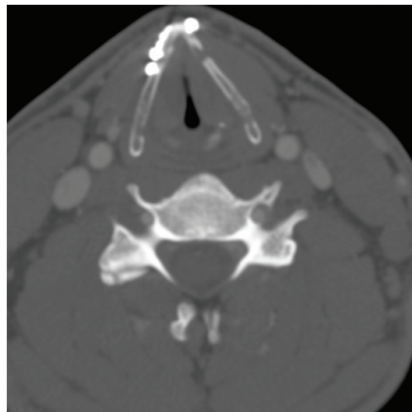
Nondisplaced laryngeal fractures may be observed, although very subtle, long-term voice changes may be noticed if they are not repaired. Displaced thyroid and cricoid cartilage fractures should be reduced and fixed to stabilize the laryngeal framework (Figure 8.1). If the displaced cartilage fracture occurs in conjunction with an endolaryngeal, soft tissue injury, the cartilage reduction and fixation should be performed prior to endolaryngeal soft tissue repair. This ensures that a proper scaffold is obtained before redraping the laryngeal mucosa. If no soft tissue injury accompanies the cartilage fracture, the cartilage may be fixed externally without entering the larynx.

Miniplate fixation of cartilage fractures is superior to wire or suture fixation. Thyroid fractures fixed with wire or suture tend to heal by fibrous—not cartilaginous—union, and often fail to maintain proper anatomic reduction. In particular, wire fixation poorly maintains the proper anatomic position of the thyroid laminae after fixation, allowing midline fractures to heal in an inappropriately flattened position.

When placing a miniplate into the soft cartilage of younger patients, it is often helpful to drill a smaller-than-usual screw hole that results in better purchase for fixation of the screw. Emergency screws may also be helpful in preventing stripped screws (Figure 8.2).



**Figure 8.1**  
CT scan of displaced thyroid cartilage fracture.



**Figure 8.2**  
CT scan of laryngeal fracture after repair with miniplate.

## **G. CRICOTRACHEAL (LARYNGOTRACHEAL) SEPARATION**

Cricotracheal (laryngotracheal) separation, also known as a Group 5 injury, is the least common but most life-threatening laryngeal injury. Most often, it occurs from “clothesline injuries” (i.e., when the neck contacts a taut line, such as a clothesline or wire support), and results in the separation of the larynx from the trachea at either the cricothyroid membrane or the cricotracheal junction.

Most patients with laryngotracheal separation present with significant respiratory distress and require a tracheotomy. Performance of the tracheotomy can be extremely difficult, however, because of the altered anatomy that results from this injury. After laryngotracheal separation, the larynx usually pulls upward and the trachea retracts into a position behind the sternum, necessitating a low tracheotomy incision. After successful tracheotomy, further radiologic testing, including chest x-ray and CT scans, may be performed. Pneumothorax commonly accompanies a laryngotracheal separation and must be promptly identified and treated.

Following appropriate trauma evaluation and radiologic studies, the patient should return to the operating room for direct laryngoscopy, esophagoscopy, and tracheal repair. The severed ends of the laryngotracheal complex should be freshened and then closed with nonabsorbable sutures with the knots placed extraluminally. Suprahyoid or infrahyoid release maneuvers may be required in order to allow for a tension-free anastomosis.

Most patients with laryngotracheal separation will also have bilateral vocal cord paralysis due to stretching or tearing of the recurrent laryngeal nerves. If the severed ends of the nerves can be located, they should be repaired primarily.

## **H. EMERGENCY AIRWAY MANAGEMENT**

Obtaining and maintaining a stable airway is the first and most important goal in managing laryngeal trauma. When evaluating the stability of the airway, it is important to remember that initially mild signs and symptoms may accompany a very severe laryngeal injury. Further, laryngeal injuries may evolve, progress, and worsen in a relatively short period of time. Therefore, carefully performed flexible fiberoptic laryngoscopy is a critical tool in the initial evaluation of the injured airway.

## CHAPTER 8: Laryngeal Trauma

If the airway is determined to be unstable, awake tracheotomy in an operating room should be performed. Intubation should ideally be avoided, as the endotracheal tube may further traumatize the endolarynx, destabilize laryngeal fractures, or lead to an acute airway compromise.

### I. SELECTION OF AIRWAY STENTS AND TRACHEOTOMY TUBES

#### 1. Airway Stents

Stents are often utilized in laryngeal injuries where the anterior commissure is significantly disrupted. In these cases, the stent functions to maintain the proper configuration of the commissure and to prevent anterior glottic webs. They are also occasionally used when massive, endolaryngeal mucosal injuries occur. In these cases, the stent helps to prevent mucosal adhesions and subsequent laryngeal stenosis.

If complete mucosal integrity is reestablished and the laryngeal fractures are properly reduced, stents are best avoided due to their potential complications—infection, pressure necrosis, and granulation tissue formation. While the best type of stent is very controversial, solid silastic stents are generally preferred. In austere settings, stents may be fashioned from portions of endotracheal tubes or a finger cut from a surgical glove and filled with a soft material, such as Gelfoam®. Stents are usually left in place for 2 weeks and removed in the operating room via an endoscopic procedure.

#### 2. Tracheotomy Tubes

Cuffed, nonfenestrated tracheotomy tubes are preferred, as they minimize airflow over the injured larynx. 6-0 tracheotomy tubes are usually adequate for both male and female patients.

### VII. Summary

Laryngeal trauma may result from either a blunt or a penetrating injury. The immediate priority in the treatment of laryngeal injuries is to establish and maintain a stable airway. Airway evaluation should include flexible fiberoptic laryngoscopy and a thorough examination of the head and neck. Further, patients with laryngeal injuries should be evaluated serially, as laryngeal hematomas or edema may progress or worsen with time, ultimately leading to airway compromise or obstruction. Finally, very mild initial signs and symptoms may occasionally mask a very severe laryngeal injury.



Mild laryngeal trauma may be managed with patient observation and adjunctive measures, such as humidified air, voice rest, steroids, and head-of-bed elevation. If the airway becomes precarious or the patient is at risk of airway compromise, an awake tracheotomy should be performed in the operating room.

In general, displaced laryngeal cartilage fractures should be repaired with miniplates to establish a stable laryngeal framework. Mucosal lacerations should be primarily repaired with 5-0 or 6-0 absorbable sutures. Stents may be placed if the anterior commissure is significantly injured or if there are multiple, severe endolaryngeal lacerations. These stents are usually removed at 2 weeks post-placement via an endoscopic procedure in the operating room. Finally, speech therapy plays a vital role in the recovery and rehabilitation of patients who suffer laryngeal trauma.

## VIII. References

Jalisi S, Zoccoli M. Management of laryngeal fractures—A 10-year experience. *Journal of Voice*. Jul 2011;25(4):473-479.

Jewett BS, Shockley WW, Rutledge R. External laryngeal trauma analysis of 392 patients. *Archives of Otolaryngology-Head & Neck Surgery*. Aug 1999;125(8):877-880.

Kantas I, Balatsouras DG, Kamargianis N, Katotomichelakis M, Riga M, Danielidis V. The influence of laryngopharyngeal reflux in the healing of laryngeal trauma. *European Archives of Oto-Rhino-Laryngology*. Feb 2009;266(2):253-259.

Mendelsohn AH, Sidell DR, Berke GS, John MS. Optimal timing of surgical intervention following adult laryngeal trauma. *Laryngoscope*. Oct 2011;121(10):2122-2127.

Norris BK, Schweinfurth JM. Arytenoid dislocation: An analysis of the contemporary literature. *Laryngoscope*. Jan 2011;121(1):142-146.

Quesnel AM, Hartnick CJ. A contemporary review of voice and airway after laryngeal trauma in children. *Laryngoscope*. Nov 2009;119(11):2226-2230.

Schaefer SD. The acute management of external laryngeal trauma. A 27-year experience. *Archives of Otolaryngology-Head & Neck Surgery*. 1192;118(2):598-604.

## Chapter 9: Soft Tissue Injuries of the Face, Head, and Neck

Matthew Scott Stevens, MD  
Christian L. Stallworth, MD

Soft tissue wounding arises from myriad etiologies, from knife or gunshot wounds to animal injuries, and from assaults to motor vehicle accidents. As in all trauma cases, airway security, maintenance of breathing, and circulation are of primary concern. Thereafter, attention may be turned toward repair of facial trauma. A complete head and neck exam can often be accomplished in the emergency room or outpatient surgery facility under local anesthesia with or without anesthesia monitoring. For difficult or complicated cases, operative intervention under general anesthesia, particularly in young children or in those patients with polytrauma or life-threatening injuries, may be considered. Surgical goals include functional and cosmetic restoration, while preserving tissue and preventing infection.

The information in this chapter is not meant to describe comprehensive, long-term care of all traumatic soft tissue injuries. Rather, it serves as a point of reference for the acute management of most all head and neck soft tissue trauma.

### I. Physical Examination

- Assess airway, breathing, and circulation according to standard cardiopulmonary life support protocol.
- In the event of central nervous system injury, expanding hematoma in the lateral pharyngeal space, damage to the tongue, palate, or floor of the mouth, or disruption of maxillomandibular stability, an endotracheal tube or tracheotomy may be needed for a secure airway.
- Hemostasis is needed for active bleeding. Wound compression will often suffice. Overt arterial bleeds require vessel ligation or cauterization. Large vessel injury is best addressed in the operative setting.
- Cervical spine injury must be considered present with all significant facial traumas until ruled out by radiographic studies. A cervical collar is mandatory in these instances.
- Underlying facial fractures should also be considered irrespective of the degree of soft tissue injury.

## **A. PERFORM COMPLETE HEAD AND NECK EXAM AT PRESENTATION**

### **1. Eyes**

All periocular injuries mandate an ophthalmology consultation to assess vision, ocular pressures, corneal integrity, the anterior and posterior chambers, the lacrimal system, and the retina.

- Assess vision and light perception, gross visual acuity, pupillary reflexes, and extraocular muscle function. Restricted mobility and subconjunctival hemorrhage are suggestive of orbital fractures. Blood in the anterior chamber (hyphema) is an ocular emergency.
- Assess lid function and structural integrity.

### **2. Ears**

Hemotympanum, canal lacerations, and Battle's sign are all indicative of temporal bone fracture.

- Examine for pinna and canal lacerations, for blood in the canal or the middle ear, and for auricular hematomas.
- If lacerations are present, determine the extent of cartilage involvement.

### **3. Nose**

- Examine lacerations and determine their depth, cartilage involvement, and any violation of the mucosal lining.
- Assess for stability of the nasal skeleton to include nasal bone and septal fractures.
- Examine the septum to rule out septal hematoma.

### **4. Mouth**

- Examine lips for evidence of laceration.
- Look for intraoral bleeding to uncover tongue or mucosal lacerations.
- Ensure the stability of the palate.
- Assess dentition for occlusion and dental fractures or tooth loss. These foreshadow maxillomandibular fractures, and missing teeth present a risk of airway blockage by a foreign body.

### **5. Neck**

- Examine for lacerations and even small wounds that could be considered puncture wounds. See Chapter 7 on the management of penetrating neck trauma.
- Examine for crepitus that may portend airway injury.

### **6. Scalp**

- Palpate hair-bearing scalp and examine it for evidence of bleeding where injuries may be concealed. Hematomas may also be present and require evacuation.

## CHAPTER 9: Soft Tissue Injuries of the Face, Head, and Neck

- If injury is identified, rule out an underlying cranial fracture.

### 7. Cranial Nerves

- A thorough cranial nerve exam is mandatory, particularly in cases of extensive soft tissue trauma. Like all many neurologic evaluations, though, this is difficult in the obtunded patient.
- Paresthesias are common even in contusions, but may help isolate underlying fractures in the maxillomandibular skeleton.
- Facial nerve status is of utmost importance as well. In cases of lacerations and penetrating injuries, nerve sectioning must be ruled out. Contusions and localized inflammation can lead to neuropraxia, but this typically presents in a delayed fashion. Documenting facial function early in the course of treatment can be invaluable for long-term prognosis—both in soft tissue trauma and in the management of temporal bone fractures.

## II. Diagnosis, Imaging Studies, and Laboratory Assessment

### A. DIAGNOSIS

Soft tissue injuries are essentially all identified by a thorough history and physical exam. The extent of injury, though, may be further characterized with the assistance of ancillary studies.

### B. IMAGING STUDIES

#### 1. Plain Film Radiographs

Plain film radiographs are primarily useful for evaluating cervical spine status. Typically initiated by the primary emergency medicine or trauma service, they have limited value for assessing most craniofacial traumatic injuries.

#### 2. Computed Tomography (CT)

- CT imaging of the face  $\leq 3$  millimeters (mm) cuts in both axial and coronal dimensions is adequate. Cuts of 1 mm or less are optimal, and provide opportunity for more accurate reconstructed coronal images of detailed 3-dimensional reconstructions if desired.
- CT provides excellent delineation of bony architecture.
- CT can demonstrate radiopaque foreign bodies that may be embedded in soft tissue.
- CT, in combination with contrast material, can delineate vascular structures.
- CT angiography is ideal for penetrating neck trauma if this modality is available.

- Subcutaneous emphysema, particular in the neck, provides insight for aerodigestive tract injuries.
- CT can characterize soft tissue fluid accumulation versus diffuse edema.

### **3. Magnetic Resonance Imaging and Ultrasonography**

There is a limited role, if any, for magnetic resonance imaging or ultrasonography in the management of acute soft tissue trauma.

## **C. LABORATORY ASSESSMENT**

### **1. Complete Blood Count**

A complete blood count can help evaluate blood volume from traumatic loss. However, acute measures may be deceptively normal if third space fluid volumes have not yet mobilized to the endovascular space.

### **2. Chemistries**

- Chemistries help denote overall fluid status and renal function, particularly in cases where general anesthesia may be necessary.
- Blood sugar may be reactively elevated in severe trauma, but dramatic elevations may also identify the closet diabetic patient. This factor is important in wound healing and infection risk.

### **3. Toxicology**

Toxicology should be used to identify elevated blood alcohol levels, the presence of narcotic drug use, and even the use of prescription medications that may impair the patient's sensorium and contribute to cardiovascular or neurologic side effects. Again, toxicology is important for the overall patient assessment and in cases that require anesthesia.

## **III. Surgical Decision-Making Principles**

### **A. TIMING OF WOUND REPAIR**

#### **1. Primary Closure**

Primary closure is ideal and should be accomplished within approximately 4-6 hours after wounding.

#### **2. Delayed Primary Closure**

Delayed primary closure is considered, with gross contamination deemed highly prone for infection (even after extensive debridement and copious irrigation).

- Here the wound is debrided, irrigated, packed, or cleansed over 24-72 hours, followed by a detailed closure, usually in the operating theater.
- Parenteral antibiotics are commonly employed with delayed closure.

## CHAPTER 9: Soft Tissue Injuries of the Face, Head, and Neck

### 3. Closure by Secondary Intent

Closure by secondary intent is permissible, wherein both patient (or surrogate) and surgeon participate in good wound care and allow for slow but steady closure of the defect. It should be considered in cases of uncontrolled diabetes, chronic hypoxia due to cardiopulmonary disease, or any other significant wound-healing deficit.

### 4. Adjunctive Therapies

Adjunctive therapies, such as the implementation of wound-healing factors or devices or the use of hyperbaric oxygen, may also be required.

### 5. Post-Healing

After the wound is healed, the scar can be dealt with appropriately.

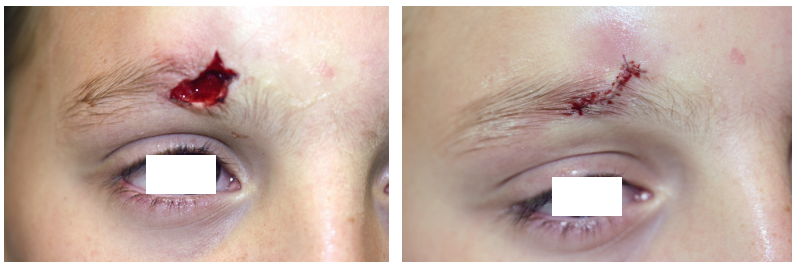
## B. ANESTHESIA CONSIDERATIONS

### 1. Localized Tissue Injuries

#### a. *Injectable Local Anesthesia*

Adults and children deemed sufficiently compliant can often undergo closure using injectable local anesthesia alone. The anesthesiologist should counsel parents or caretakers regarding the steps required, and give them factual information in an honest but empathetic manner.

Ideally, regional nerve blocks (i.e., infraorbital, mental, supratrochlear, and supraorbital) should be performed to achieve excellent wide-field anesthesia and minimize tissue distortion that results from subcutaneous permeation of significant fluid volume (Figure 9.1). Once the blocks have taken effect, local infiltration with a limited volume should be administered for targeted local anesthesia and hemostasis.<sup>1</sup>



**Figure 9.1**

A 10-year-old female with stellate right medial brow laceration. Supraorbital and supratrochlear blockade provides excellent anesthesia for wound irrigation and closure in the clinic setting. Closure must address realignment of the eyebrow.

If the procedure is likely to take longer than 1 to 1.5 hours, then 0.25 percent bupivacaine can be added to the 1 percent lidocaine to prolong its effect. Generally, epinephrine is not used in the local anesthetic for children.

Anesthetic solutions may be buffered with sodium bicarbonate (10 percent of the total volume of anesthetic) to reduce the discomfort of local wound infiltration.

#### ***b. Topical Anesthetics***

Topical anesthetics, such as EMLA® (eutectic mixture of local anesthetics) Cream (lidocaine 2.5 percent and prilocaine 2.5 percent) can also be applied to the area of planned local nerve block if sufficient time is allowed.

#### ***c. Pediatric Intensivists or Other Qualified Emergency Physicians***

Pediatric intensivists or other qualified emergency physicians can be invaluable to provide conscious sedation in the emergency department for children, where wounds are deemed unworthy for the operative theater and more limited sedation techniques are suspected to be unsuccessful.

#### ***d. Sedation***

Most adults will not require sedation for primary closure of a wound prior to its anesthetization. However, if anxiety is an issue, certain patients may benefit from parenteral sedation (diazepam) or an antianxiety/antiemetic medication (promethazine).

## **2. Extensive Injuries**

For injuries with significant tissue avulsion, when underlying osseous or neurovascular structures are injured or at risk, in polytrauma or life-threatening injuries, or in instances where conscious sedation for children is deemed either inappropriate or unavailable, intervention in the operating theater may be required (and humane).

## **C. IRRIGATION AND DEBRIDEMENT**

The mainstays of successful soft tissue wound management include irrigation and debridement, particularly in the case of human or animal penetrating wounds where copious irrigation is essential. Unfortunately, these steps can generate significant discomfort for the patient. For this reason, pretreatment local anesthesia is recommended whenever possible.

## CHAPTER 9: Soft Tissue Injuries of the Face, Head, and Neck

### 1. Microdebridement

- Accomplished with sterile saline, or tap water from a clean outlet should sterile saline be unavailable, to decrease the bacterial load in tissues.
- Although several liters of saline irrigation are adequate, a 2:1 solution of saline and povidone-iodine, usually in the volume of 1.5 liters is preferable.
- A surgical scrub brush is helpful for abrasions.
- For larger wounds, a bulb syringe or intravenous tubing irrigation will suffice.
- For smaller penetrations or puncture wounds, a plastic intravenous catheter on a 20-cubic-centimeter syringe works well.
- Commercial products like Pulsavac® (Zimmer) are available for simultaneous, aggressive lavage and microdebridement of wounds.

### 2. Macrodebridement

In cases of large particulate matter (e.g., glass or gravel) manual debridement is necessary.

- Again, pretreatment with local anesthesia is advocated.
- Prior to definitive closure, obviously devitalized soft tissue should be debrided. However, the extensive facial blood supply permits tissue survival, even in the setting of severe trauma. Therefore limited, rather than extensive, debridement of tissue deemed marginal should be attempted in most cases.

## D. FUNDAMENTALS OF WOUND CLOSURE

The surgeon must bring knowledge of suture materials, needles, and closure techniques, most of which are beyond the scope of this Resident Manual.

### 1. Prepare Wound

The surgeon must understand differences between permanent suture (e.g., nylon, polypropylene (Prolene™)) and resorbable suture (e.g., plain gut, chromic catgut, polyglactin (910 Vicryl™)), and between monofilaments (e.g., poliglecaprone (Monocryl™)) and polyfilaments (e.g., silk). Important characteristics include time of retained tensile strength and time to resorption. Of particular importance for traumatic repairs, recognize the relative increased risks of infection with polyfilament materials secondary to bacteria harboring between individual filament fibers.

### 2. Close Tissues

Following wound preparation, close tissues in a meticulous layered fashion to include periosteum, muscle, subcutaneous tissue, and skin or mucosa, as involved.



**a. Deep-Tissue Alignment and Reapproximation**

- Align and reapproximate deeper tissues (muscle, fascia) to abolish dead space and relieve wound tension.
- Use 3-0 or 4-0 resorbable suture (e.g., Monocryl™, Vicryl™). Using undyed or clear suture will prevent surface visibility.
- Place sutures in a simple, interrupted, inverted fashion with a buried knot.

**b. Dermis Closure**

- Close dermis with 4-0 or 5-0 resorbable suture (i.e., Vicryl™ or chromic) in a similar inverted, interrupted fashion, thereby burying the knot.
- Pay particular attention to needle entry and exit points in the dermis to precisely realign skin edges.
- Work to avoid height discrepancies on either side of the wound.

**c. Skin Closure**

Skin closure may be undertaken with 5-0 or 6-0 either absorbable (i.e., fast-absorbing gut) or permanent (i.e., nylon or Prolene™) suture. In patients for whom follow-up is questioned or in children where compliance with removal is often limited, absorbable material is frequently chosen.

**d. Shallow Lacerations**

If skin edges are precisely approximated under no tension, wound adhesives, such as a topical skin adhesive like 2-octyl-cyanoacrylate (Dermabond®), may also be applied for small, shallow lacerations.

**e. Suture Options**

- In general, sutures in the face and neck should be placed ~2 mm from the skin edge and 3 mm between each suture as to provide good eversion and avoid resultant depressed scarring.
- If skin eversion is difficult, intermittent placement of vertical mattress sutures is an excellent option.
- Typically, closure is accomplished with either simple interrupted or running (locked or unlocked) sutures, with some debate existing between these options. A running-locked stitch provides excellent eversion of the skin edge and favorable cosmesis. Careful attention must be paid to avoid strangulation of the skin edges. If lacerations are significantly jagged making alignment more difficult, simple interrupted sutures are ideal. Additionally, where concern for infection is high, one may defer to interrupted sutures, so as to allow for individual removal to provide drainage if infection does ensue, rather than reopening the entire wound with resultant poorer cosmesis.

## CHAPTER 9: Soft Tissue Injuries of the Face, Head, and Neck

- Close mucosal surfaces with 4-0 or 5-0 resorbable suture (i.e., chromic gut or Vicryl™), with simple interrupted, running, or run-locking stitches.

### **f. Drains and Dressings**

If a large dead space exists, or if an avulsed flap is replaced, it may be necessary to place a small drain, with or without suction. Should suction not be utilized, place the drain exit near the most dependent portion of the wound if possible. A compressive dressing may also be utilized for such injuries.

### **g. Undermining and Debridement**

Occasionally, undermining with a scalpel or sharp tissue scissors in the subdermal plane may be warranted, along with debridement, if necessary. This may aid in freshening the skin edges and facilitate skin eversion. This is particularly true in cases of beveled or scythed wounds, or when the wound has been open for an extended period and has begun to dry. In such cases, the wound edges begin to retract and round themselves, and thicken from resulting edema.

### **3. Avoid Undertaking Local Flaps in the “Primary” Setting**

Finally, any thought to undertaking local flaps in the “primary” setting should be abolished with very limited exceptions. Excision or significant rearrangement of potentially viable tissue may preclude further options later, once injuries have “declared” themselves and final reconstruction is attempted.

## **IV. Informed Consent**

As with any emergency, there are instances where consent is implied and treatment may commence without discussing all aspects of soft tissue repair with the patient. However, every attempt should be made to keep patients and their families informed throughout the process.

Remain honest, yet judicious, in disclosing potential outcomes. Set appropriate expectations for present and future care, while also acknowledging the stress of traumatic events. In cases where patients and families are overwhelmed and unable to discuss or comprehend the breadth of care required, focus their attention on the immediate situation.

Consent should involve discussion of the planned repair itself, but also of the potential complications and future outcomes. These include (but are not limited to) infection, wound breakdown and tissue loss, scarring,

functional deficits specific to the site of injury, unacceptable cosmetic appearance, and the need for additional revision or adjunctive procedures.

It is particularly important to keep parents informed of every step in the treatment process of their child.

## **V. Operative Management by Location**

Comprehensive reconstruction techniques for the facial subsites listed below are beyond the scope of this Resident Manual. In some cases, the principles discussed may serve as temporizing maneuvers until definitive reconstruction is undertaken at a later time.

### **A. SCALP**

Scalp tissue is thicker than one might expect and unforgiving in extensibility.

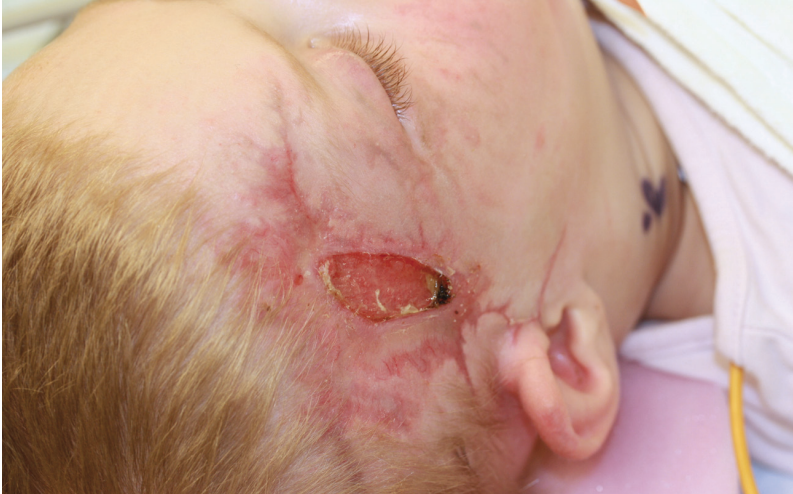- Assess for underlying bony fractures.
- Attempt to cover all exposed bone. If periosteum is missing, and closure not possible, healing by second intent is greatly impaired and may lead to desiccated calvarial bone exposure.
- If closure is unable to cover bone, cover with a nonadherent dressing using an antibiotic ointment for moisture interface.
- Close wounds in layered fashion, with particular attention to closure of the galea aponeurosis. The galea has a robust vascular supply, and closure will reduce tension on the overlying cutaneous tissues.
- Close small wounds with chromic or fast-absorbing polyglactin 910 (Vicryl Rapide™) suture.
- Close larger wounds with surgical staples, which facilitate both the speed of closure and the ease of removal in the hair-bearing scalp.
- Place a passive (Penrose) drain under large, undermined scalp flaps to aid in the egress of serosanguinous fluid, prevent hematoma formation, and eliminate dead space.
- Place compressive head wraps at least for 24–48 hours, until underlying tissues reanneal.

### **B. FOREHEAD**

- Assess wounds for possible underlying frontal sinus fracture.
- Supratrochlear and supraorbital blocks facilitate wide-field anesthesia.
- Close wounds in standard fashion, with attention to alignment of rhytids, the trichion, and brow margins.

## CHAPTER 9: Soft Tissue Injuries of the Face, Head, and Neck

- In the event of tissue loss or undue wound tension, open wounds of both the forehead and the temple heal well by second intention (Figure 9.2).



**Figure 9.2**

A 2-year-old ejected from motor vehicle. Large surface area of right temple and forehead with soft tissue loss and inadequate tissue volume for primary closure. Temporalis fascia and muscle provide excellent wound bed for healing by second intent. Once the wound is healed and free of infection, further scar revision, tissue expansion, and/or grafting can be done in a controlled setting.

### C. AURICLE

Appropriate wound closure requires knowledge of both the topographical anatomy of the pinna and cartilage's dependency on its perichondrial blood supply.

#### 1. Superficial Lacerations

Superficial lacerations can be closed primarily with skin-only sutures. The absence of subcutaneous tissue on the lateral surface and the adherence of tissue to the cartilage framework make subdermal sutures impractical and unnecessary.

#### 2. Cartilage Lacerations

Cartilage lacerations should be reapproximated with monofilament, resorbable suture. Monocryl™ is an ideal material.

Auricular cartilage is brittle and prone to fracture. Reverse cutting needles should be used to ensure clean entry and exit from the

cartilage, and to prevent back-fracture of the cartilage as the surgeon sews toward himself or herself.

### **3. Approximation of the Helix and Antihelix**

Meticulous approximation of the helix and antihelix is necessary to maintain structural and cosmetic integrity of the underlying framework. This will help prevent an acquired auricular deformity.

### **4. Lacerations Involving the Free Edges of the Pinna**

Lacerations involving the free edges of the pinna (i.e., helix, lobule) require accentuated skin eversion with mattress sutures. This will help prevent notching that may occur from scar contracture and depression during the healing process (Figure 9.3).

### **5. Hematomas and Seromas**

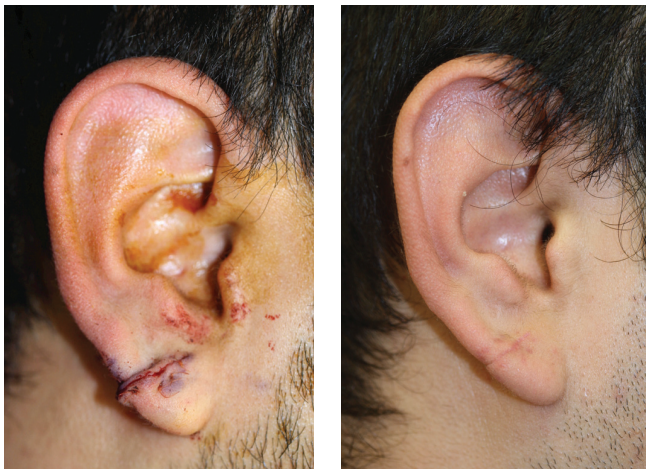Hematomas and seromas require evacuation.

### **6. Perichondrial Coaptation to the Cartilage Framework**

Plain gut sutures, chromic quilting sutures, or bolster dressings aid in perichondrial coaptation to the cartilage framework and eliminate dead space. This is crucial to maintain cartilage viability and prevent cauliflower ear or pseudocyst deformities.

### **7. Segmental Avulsion of the Pinna**

For segmental avulsion of the pinna, the cartilage skeleton should be deperithelialized and thoroughly cleansed to minimize bacterial load.



**Figure 9.3**

Right ear laceration closed primarily. Vertical mattress sutures used to provide accentuated skin eversion. With scar maturation and retraction, incision line flattens without significant notching of the rim.

## CHAPTER 9: Soft Tissue Injuries of the Face, Head, and Neck

### 8. Cartilage Banking

Cartilage is then banked in a subfascial or submuscular pocket over the mastoid or temporoparietal scalp. Consider banking on the contralateral side if possible to ensure adequate blood supply and distance the tissue from possible local infection. This will also minimize incisions and temporoparietal fascia violation that may be needed at the time of staged reconstruction.

### 9. Total and Near-Total Auricular Avulsion

For total and near-total auricular avulsion, microvascular reanastomosis is advocated but depends on surgical experience and resources available.

## D. PERIORBITA

### 1. Ophthalmology Consultation

Emphasis must be on preservation of vision and the integrity of the ocular structures. Therefore, all periocular injuries obligate an ophthalmology consultation.

### 2. Irrigation

If ocular debris or chemical exposure is suspected, copious irrigation is mandatory.

### 3. Delayed Closure in Operating Room

Depending on the experience of the surgeon and resources available, delay in closure may be warranted to allow for experienced assistance and specialized instrumentation. In this case, closure in the operating room is ideal. Tarsorrhaphy, Frost sutures with bolsters, or an eye patch may be necessary to provide temporary protection of the cornea and globe. Remember to apply moisture in the form of basic salt solution or ophthalmic lubricating or antibiotic ointment. Use corneal protectors if necessary.

### 4. Lid Laceration

In the event of lid laceration, repair each lamella independently.

### 5. Posterior Lamella Lacerations

Posterior lamella lacerations may only require tarsal plate repair. Use soft, resorbable suture, like Vicryl™. Place knots superficially. Deep, inverted knots, even if covered by palpebral conjunctiva, often lead to corneal irritation and even abrasion during the blink mechanism.

## 6. Anterior Lamella Lacerations

Anterior lamella lacerations typically only require skin repair. The orbicularis oculi fibers are densely adherent to the skin and will passively approximate with skin closure. Deep sutures tend to accentuate intramuscular scarring and increase risk of lid malposition, retraction, and ectropion.

## 7. Lacrimal Canalicular Injury

Lacrimal canalicular injury may require cannulation with repair or Crawford tube placement. This is best done in the operative setting and with ophthalmologic surgical guidance.

## 8. Canthal Injuries

- Medial canthal tendon avulsion and canthi laceration may denote naso-orbital-ethmoid fracture. See Chapter 3 for repair techniques.
- Lateral canthal repair must ensure resuspension of the canthal tendon to periosteum, approximating Whitnall's tubercle and canthoplasty with "gray line" approximation.

## 9. Closure at the Lid Margin

Closure at the lid margin should be done with eversion of the skin edges to help prevent notching.

## 10. Lid Margin and Proximal Anterior Lamella Sutures

All lid margin and proximal anterior lamella sutures should be cut with longer tails draped away from the lid margin. This helps prevent corneal irritation and abrasion. Tails can be secured with distally placed sutures or Mastisol® (Ferndale) skin adhesive and Steri-Strip™ dressings.

## 11. Superior Lid Lacerations

In superior lid lacerations, particularly horizontal injuries, assessment of levator palpebrae superioris function is crucial. Muscle or aponeurosis separation from the superior tarsus will lead to traumatic ptosis. Reattachment can be established, depending on surgical skill and tissue quality. If bruising, edema, muscle contraction back into the orbit, or inexperience makes appropriate repair unlikely, the laceration should be repaired in a delayed setting in the operative theatre with ophthalmology assistance.

## 12. Visible Orbital Fat

If orbital fat is visible within the wound, the orbital septum has been violated. This, too, is reason for further evaluation and repair in the operative setting.



## CHAPTER 9: Soft Tissue Injuries of the Face, Head, and Neck

### E. NOSE

#### 1. Nasal Soft Tissue Injuries

Nasal soft tissue injuries require closure in three layers.

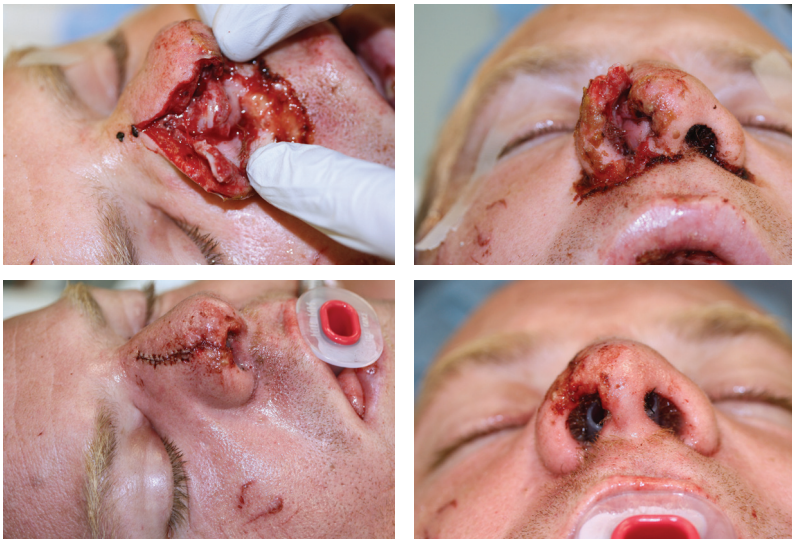- Endonasal mucosa should be reapproximated if at all possible as a first step.
- Alar cartilage lacerations should be reapproximated with 6-0 permanent, monofilament suture.
- Alar rim and columellar lacerations require eversion of the skin margins to help prevent retraction and notching during scar maturation.

#### 2. Extensive Nasal Vestibule Injuries

For extensive vestibular injuries, soft silicone stents with mupirocin ointment should be placed to help maintain vestibular patency during the healing process. These are affixed to the caudal septal with a nonresorbable monofilament stitch (Figure 9.4).

#### 3. Septal Hematomas

Septal hematomas require emergent evacuation. The mucoperichondrium is coapted to the septal cartilage using plain gut or Vicryl Rapide™ quilting mattress sutures.



**Figure 9.4**

Through-and-through laceration of the right nasal soft tissue. Endonasal mucosa reapproximated followed by realignment of the alar cartilage using 6-0 Prolene. Skin closure with 6-0 fast-absorbing gut suture. Septal fracture reduced, vestibular margin at the soft tissue facet closed, and silicone Doyle splints placed.



#### 4. Severe Septal Mucosal Lacerations or Hematomas

In cases of severe septal mucosal lacerations or hematomas, septal splints are advocated. Prefabricated Doyle splints and hand-cut silicone sheets are both viable options.

#### 5. Extensive Soft Tissue Undermining

If extensive soft tissue undermining has occurred and/or the threat of subcutaneous dead space exists, the soft tissue envelope should be taped and dressed in a post-rhinoplasty fashion.

### F. LIPS

#### 1. Wound Examination

Examine for underlying fractures, loose dentition, malocclusion, or other oral cavity injury.

#### 2. Wound Closure

Close wounds in multiple layers.

##### **a. Mucosa**

Close mucosa with resorbable sutures (i.e., chromic, Vicryl™, Vicryl Rapide™).

##### **b. Orbicularis Oris Muscle**

Reapproximate laceration of the orbicularis oris muscle as a separate, central layer. In our opinion, polydioxanone suture material is the preferred option. The monofilament glides through muscle without tearing, minimizes scar formation, and provides a longer-lasting, strong, yet resorbable option for muscle repair.

##### **c. Red and White Lips**

Red and white lips should be closed as independent subsites. Red lip should be closed with chromic or Vicryl™ sutures, with attention to realignment of the “dry line”—the interface between the wet and dry red lip.

#### 3. Reapproximation of Landmarks

##### **a. Vermillion Border**

The vermillion border is an important aesthetic boundary. Great care should be taken to reapproximate this line. A simple, precise, single 6-0 suture should be placed squarely at this line. Some surgeons advocate using silk suture material here, because of its soft quality and favorable “lie.” However, fast-absorbing gut suture material is equally effective at this site, particularly in children where suture removal itself may be traumatic.

## CHAPTER 9: Soft Tissue Injuries of the Face, Head, and Neck

### **b. Other Landmarks**

Other landmarks should similarly be reapproximated, including the white roll, the philtral ridges, Cupid's bow, and the mental crease.

### **G. CHEEKS**

- Examine cheek wounds for possible intraoral communication.
- Note proximity to the course of the parotid duct and major facial nerve branches.
- If blood is seen at Stenson's orifice, or the depth and location of the wound place the parotid duct at risk, gently cannulate the duct with a lacrimal probe. Overt duct transection, if identified, should be repaired in the operative setting.
- Duct injury signifies higher likelihood of facial nerve injury, particularly in the buccal distribution.
- For lacerations medial to the lateral canthi with facial nerve paralysis, identifying nerve branches for primary anastomosis is highly unlikely.

### **H. CHIN**

- Examine chin injuries for intraoral communication and for anterior fractures or loose teeth.
- Significant auditory meatal trauma should raise suspicion for possible subcondylar mandible fracture.

### **I. NECK**

- Consider all neck wounds as penetrating, until proven otherwise. See Chapter 7 for further information on penetrating neck trauma.
- If wounds are superficial, layered closure with reapproximation of the platysma helps to relieve wound tension and ensure adequate blood supply to the overlying skin.
- Place passive drains for large areas of dead space or grossly contaminated wounds. Fluid accumulation may not only promote infection and wound breakdown, but can threaten the airway if it continues to propagate (Figure 9.5).

## **VI. Perioperative Care**

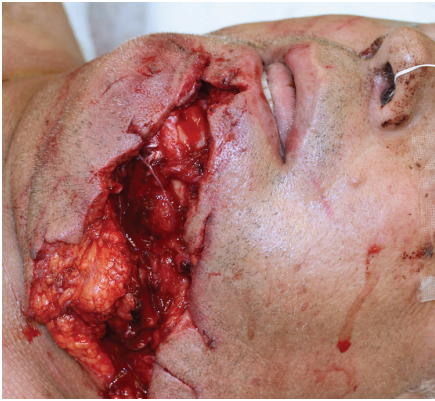### **A. ANTIBIOTIC PROPHYLAXIS**

#### **1. Uncontaminated Wounds <24 Hours Mature**

- Clean.
- Do not use antibiotic prophylaxis.

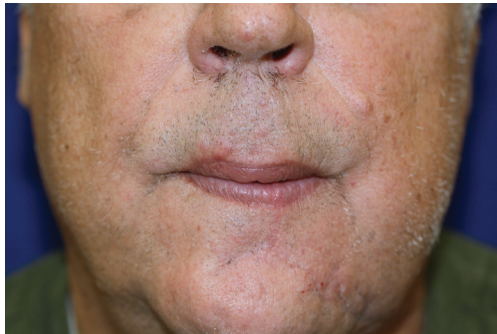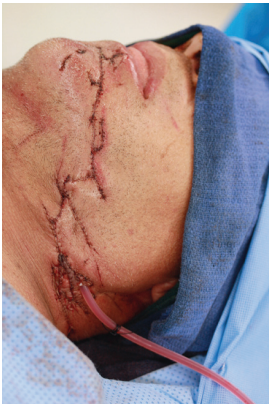#### **2. Contaminated Wounds or Wounds >24 Hours Mature**

- Use first-generation cephalosporins (cephalexin, cefadroxy) or amoxicillin + clavulanate (Augmentin®).



**Figure 9.5**

Tearing and avulsive injury of left neck, chin, and lip following ejection through windshield. Tissues reapproximated in multiple layers, but unable to affix avulsed tissues back to mandible. Lip closed with specific attention to vermillion closure, and Jackson-Pratt drain placed to evacuate large dead space from neck Levels I and II.



- Consider clindamycin or trimethoprim-sulfamethoxazole (Bactrim™) if the patient is allergic to penicillin derivatives.

### 3. Oronasal-Involved Wounds (i.e., through-and-through lip lacerations)

- Clindamycin is typically used as a first-line treatment.
- Consider amoxicillin + clavulanate (Augmentin®), as well as a second- or third-generation cephalosporin (cefuroxime, ceftriaxone).

### 4. Ear or Nasal Cartilage Involvement

- Fluoroquinolones (ciprofloxacin, ofloxacin) provide good antipseudomonal coverage and excellent cartilage penetration.

### 5. Animal Bites

Some debate exists concerning the need for antibiotic prophylaxis. In general, consider in more complicated cases, such as immunocompromised victims, or in more extensive wounding.

## CHAPTER 9: Soft Tissue Injuries of the Face, Head, and Neck

- Use amoxicillin + clavulanate (Augmentin®) as a first-line treatment.
- If the patient is allergic to penicillin derivatives, consider:
  - In adults, a tetracycline (e.g., doxycycline), or combination therapy with clindamycin and a fluoroquinolone.
  - In children, a macrolide (e.g., erythromycin) or combination therapy with trimethoprim + sulfamethoxazole (Bactrim™) and clindamycin.

### 6. Human Bites

- Use antibiotic prophylaxis if wounding is deeper than the epidermis, as human flora contains an abundance of bacterial pathogens.
- Cover *Eikenella corrodens* (not covered typically by first-generation cephalosporin or clindamycin alone).
- Use amoxicillin + clavulanate (Augmentin®), as a first-line treatment.
- If the patient is allergic to penicillin derivatives, consider combination therapy with clindamycin plus trimethoprim + sulfamethoxazole (Bactrim™), or a fluoroquinolone therapy with clindamycin plus trimethoprim + sulfamethoxazole (Bactrim™), or a fluoroquinolone (e.g., ciprofloxacin).

### B. PROS AND CONS OF TOPICAL ANTIBIOTICS

Numerous alternatives exist to include various combinations, such as bacitracin, neomycin, polymyxin B (Neosporin®), bacitracin + polymyxin B (Polysporin™), or triple antibiotic ointment. These topical antibiotics allow for high drug concentrations at the site of injury, while limiting systemic toxicity. They also increase moisturization, and thus improve the rate of reepithelization.

Strong data clearly delineating reduction in infection rates are lacking for continued utilization beyond clinical closure of the epithelium. Once superficial wound healing is complete (24–48 hours), there is minimal penetration into deeper tissues that would actually prevent cellulitic infection.

#### 1. Neomycin

- Active against most gram-negative bacteria and a few gram-positive bacteria, but inactive against anaerobes as well as streptococci.
- Cost-effective.
- High likelihood of contact dermatitis (some reports indicate ~15 percent of patients).

#### 2. Bacitracin

- Most effective against gram-positive bacteria, not to include methicillin-resistant *Staphylococcus aureus* (MRSA).

- Cost-effective.
- Low reactive potential.

### 3. Mupirocin (e.g., Bactroban®)

- Provides excellent activity against gram-positive Staph and Strep species, to include MRSA as well as *Staphylococcus pyogenes*.
- Found in one study to have an effect equal to that of oral cephalixin in treatment of secondarily infected minor wounds.<sup>2</sup>
- Poor cost profile.
- Low reactive potential.

## C. TETANUS PROPHYLAXIS

Table 9.1 presents recommendations for preventing tetanus in patients under three different scenarios.

**Table 9.1. Recommended Tetanus Prophylaxis under Different Scenarios**

Scenarios	Recommended Tetanus Prophylaxis
<7 years of age, or >5 years since last tetanus vaccination	Use tetanus-diphtheria toxoid (Td) or the diphtheria, tetanus, and pertussis (DTP) vaccine.
Unknown vaccination history or <3 vaccinations in the tetanus series	Apply tetanus immune globulin (TIG) 250–500 units intramuscular. Give Td to these patients and to patients who have not been vaccinated in more than 10 years.
Minor, low-risk wounds	TIG vaccination is unnecessary for minor wounds, where risk of tetanus infection is extremely low.

## D. POST-REPAIR DIRECTIVES

Various strategies to prevent infection and promote wound healing and cosmesis exist following closure of soft tissue wounds.

### 1. Moisturization

As moisturization has been shown to improve the rate of wound re-epithelization, antibiotic ointments or petroleum-based jelly should be applied until sutures are removed or resorbed. Although definitive data demonstrating lower infection rates with antibiotic-containing options are lacking, application of bacitracin- or mupirocin-based ointments for the first 5–7 days is recommended. Petroleum jelly may be used thereafter.

### 2. Daily Debridement

Along incision lines, daily debridement of crust formation with dilute, half-strength hydrogen peroxide via cotton tip applicator should be implemented.

## CHAPTER 9: Soft Tissue Injuries of the Face, Head, and Neck

### 3. Dressings

While nonadherent dressings may assist with moisturization and provide a barrier for additional contamination during the initial days following closure, more limited injuries where meticulous wound care is anticipated may be left uncovered.

In instances of large avulsion injuries or where significant dead space may be present, compressive dressings should be considered.

### 4. Bathing

While patients should be instructed to avoid soaking in a bathtub or pool for at least 10–14 days (or until all wounds have epithelialized), showering with gentle soap and water is encouraged after 24–48 hours.

### 5. Antibiotics

For grossly contaminated wounds, parenteral or oral antibiotic prophylaxis is routinely implemented; however, with minor and reasonably clean wounds, antibiotic use may be declined.

### 6. Nutrition

Adequate nutrition—often a challenge in polytrauma or burn patients, specifically—remains critical.

### 7. Head Elevation

Elevation of the head may alleviate swelling.

### 8. Patient and Caretaker Instructions

Signs and symptoms that may indicate developing infection should always be explained at great length to patients and caretakers (assistance with handouts is encouraged in this regard).

### 9. Suture Removal

Suture removal is generally considered after 5–7 days on the face and 7–10 days on the neck or scalp. Staples placed in the scalp should be removed after 10–14 days.

### 10. Hypertrophic Scarring and Hyperemia

Hypertrophic scarring and hyperemia are more likely to occur with traumatic injuries, especially in children, and can be lessened by application of silicone gel applied twice daily for up to 2 months after initial wound healing. Initiate this therapy 2–4 weeks after repair, depending on healing.

## VII. Special Circumstances

### A. ABRASIONS

- Ensure that wounds are thoroughly cleansed and debrided.
- Remove foreign material, especially dark particulate matter, while wounds are open if possible, as it will lead to dermal tattooing.
- Keep wounds moist with antibiotic ointments, and later petroleum jelly, to promote epithelial migration and healing.

### B. AVULSION INJURIES

Avulsion injuries typically involve soft tissue appendages that are focally anchored to the craniofacial skeleton. Tissue viability must be assessed based on the mechanism of injury (i.e., blunt versus shearing or laceration), ischemic time since injury, and method of preservation and transport of the tissue. See the auricle discussion under section V.C, above.

### C. FACIAL NERVE INJURIES

- Physical examination must assess facial nerve status at the time of presentation.
- For blunt injuries that present with facial nerve paresis or paralysis, see Chapter 6 for management of temporal bone trauma.
- For penetrating soft tissue injuries with nerve paresis, close observation and the use of diagnostic testing, such as nerve excitability and conduction tests, are warranted.
- For penetrating injuries with facial nerve paralysis in the distribution of the soft tissue trauma, nerve exploration is required.
- Within 72 hours of injury, a nerve stimulator may assist in identification of the distal segment prior to Wallerian degeneration.
- Anastomosis of the proximal and distal segments is performed with tension-free, epineurial repair using microscopic assistance.
- If the segments are identified, but intervening tissue is lost, an interposition nerve graft will be needed. Great auricular and sural nerves are the donors of choice.

### D. BITE INJURIES

All bites should be considered contaminated wounds. Teeth from the animal or human attacker are always a potential foreign body in any bite wound. Bite injuries typically only involve soft tissue. However, the force imparted in the bite may lead to bony trauma as well.

For small punctate penetrating wounds, it is preferable to excise the puncture tract with a 2-, 3-, or 4-mm dermatologic punch, thereby removing damaged and contaminated tissue. This clean, cylindrical

## CHAPTER 9: Soft Tissue Injuries of the Face, Head, and Neck

wound can then be irrigated and loosely closed with one or two dermal sutures after instillation of antibiotic ointment, preferably mupirocin, within its depth.

Tissue flaps and associated wounds should be minimally debrided and copiously irrigated. Surrounding tissue may be slightly elevated to facilitate dermal closure with rather loosely placed 4-0 or 5-0 chromic catgut suture (or polyglactin suture if some tension exists). Loosely placed epidermal sutures of 6-0 polypropylene or 5-0 fast-absorbing catgut (in children) then complete the repair.

### 1. Animal Bites

#### a. Dog and Cat Bites

Dog bites are most common. They yield puncture wounds, and more commonly, lacerations. Infected dog and cat bites are likely to be populated by *Pasteurella multocida*, *Staphylococcus aureus*, and *Streptococcus viridans*. Cat bites are exceedingly more likely than dog bites to become infected (80 percent versus <5 percent).

#### b. Rabies Virus Transmission

Animal bites pose the risk of rabies virus transmission. If rabies is a possibility, the patient should receive a first dose of immune globulin on the day of the injury, followed by the vaccine at days 0, 3, 7, 14, and 28. Because povidone-iodine is a known virocidal and can eliminate 90 percent of the rabies risk, the wound should be irrigated and cleansed with this agent as well.

### 2. Human Bites

Human bites are less common than animal bites. Human bites are less likely to penetrate deeply into facial tissue than animal bites, owing to the length and shape of the anterior human teeth.

#### a. Primary Closure and Open Packing

Primary closure is selected only in the most favorable of wounds. Human bites deemed not safe for primary closure may be packed open with frequent dressing changes and application of topical antimicrobials, then closed in a delayed fashion 2–4 days after wounding (if clean) or left to heal by second intention. The latter will likely require subsequent scar revision.

#### b. Broad-Spectrum Antibiotics

A polymicrobial population, including anaerobic and aerobic organisms, contaminates most human bites. Thus, it is common to utilize broad-spectrum antibiotics with excellent anaerobic and microaerophilic efficacy.



- Human bites are typically complicated by *Eikenella corrodens* or *Bacteroides* sp.
- Typically, patients may be discharged with a broad-spectrum oral antibiotic with anaerobic coverage. Good choices include amoxicillin-clavulanate, clindamycin, and ciprofloxacin.
- Mupirocin® ointment can be applied topically to the wound and utilized for approximately 1 week post-repair.

#### **c. Testing for Communicable Diseases**

Human bites may transfer hepatitis B and C, herpes virus, and human immunodeficiency virus (HIV). It is good practice to treat a human bite as a possible HIV exposure. An HIV test should be performed on both patient and attacker, if possible. Eliciting a history of other communicable diseases in both patient and attacker is also prudent.

#### **d. Scar Revision**

Recipients of human bites should be made aware of probable less than ideal wound healing, and probable need for scar revision.

#### **e. Intravenous Bolus of a Second-Generation Cephalosporin**

An intravenous bolus of a second-generation cephalosporin (cefuroxime, ceftiofloxacin) should be administered for all penetrating soft tissue bite wounds. If penicillin sensitivity cross-reaction is a major concern with a cephalosporin, then parenteral ciprofloxacin is a good choice. Alternatively, clindamycin may be considered.

#### **f. Parenteral Antibiotic Therapy**

If wounds are severe, consider continued parenteral antibiotic therapy, either as inpatient treatment or home intravenous therapy.

#### **g. Adhesive Dressings**

Bite wounds should not be concealed by adhesive dressings, as it is important to observe the wound for infection and allow slight laxity of the wound margins for seepage of serous fluid.

### **E. BURN INJURIES**

Burn injuries may result from thermal injury, ingestion of caustic agents, and electrical shock. When they occur, they are more commonly seen in the pediatric population. Burn injuries tend to propagate beyond the focus of the insult, and damage may escalate for some time after the traumatic event. Management is complex and ongoing over time. However, some tenets must be followed early on in the emergency setting.

## CHAPTER 9: Soft Tissue Injuries of the Face, Head, and Neck

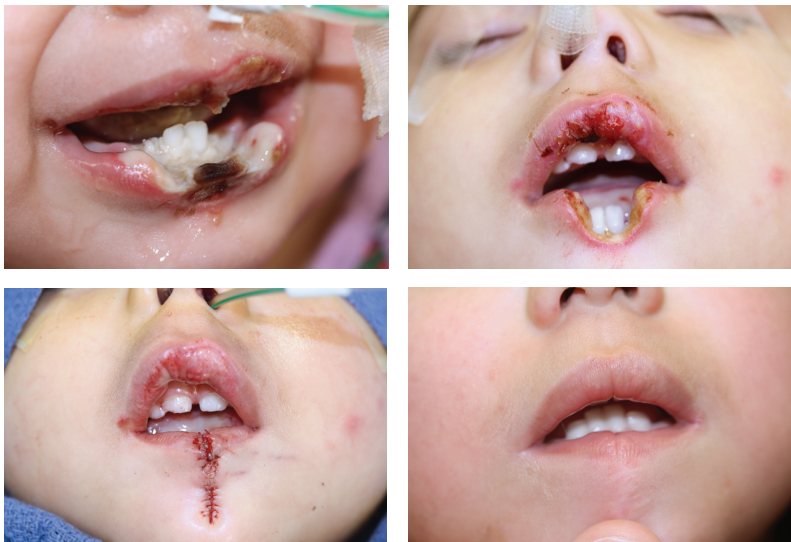- Ensure a secure airway. Keep in mind that swelling and subsequent airway compromise may present in a delayed fashion.
- The breadth of wounding will present in a delayed fashion. Therefore, do not remove, or repair, tissue acutely until all wound margins have declared themselves in the days following the injury (Figure 9.6).
- For thermal and electrical injuries, use soft tissue cooling to minimize perpetual tissue injury.
- When caustic or chemical agents are suspected, copiously irrigate wounds to dilute the offending agent.
- Administer antibiotics to cover skin flora and pseudomonal species.
- Keep wounds moist at all times.

### 1. Facial Subsites

Many facial subsites, including the external auditory canal, eyelids, nares, and mouth, are at great risk for retraction, contraction, and stenosis. Definitive management cannot begin until tissue viability has been declared, and may require skin grafting, local soft tissue rearrangements, stents, or other adjunctive procedures and devices.

#### Figure 9.6

A 2-year-old who bit into a refrigerator electric cord. Suffered third-degree burn with vaporization of central lower lip tissues and first-degree burns to upper lip, gingiva, and anterior tongue. Wound managed conservatively to allow demarcation of tissue viability. Minimal tissue debridement performed and lip closed on post-injury day 7.



## VIII. Conclusion

The proper initial and subsequent management of soft tissue trauma to the face, head, and neck can have far-reaching consequences for the appearance, function, and quality of life of the injured individual. Because of the importance of this region of the body, especially the face, in our daily lives, it is a *prima facie* responsibility of the otolaryngologist-head and neck surgeon to perform the most meticulous reconstruction of these injuries. Proper attention to careful and gentle tissue handling, minimal debridement of important facial tissue, repair of neurovascular and ductal structures, and reduction of infection and scarring will all benefit the patient's ultimate result. This is particularly true in children, where the stigmata of facial abnormalities will be borne by them during the formative development of their self-esteem.

Most soft tissue injuries to the face, head, and neck will require secondary interventions to produce the best result, and the patient and/or patient's family should be apprised of this likelihood early in the acute management phase, followed by the development of a comprehensive plan for reconstruction that will inform them of the potential outcome, including residual sequelae and possible disabilities. The surgeon must relate to the patient and family in a caring and honest manner, developing the important relationship that should last through the possibility of years of secondary reconstructive procedures. Following the fundamentals presented in this chapter, and seeking additional information from other educational and clinical sources, the resident physician in otolaryngology-head and neck surgery will be well prepared to care for a wide range of traumatic injuries to the face, head, and neck.

## IX. References

1. Zide BM, Swift R. How to block and tackle the face. *Plastic & Reconstructive Surgery*. 1998;101(3):840-851.
2. Kraus SJ, Eron LJ, Bottenfield GW, Drehobl MA, Bushnell WD, Cupo MA. Mupirocin cream is as effective as oral cephalexin in the treatment of secondarily infected wounds. *J Fam Pract*. Dec 1998;47:429-433.

# Chapter 10: Foreign Bodies and Caustic Ingestion

Whitney A. Pafford, MD

## I. Anatomy

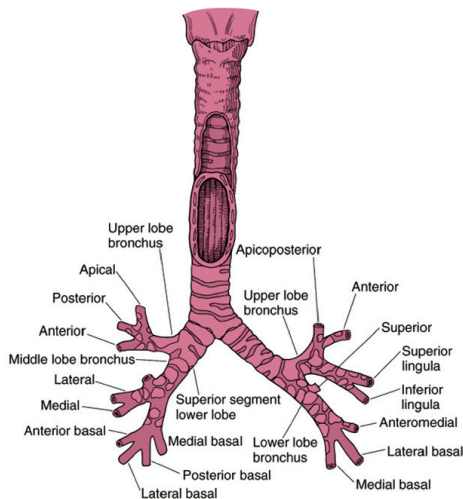
### A. UPPER AIRWAY

Foreign body aspiration and caustic ingestion can be life-threatening emergencies. Rapid recognition, work-up, and treatment reduce the risk of complications and associated morbidity and mortality. Given the importance of endoscopy in these patients, a general understanding of the upper aerodigestive anatomy is critical in their management.

- Nares.
- Nasopharynx.
- Oral cavity.
- Oropharynx.
- Larynx.

### B. LOWER AIRWAY

The trachea begins immediately inferior to the cricoid cartilage. It bifurcates into the right and left mainstem bronchi (Figure 10.1).



**Figure 10.1**

Tracheobronchial anatomy. Source: Myers and Carreau, Figure 67-1.

### **1. Right Main Bronchus**

The right main bronchus is shorter, wider, and more vertical than the left. It divides into three lobar bronchi and 10 segmental bronchi: three in the superior lobe, two in the middle lobe, and five in the inferior lobe.

### **2. Left Main Bronchus**

The left main bronchus divides into two lobar bronchi and eight segmental bronchi: four in the superior lobe and four in the inferior lobe. Anatomic variations may be present.

## **C. ALIMENTARY TRACT**

### **1. Hypopharynx**

The hypopharynx begins at the level of the hyoid bone. It is divided into the pyriform sinuses, the postcricoid region, and the posterior pharyngeal wall.

### **2. Esophagus**

In adults the esophagus starts at the level of the cricopharyngeus or the upper esophageal sphincter, and ends at the lower esophageal sphincter. It is approximately 22 centimeters (cm) long and has three points of anatomic constriction: (1) the cricopharyngeal sphincter (16 cm from incisors), (2) the left main stem bronchus (27 cm from the incisors), and (3) the gastroesophageal junction (38 cm from the incisors). The cricopharyngeal sphincter is the narrowest point and is at highest risk of injury or perforation.

### **3. Stomach**

The stomach is divided into the cardia, fundus, body, and pylorus. The cardiac notch is the acute angle between the intra-abdominal esophagus and the gastric fundus.

## **II. Foreign Bodies**

Although the incidence of aerodigestive foreign bodies has remained stable, its recognition and safety in removal have increased dramatically. The majority of foreign bodies are esophageal in both children and adults. Airway foreign bodies are more likely to occur in children. A higher incidence is found in children due to lack of molars, less controlled coordination of swallowing, immaturity in laryngeal elevation and glottic closure, and their tendency to explore their environment by putting things in their mouth.

## CHAPTER 10: Foreign Bodies and Caustic Ingestion

### A. PRIMARY SURVEY

A foreign body in the airway can cause complete obstruction and can rapidly progress to an emergent airway, particularly in children. Initial evaluation should include assessing the patient for level of alertness, respiratory distress, and hemodynamic stability. If complete obstruction is suspected the Heimlich maneuver may be attempted in an alert patient.

Back blows and/or abdominal thrusts should be avoided in coughing/gagging patients, since they may turn a partially obstructed airway into a completely obstructed airway. Finger sweeps should never be attempted, since they could push the object further into the airway.

### B. PATIENT HISTORY

The patient's history is the most important portion of the exam. Adults often give a history of choking or dysphagia/odynophagia following a certain event. Pediatric patients are much more challenging, because only a small percentage will have a witnessed episode.

A foreign body should be suspected when a patient has choking or severe coughing with respiratory distress. Foreign bodies can also mimic other conditions. They should be considered in healthy children with a new onset of wheezing or patients with recurrent asthma or pneumonia.

#### 1. Phases of Aspiration

There are three phases of aspiration.

- Initially patients choke, gag, and have paroxysms of coughing or airway obstruction at the inciting event.
- This subsides into an asymptomatic phase after reflexes fatigue, which can last hours to weeks.
- Complications begin in the third phase when obstruction, erosion, or infection may cause hemoptysis, pneumonia, atelectasis, abscess, or fever.

#### 2. Symptoms

Progression of symptoms may aid in localization of a foreign body.

Symptoms may include:

- Fever, chest pain, tachycardia, lethargy, and irritability in children.
- Nasal obstruction, rhinorrhea, epistaxis.
- Shortness of breath.
- Changes in voice.

- Odynophagia, dysphagia, decreased oral intake, vomiting.
- Ptyalism.
- Hemoptysis, hematemesis.
- Neck pain.

### 3. Information Gathering

#### a. Foreign Body

It is important to gather information about the foreign body:

- Size.
- Shape.
- Material.
- When the aspiration or ingestion occurred.

#### b. History of Similar Episodes

A history of similar episodes is also important. Recurrent episodes suggest the need for further work-up to rule out an underlying neurologic or anatomic abnormality.

#### c. Last Oral Intake

It is important to know when the patient last ate or drank.

#### d. Complete Patient History

- Medical history.
- Surgical history.
- Medications.
- Allergies.
- Social history.

## C. PHYSICAL EVALUATION

### 1. General

Check the patient's vital signs, alertness, and interactivity.

### 2. Head, Eyes, Ears, Nose, and Throat

Evaluate HEENT for the following:

- *Airway*—Stridor, stertor, nasal flaring, retractions.
- *Voice*—Hoarse, breathy, muffled.
- *Oral cavity/oropharynx*—Dentition, lacerations/abrasions, foreign body.
- *Neck*—Crepitus, mobility, palpable thud over trachea or audible slap sometimes appreciated with tracheal foreign bodies.

### 3. Pulmonary

Check for retractions, wheezing, or diminished breath.

## CHAPTER 10: Foreign Bodies and Caustic Ingestion

### 4. Abdomen

Check for bowel sounds, tenderness to palpation, and rigidity.

### 5. Fiberoptic Exam

In all patients, airway stability is the most important consideration. Lack of patient cooperation or intolerance of a fiberoptic exam may dislodge a foreign body in the upper aerodigestive tract and lead to aspiration with subsequent obstruction. If fiberoptic evaluation has the potential to turn a stable airway into an unstable airway, imaging and possible intraoperative evaluation should be considered.

### D. IMAGING

Radiographic studies may confirm or localize a suspected foreign body. In pediatric patients, 70–80 percent of airway foreign bodies are vegetable matter, most commonly a radiolucent peanut. The majority of pediatric esophageal foreign bodies are radiopaque coins, but most adolescent and adult esophageal foreign bodies are food boluses. Therefore, lack of radiographic findings does not rule out a potential foreign body in the setting of a convincing history and physical exam.

### 1. Aspiration

#### a. Radiographs

- Posterior-anterior (PA) and lateral soft tissues of the neck should be obtained for all laryngeal and tracheal foreign bodies.
- PA and lateral chest x-ray should be performed if there is a suspected pulmonary foreign body.
- Hyperinflation found on inspiratory and expiratory chest films or atelectasis on inspiratory films can aid in the diagnosis of a radiolucent foreign body. In pediatric patients, failure of the dependent lung to collapse in lateral decubitus films suggests bronchial obstruction. Both sides are recommended for comparison.
- Fluoroscopic evaluation is of little benefit in initial diagnosis. Decreased diaphragmatic movement on the obstructed side is noted in about 50 percent of cases. Fluoroscopy may be more beneficial in extraction of a foreign body. Biplanar fluoroscopy may be used for retrieval of radiopaque foreign bodies in the lung periphery.



## 2. Ingestion

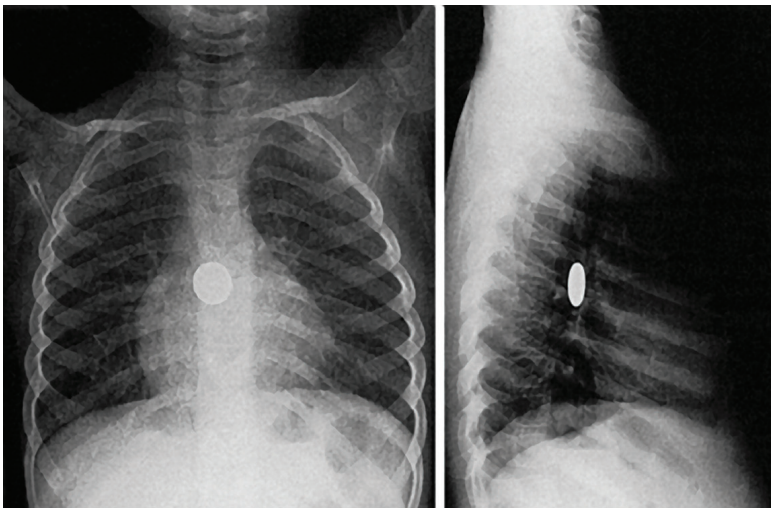
### a. Radiographs

#### i. PA and Lateral Chest Films

PA and lateral chest films from the esophageal inlet to the abdomen are performed to evaluate the possible presence of a foreign body (Figure 10.2). If a radiopaque foreign body is found in the alimentary tract, three factors predict spontaneous passage:

- Male gender.
- Older than 5 years.
- Location in the distal esophagus.

An observation period of 8–16 hours is considered appropriate management in otherwise healthy children with coin ingestion that is causing no obvious symptoms and no distressing signs.



**Figure 10.2**

Chest films of a coin in the midesophagus. Source: Flint et al., Figure 208-3.

#### ii. Barium Contrast

Barium contrast for suspected radiolucent foreign bodies should be avoided. A negative scan is not sufficient to rule out a foreign body, as the object may be obscured by the swallowed material. Barium contrast would also delay the time for the patient to enter the operating room for endoscopy.

## CHAPTER 10: Foreign Bodies and Caustic Ingestion

### **b. Computed Tomography**

CT studies may confirm or help identify a radiolucent foreign body, such as a food bolus or a fish or chicken bone. Although CT imaging is not required, it may be useful in specific patients:

- Patients with multiple medical problems who are less than ideal surgical candidates.
- Patients who present with worsening symptoms beginning days prior to presentation to rule out submucosal migration of the foreign body or potential abscess formation.

## **E. MANAGEMENT**

If the patient is in respiratory distress, oxygen, heliox, and either intubation or an emergent surgical airway may be needed before the object can safely be removed.

### **1. Special Considerations**

Although some esophageal foreign bodies may be monitored for possible passage, some foreign bodies require emergency removal.

#### **a. Disk Battery**

If a disk battery becomes lodged in the esophagus, immediate action is required. Corrosive material that leaks from the battery will lead to (1) esophageal mucosal injury within 1 hour and (2) perforation with possible mediastinitis in as little as 4–6 hours.

#### **b. Pills**

Some pills are irritating to esophageal mucosa. If the impacted pill falls into this category, endoscopy with removal of all pill remnants is recommended.

#### **c. Sharp or Pointed Objects**

These objects may cause more trauma as they transverse the aerodigestive tract. To remove them without causing further damage, disengage the point from the mucosa by moving it distally, and sheathe the point within the endoscope during extraction.

## **2. Endoscopy**

### **a. Indications**

#### **i. Bronchoscopy**

Patients with a confirmed foreign body in the airway or a suspicious history, despite negative radiographic imaging, should undergo bronchoscopy.

### ii. Esophagoscopy

Symptomatic patients with suspected esophageal foreign bodies should undergo esophagoscopy.

### iii. Patient Monitoring

Asymptomatic patients may be monitored if the retained object is not at risk of causing more injury. If the object has not passed from the esophagus after appropriate monitoring or is too large to pass through the pylorus, the object should be removed.

## b. Preparation

It is important to maintain communication between the anesthesiologist and the endoscopist to maximize patient safety. Make sure the proper equipment is available and functioning before bringing the patient into the operating room. If the center is inadequately equipped or staffed for this particular type of case and the patient is stable, arrange for transferring the patient to another hospital.

### i. Bronchoscope and Esophagoscope

Assemble both a bronchoscope and an esophagoscope in the operating room. Some foreign bodies may become dislodged on induction or during the case, and either aspirated or swallowed unintentionally. Age-appropriate endoscopes should be prepared for the case, as well as an endoscope that is one size smaller than anticipated, in the event the aerodigestive tract is smaller than normal. Table 10.1 presents age-based guidelines for selecting bronchoscopes, laryngoscopes, and esophagoscopes for diagnostic endoscopy.

**Table 10.1. Age-Based Guidelines for Selection of Bronchoscope, Laryngoscope, and Esophagoscope for Diagnostic Endoscopy**

Mean Age (Range)	Bronchoscope Size*	mm*	Laryngoscope Size*	Esophagoscope Size*
Premature infant	2.5	3.7	8	4
Term newborn (newborn to 3 mo.)	3	5.8	8	4-5
6 mo. (3-18 mo.)	3.5	5.7	9	5-6
18 mo. (1-3 yr.)	3.7	6.3	10.5	6
3 yr. (2-6 yr.)	4	6.7	10.5-12	6-7
7 yr. (5-10 yr.)	5	7.6	12	7
10 yr. (>10 yr. to adolescent)	6	8.2	16	8

\*Outside diameter given in millimeters. Source: Flint et al., Table 208-1.

## CHAPTER 10: Foreign Bodies and Caustic Ingestion

### *ii. Laryngoscope*

Make sure an age-appropriate laryngoscope is also ready.

### *iii. Forceps*

Before bringing the patient into the operating room, select forceps based on the location and type of foreign body. Optical forceps are preferable, because of their visualization capabilities and manipulative characteristics. However, optical forceps may impair ventilation, because of their larger size, which incorporates the optical tract. A Magill forceps and a Miller or Macintosh blade from the anesthesiologist are often helpful for foreign bodies above the glottis.

### **c. Procedure**

#### *i. General anesthesia*

Use general anesthesia to provide optimal airway control and patient comfort.

#### *ii. Esophageal Foreign Body*

If an esophageal foreign body is suspected, intubate the patient for airway protection, to prevent inadvertent aspiration during attempted removal, and to minimize tracheal compression caused by the rigid esophagoscope.

#### *iii. Upper Airway Foreign Bodies*

For upper airway foreign bodies, keep the patient spontaneously breathing. Topically anesthetize the larynx with 1–4 percent lidocaine, depending on the patient's size and age, to inhibit laryngeal reflexes and reduce the incidence of laryngospasm. Give preoxygenation and maintain oxygenation by placing a catheter through the nares and into the hypopharynx.

#### *iv. Retrieval of the Foreign Body*

During retrieval of the foreign body, remove the bronchoscope or esophagoscope, forceps, and foreign body as a unit. Upon removal of the foreign body, reexamine the airway or esophagus to look for a second foreign body and to assess any potential damage.

Occasionally a foreign body is swallowed or aspirated during induction. If a previously confirmed foreign body is no longer visualized, perform a complete bronchoscopy and esophagoscopy.

### **3. Controversies in Management: Flexible versus Rigid Endoscopy**

#### **a. Rigid Endoscopy**

Traditionally, rigid endoscopy is preferred for its ability to secure the airway and provide control during the removal of foreign bodies. For this

reason, rigid endoscopy is still recommended in pediatric patients for aspirated and ingested foreign bodies.

#### **b. Flexible Endoscopy**

Advances in flexible endoscopy with improved instrumentation have allowed for comparable foreign body retrieval and may be considered in adults or patients who are not ideal candidates for general anesthesia. Flexible endoscopy may be used for removal of blunt objects or meat impaction, but is not recommended for sharp objects due to inability to sheath the object and protect the mucosa on retrieval. Gastric foreign bodies are most successfully removed with flexible endoscopes.

### **4. Postoperative Management**

#### **a. Monitoring**

Patients, particularly children, should be monitored for approximately 4 hours for fever, tachycardia, or tachypnea.

#### **b. Airway Edema**

If airway edema is noted during the case, consider racemic epinephrine with or without steroids.

#### **c. Reflux Precautions and Medical Therapy**

Reflux precautions and medical therapy are prescribed, depending on the extent of mucosal injury from esophageal foreign bodies.

#### **d. Perforation or Heightened Symptoms**

If a perforation is suspected or symptoms worsen, obtain a chest x-ray immediately postoperatively (see II.D.2.b, Computed Tomography).

## **F. PREVENTION AND MANAGEMENT OF COMPLICATIONS**

### **1. Indications for Antibiotics**

Consider using antibiotics for the following conditions:

- Aspirated vegetable matter or retained foreign bodies with thick mucoid secretions.
- Esophageal perforation, mediastinitis, or abscess formation.
- Patients with underlying pulmonary issues or poor lung compliance.

Broad-spectrum antibiotic selection should include coverage for gram-negative bacilli and methicillin-resistant *Staphylococcus aureus*. Anaerobe coverage should be considered for patients with significant periodontal disease, alcoholism, or foul smelling sputum. Antibiotic coverage may be adjusted based on culture results and continued for 7 days.

## CHAPTER 10: Foreign Bodies and Caustic Ingestion

### 2. Pulmonary

#### a. Atelectasis

Atelectasis is usually asymptomatic and will resolve with patient mobility or incentive spirometer.

#### b. Pneumonia

Pneumonia may be the presenting symptom or may develop a few days following removal of the foreign body. Treat with antibiotic coverage as noted in I.F, above. If the patient's symptoms do not improve with adequate therapy, a missed second foreign body should be considered.

#### c. Bleeding

Bleeding is usually from mucosal trauma or granulation tissue. This is often self-limiting. In rare instances, vessel erosion may lead to a significant bleed, requiring urgent thoracic surgery intervention.

#### d. Pneumothorax or Pneumomediastinum

Pneumothorax or pneumomediastinum is usually from a small perforation in the airway that heals spontaneously and does not require further intervention. Symptomatic patients may be treated with oxygen and serial chest x-rays. If the pneumothorax or pneumomediastinum increases in size or is large on initial identification, a thoracic surgery consult should be called for further intervention.

### 3. Esophageal

#### a. Bleeding

Bleeding is usually from direct mucosal trauma and is self-limiting. Consider proton pump inhibitors and/or H2 blockers to prevent further injury to the damaged mucosa.

#### b. Esophageal Perforation

- Early recognition and management of esophageal perforations have decreased the mortality rate from 60 percent to 9 percent from complications, such as a retroesophageal abscess or mediastinitis.
- Cervical subcutaneous emphysema, fever, tachycardia, tachypnea, and increased pain may all be early signs of a perforation.
- If a small esophageal perforation is suspected intraoperatively, place a nasogastric tube and perform a barium swallow or gastrografin study. If esophageal perforation is confirmed, keep the patient NPO, and consider broad-spectrum antibiotics.

## III. Caustic Ingestion

The incidence of caustic ingestion has decreased since the Federal Hazardous Substances Act of 1960 and the Poison Prevention

Packaging Act of 1970 mandated childproof container caps and packaging. Injury can range from mild mucosal irritation to death, depending on the quantity and type of substance ingested.

## A. CATEGORIES OF CAUSTIC MATERIALS

Caustic materials may be classified into three different categories, as shown below. Table 10.2 presents some examples of these categories of caustic materials.

**Table 10.2. Categories and Examples of Caustic Materials**

Acids (pH < 7)	Alkali (pH > 7)	Bleach (pH ~7)
Toilet bowl cleaner	Lime	Sodium hypochlorite
Battery fluid	Laundry detergent	Calcium hypochlorite
Sulfuric acid	Clinitest® tablets Hair-relaxing agents*	

\*Hair-relaxing agent packaging is not mandated by the U.S. Food and Drug Administration to be sold in child-safe packaging. Their pleasant odor and colorful tubs unintentionally attract children, leading to an increased incidence of ingestion over the last decade.

### 1. Acids (pH <7)

Acids (pH <7) cause coagulation necrosis with eschar formation, which limits its penetration to deeper tissues. Esophageal damage is less likely due to the protection afforded by the slightly alkaline pH of the esophagus and resistance of the squamous epithelium to acids. Gastric injury may occur at a slightly higher incidence due to pooling and prolonged contact from reflex pylorospasm. The acidic pH in the stomach can also heighten the injury.

### 2. Alkali (pH >7)

Alkali (pH >7) agents cause liquefaction necrosis, which breaks down the cellular membranes, allowing deeper penetration into tissues. Tissue damage continues until the alkali is neutralized by its reaction with the tissues, resulting in significant injury. Areas of narrowing are at greater risk for injury (e.g., cricopharyngeus, aortic arch, left mainstem bronchus, diaphragmatic hiatus).

### 3. Bleach (pH ~7)

Bleach (pH ~7) is an esophageal irritant that causes minimal morbidity or mortality.

## CHAPTER 10: Foreign Bodies and Caustic Ingestion

### B. PRIMARY SURVEY

Initial evaluation should include assessing the patient for level of alertness, respiratory distress, and hemodynamic stability. Injury may range from upper airway edema, causing respiratory distress to gastric perforation and hemodynamic instability. Unstable patients may need to go emergently to the operating room.

### C. PATIENT HISTORY

A complete patient history should be obtained (see section II.B). When obtaining the history think **A**ge, **A**mount, **A**gent, and *t*ime-**A**go.

#### 1. Age and Amount Ingested

Incidental ingestion is most common in children under 5 years of age. In these patients, the agent tends to be a common household supply. Ingested volumes are small, since the bitter taste makes the child spit out the remaining substance.

Adolescent and adult caustic ingestions are more often intentional or suicide attempts, so a larger volume is often ingested.

#### 2. Agent Ingested

It is important to identify whether the agent was an acid or a base. If the agent is known, concentration and pH can often be found online or by calling the National Poison Center's 24-hour National Poison Control Hotline (1-800-222-1222). Large volumes of strong acids are often needed to create injury, but only a few milliliters of a strong alkali can cause extensive damage instantaneously. Also, acids are more likely to result in chemical epiglottitis, which places the patient at high risk of airway obstruction. Besides the type of agent, try to determine whether it was in a liquid or granular form. Granules will need to be cleansed from the mucosa to prevent continued damage.

#### 3. Timing of Ingestion

Knowing the timing of the ingestion will help guide management. It is important to know when the caustic ingestion occurred to assess potential complications and whether the patient is a candidate for endoscopy.

### D. SYMPTOMS

- Shortness of breath.
- Changes in voice.
- Dysphagia.
- Odynophagia.
- Chest pain.



- Tachycardia.
- Abdominal pain.

## **E. PHYSICAL EXAM**

Early signs and symptoms do not correlate with the severity and extent of tissue injury. Up to 30 percent of patients with caustic esophageal injury do not show any evidence of oropharyngeal damage. The absence or presence of visible injury on physical exam should not influence further investigation.

A full patient exam should include, but not be limited to, the following:

### **1. General**

Vital signs, alert, interactive.

### **2. HEENT**

- *Airway*—Stridor, nasal flaring, retractions.
- *Voice*—Hoarse, breathy, muffled.
- *Oral cavity/oropharynx*—Burns, irritation, edema, fibrous exudates.
- *Neck*—Crepitus, mobility.
- *Fiberoptic exam*—Mucosal injury, fibrous exudates, supraglottic/glottic edema.

### **3. Pulmonary**

- Auscultation for wheezing or diminished breath sounds.

### **4. Abdomen**

- Bowel sounds, tenderness to palpation, rigidity.

## **F. PREOPERATIVE MANAGEMENT**

### **1. Limit Fluid Intake**

Patients who present immediately after ingestion and are stable may be given water to dilute the ingested substance and rinse it from the esophagus. Fluid intake should be no more than 15 milliliters per kilogram of weight, as excess fluids may induce vomiting. Gastric lavage and induced vomiting are contraindicated.

### **2. Avoid Neutralizing Agents**

Avoid neutralizing agents. They may cause exothermic chemical reactions that will increase injury to the esophagus.

### **3. Apply Conservative Measures**

Conservative measures are recommended on presentation:

- Clean oral mucosa with water to dilute any remaining caustic material.
- Remove any visible granules to prevent continued injury.

## CHAPTER 10: Foreign Bodies and Caustic Ingestion

### 4. Place Nasogastric Feeding Tubes under Supervision

Nasogastric feeding tubes may be placed during endoscopy. Placement without direct supervision may increase the risk of a perforation.

### 5. Use Imaging

#### a. Radiographic Imaging

Radiographic imaging plays a minimal role in initial presentation. A barium esophagram is inadequate to detect mucosal irregularities and motility disturbances, leading to a significant false negative rate. It may be used to rule out a suspected perforation, but should not replace an endoscopic exam, unless the patient presented more than 48 hours after the inciting event.

#### b. Nuclear Medicine

Nuclear medicine may be used in detecting esophageal injury after pediatric ingestion. Technetium 99m-labeled sucralfate has high sensitivity and specificity in determining the presence of an esophageal injury, which allows for screening of injuries, but does not determine severity or enable intervention.

### 6. Consider Endoscopy

#### a. Indications for Endoscopy

- Endoscopy is recommended for any adult having ingested a strong alkali or acid, regardless of the lack of presenting signs or symptoms.
- Pediatric endoscopy can be reserved for children with significant oral burns, dysphagia, or stridor. Studies have shown asymptomatic children were not found to develop sequelae. However, if glucose test tablets or a battery is suspected, the patient should be taken emergently to the operating room, despite the absence of symptoms.
- In children who lack a strong history and have only one presenting sign or symptom, the risk of significant injury is low, and endoscopy can be deferred or held, pending the results of a nuclear medicine study. If a technetium 99m-labeled sucralfate study results in positive findings, the patient should undergo endoscopy.

#### b. Timing of Endoscopy

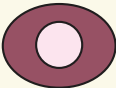

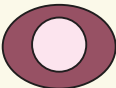
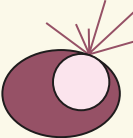
In stable patients, upper endoscopy should be performed during the first 24–48 hours after ingestion. The full extent of mucosal injury will not be visible in the first 24 hours. After several days, necrotic tissue sloughs off, the esophageal wall becomes weak, and the patient is at higher risk of perforation during endoscopy or nasogastric tube placement.

### c. Evaluation of Endoscopy

#### i. Endoscopic Stages of Esophageal Injuries

Table 10.3 presents the endoscopic stages of esophageal injuries, along with information about treatment and outcome.

**Table 10.3. Endoscopic Stages of Esophageal Burns**

Grade of Injury	Effect of Injury		Injury Treatment and Outcome
Normal	No erythema		No healing time.
First degree	Mucosal erythema		Consistently heals uneventfully.
Second degree	Mucosal erythema Noncircumferential exudate		Occasionally forms strictures.
Third degree	Mucosal erythema Circumferential exudate.		Most form strictures.
Fourth degree	Mucosal erythema Circumferential exudate Esophageal wall perforation		Carries the additional risk of sepsis and mediastinitis. Small perforations may be treated conservatively. Larger perforations with surrounding necrosis may require resection with reanastomosis.

Source: Flint et al., Figure 211-2.

#### ii. Tracheoscopy

Tracheoscopy should be included to examine the posterior tracheal wall for all third- and fourth-degree injuries.

#### iii. Abortion of Endoscopic Evaluation

Endoscopic evaluation should be aborted when there is no definable lumen.

#### iv. Type of Esophagoscope

Rigid and flexible esophagoscopes may both be used. However, a flexible esophagoscope is needed to adequately visualize the stomach.

## CHAPTER 10: Foreign Bodies and Caustic Ingestion

If necrosis is identified extending into the gastric mucosa, direct visualization of the outer gastric wall should be considered to rule out transmural necrosis.

### G. POSTOPERATIVE MANAGEMENT

#### 1. Pharmacologic Therapy

Gastric reflux precautions, proton pump inhibitors, histamine H<sub>2</sub> receptor blockers, or sucralfate should be considered for patients with any mucosal injury.

The use of broad-spectrum antibiotics and corticosteroids for second- and third-degree injuries is controversial. No study has proven their effectiveness in preventing stricture formation or other subsequent complications. Broad-spectrum antibiotics are required for symptomatic patients (fever, chest pain, tachycardia) with a known perforation, given their risk of mediastinitis. Use is controversial in asymptomatic patients, although routinely administered.

#### 2. Alimentation

Patients with first- or second-degree injuries may start a liquid diet immediately following endoscopy and advance to a regular diet over 24–48 hours if they remain asymptomatic.

A nasogastric feeding tube should be placed under direct visualization for all patients with third- and fourth-degree injuries. Although its primary purpose is to allow for adequate nutrition, it also serves as a mechanical stent if left in place throughout reepithelialization. Close observation in a hospital setting is mandatory for all patients with these injuries. Third-degree injuries may progress to fourth-degree injuries after 48 hours.

Patients with third-degree injuries may attempt a clear diet after 3 days and advance to a regular diet if they remain asymptomatic. A barium or gastrografin swallow study should be repeated after 3 days for all patients with fourth-degree injuries that show clinical improvement before attempting postoperative intake.

#### 3. Further Workup

Patients with intentional caustic ingestion should be evaluated and cleared by psychiatry prior to discharge.

A baseline barium swallow should be completed 3 weeks post-incident in patients with second-degree injuries or higher.

## **H. COMPLICATIONS**

### **1. Esophageal Perforation**

Esophageal perforation may lead to mediastinitis, sepsis, and ultimately death. Patients with esophageal perforations should be monitored closely and treated as discussed previously.

### **2. Esophageal Strictures**

Esophageal strictures most commonly occur at the level of the cricopharyngeus, aortic arch, or lower esophageal sphincter. Strictures from caustic ingestion tend to be longer and tighter than benign strictures and may be refractory to and have a higher rate of complications with dilation.

### **3. Esophageal Carcinoma**

Esophageal carcinoma may develop after caustic ingestion. One in seven patients may develop malignancy, leading some physicians to advocate for regular esophageal surveillance, although the latent period for development may be as long as 50 years. Nodularity or ulceration in the region of a previously smooth stricture suggests malignant transformation.

## **IV. Conclusion**

Foreign body aspiration or ingestion and caustic ingestion are serious, potentially life-threatening emergencies. In the course of trauma, foreign bodies, such as chewing gum, teeth, dentures, and other detritus of impact, can be ingested or aspirated, complicating the evaluation and treatment of traumatic injuries. Any difficulties with airway and breathing after traumatic events should raise the specter of possible foreign bodies in the aerodigestive tract, in addition to the other possible etiologies. Caustic ingestions, while not as common as foreign body aspiration/ingestion, can also occur during traumatic episodes, particularly burns and by-products of combustion engines, batteries, and industrial equipment.

The most dangerous conditions exist when these emergencies are seen in pediatric patients, as their airways are small and susceptible, and their functional reserves are quite restricted. The otolaryngology-head and neck surgery resident must be highly suspicious for these injuries and understand the evaluative and therapeutic procedures to rescue the patients. This includes knowledge about the historical information, findings on physical examination, appropriate use of imaging studies, and the proper selection of endoscopic equipment and technology to clear the aerodigestive tract. This chapter provides the fundamental knowledge to care for patients with foreign bodies and caustic ingestion.

## CHAPTER 10: Foreign Bodies and Caustic Ingestion

### V. References

Flint PW, Haughey BH, Lund VJ, et al. *Cummings Otolaryngology-Head and Neck Surgery*. 5th ed. Philadelphia, PA: Elsevier Health Sciences; 2010.

Myers EN, Carreau RL, eds. *Operative Otolaryngology: Head and Neck Surgery*, Vol. 1. 2nd ed. Philadelphia, PA: Elsevier Health Sciences; 2008.

# Chapter 11: Outcomes and Controversies

G. Richard Holt, MD, MSE, MPH, MABE

## I. Outcomes

### A. FACTORS AFFECTING THE CLINICAL OUTCOME

The clinical outcome for an individual patient after treatment for injuries to the face, head, and neck will depend upon a number of factors:

- Extent of facial, head, and neck injuries.
- Preexisting comorbidities (diabetes, hypertension, pulmonary and vascular disorders).
- Extent of other bodily injuries (central nervous system, spinal cord, cardiopulmonary, ocular).
- Timing of diagnosis.
- Timing of treatment.
- Availability of appropriate diagnostic services.
- Experience, current knowledge, and competence of surgeon.
- Patient compliance and accountability.

### B. MAIN FACTORS UNDER SURGEON CONTROL

Not all of the above factors are under the direct control of the surgeon, especially where resources are limited and where the community has a high level of endemic noncommunicable diseases. The main factors under surgeon control are the **extent of knowledge, experience, and competency of the surgeon**. Patient outcomes after trauma care have a strong correlation with these factors. Therefore, throughout their career, otolaryngologists–head and neck surgeons must maintain interest in, and the practice of, modern trauma surgery.

### C. CASE MANAGEMENT AND COORDINATION

Case management and coordination are important in the care of patients with serious face, head, and neck traumatic injuries or those with multiple body trauma. The more severely injured patients may require one or more of the following rehabilitative and restorative services:

- Physical rehabilitation.
- Cognitive retraining.
- Speech and swallowing therapy.
- Clinic and surgical procedure appointments.
- Medication compliance.

## CHAPTER 11: Outcomes and Controversies

- Assistance with insurance coverage (Medicaid).
- Dental and ophthalmology services.

It is the surgeon's responsibility to ensure the continuity of care and access for the patient to the full range of rehabilitative services that the patient may need to achieve the best ultimate outcome.

### D. CLINICAL INDICATORS AND BEST PRACTICES

A number of clinical indicators and best practices in face, head, and neck trauma care are based on current evidence, expert opinion, and consensus experience. It is important that surgeons maintain systematic records of their patients' outcomes, so they may understand and compare the outcomes with expected national standards. Quality improvement is the salutary and expected result of such outcome studies. To review general quality and patient safety information for surgeons, visit the Academy's Web site (<http://www.entnet.org/Practice/quality.cfm>).

## II. Controversies

As with all fields of surgery, there are controversies and differences of opinions in trauma care of the face, head, and neck. In addition to variations in training and experience, there are philosophical differences in how surgeons approach soft tissue and osseous trauma repair and reconstruction. Additionally, resource allocation and cost factors may affect particular protocols for trauma care. Some controversies or differences of opinion bear disclosure for consideration.

### A. CLOSED VERSUS OPEN REDUCTION OF NASAL FRACTURES

#### 1. Local Anesthesia versus Deeper Anesthesia

*PRO local anesthesia*—Mild to moderately displaced supratip or lateral nasal fractures may be adequately reduced in a clinical setting utilizing topical and local anesthesia.

*CON local anesthesia*—Lateral nasal fractures cannot be adequately reduced without deeper anesthesia, and operative reduction will produce better end results.

#### 2. Outpatient versus Inpatient Closed Reduction

*PRO outpatient*—Outpatient closed reduction of nasal fractures will be less expensive and more cost-effective.

*CON outpatient*—Because of the likelihood that closed reduction will not achieve a satisfactory result and will require a second, operative



intervention, it is better to treat the patient in the operating room initially.

## **B. IMMEDIATE PRIMARY VERSUS DELAYED CLOSURE OF CONTAMINATED SOFT TISSUE WOUNDS**

### **1. Risk of Infection**

*PRO primary closure*—Because of the “privileged” vascular supply to the face, scalp, and neck, the likelihood is high that primary closure of contaminated wounds, after appropriate cleansing, will be successful.

*CON primary closure*—It is risky to close a contaminated wound primarily, due to the risk of methicillin-resistant *Staphylococcus aureus* (MRSA) and other infectious agents. It is better to clean the wound over 2-3 days and then close it in a delayed fashion.

### **2. Cost Considerations**

*PRO primary closure*—Considerations in this controversy include the cost of early discharge after primary closure.

*CON primary closure*—There is risk of more expensive readmission and intensive care if infection occurs.

### **3. Use of Metal Alloy or Resorbable Fixation Plates**

*PRO metal alloy plates*—Metal alloy fixation plates reduce the risk of mobility at tension fracture sites and the risk for nonunion.

*CON metal alloy plates*—Metal alloy plates are more thermal conductive than the absorbable plates and may require removal for discomfort.

*PRO resorbable fixation plates*—Resorbable fixation plates reduce stress shielding over time at tension fracture sites.

*CON resorbable fixation plates*—Most resorbable fixation plates are higher profile, and thus more palpable, than the metal alloy fixation plates.

## **III. Final Considerations**

These examples are provided to emphasize that trauma care decisions and options by otolaryngologist-head and neck surgeons have variation across the United States, occurring within the general framework of clinical guidelines, best practices, and best evidence. Your attending faculty may have a practice protocol or philosophy, based on good scientific principles, that varies somewhat from the general recommendations contained in this Resident Manual. Yet, the information we

## CHAPTER 11: Outcomes and Controversies

propose for your consideration herein is an excellent starting point for an educational conversation between you and your attending faculty member.

Additionally, you should seek further extensive reading on trauma care and surgery in reference textbooks, specialty journals, and focused trauma publications to expand the range and depth of your foundational knowledge.



## Conclusion

G. Richard Holt, MD, MSE, MPH, MABE

This Manual was developed for you by the Resident Trauma Manual Task Force of the American Academy of Otolaryngology-Head and Neck Surgery (AAO-HNS) Committee on Trauma, with the excellent assistance of the Education Staff of the AAO-HNS Foundation. Its concept was to provide you, the Resident Physician in Otolaryngology-Head and Neck Surgery, with an electronic, quick-reference tool to aid your evaluation and management of patients with traumatic injuries of the face, head, and neck. There has been a growing concern in our specialty that otolaryngologists-head and neck surgeons in community practice are losing interest in providing trauma care in their emergency room settings. This trend must be reversed for the good of the specialty in its capabilities to provide **comprehensive medical and surgical trauma care.**

The Committee on Trauma encourages you to learn as much as possible about trauma care in the region of the face, head, and neck, to gain valuable clinical and surgical experience, and to develop a sense of the professional rewards that come from this type of reconstructive surgery. Remember that your efforts on behalf of the traumatized patient can make a significant difference in the patient's quality of life.

We wish you good success in your residency training and a rewarding life of service in the future practice of otolaryngology-head and neck surgery.

## AAO-HNS Committee on Trauma

### **COMMITTEE CHAIR**

#### **Joseph A. Brennan, MD**

San Antonio Military Medical Center  
Fort Sam Houston, Texas

### **COMMITTEE CHAIR-ELECT**

#### **Anna Pou, MD**

Louisiana State University  
Health Science Center  
New Orleans, Louisiana

#### **Ben J. Balough, MD**

Kaiser Permanente Northern California  
Sacramento, California

#### **Jose E. Barrera, MD**

San Antonio Military Medical Center  
Fort Sam Houston, Texas

#### **Mark E. Boston, MD**

San Antonio Military Medical Center  
Fort Sam Houston, Texas

#### **Marion E. Couch, MD, PhD**

University of Vermont Medical Center  
Burlington, Vermont

#### **Jaimie DeRosa, MD, MS**

Massachusetts Eye and Ear Infirmary  
Boston, Massachusetts

#### **Paul J. Donald, MD**

University of California Davis  
Medical Center  
Sacramento, California

#### **Robert L. Eller, MD**

Royal Air Force  
Lakenheath, England

#### **Jeffrey A. Faulkner, MD**

Landstuhl Army Medical Center  
Germany

#### **David K. Hayes, MD**

San Antonio Military Medical Center  
Fort Sam Houston, Texas

#### **G. Richard Holt, MD, MSE, MPH, MABE**

University of Texas Health Science Center  
San Antonio, Texas

#### **Michael R. Holtel, MD**

Sharp Rees-Stealy Medical Centers  
San Diego, California

#### **Robert M. Kellman, MD**

State University of New York Upstate  
Medical University  
Syracuse, New York

#### **Manuel A. Lopez, MD**

Lopez Facial Plastic Surgery  
San Antonio, Texas

#### **Lawrence J. Marentette, MD**

University of Michigan Medical Center  
Ann Arbor, Michigan

#### **Stephen C. Maturo, MD**

San Antonio Military Medical Center  
San Antonio, Texas

#### **Eric J. Moore, MD**

Mayo Clinic  
Rochester, Minnesota

#### **Cecelia E. Schmalbach, MD**

San Antonio Military Medical Center  
Fort Sam Houston, Texas

#### **Joseph C. Snizek, MD**

Tripler Army Medical Center  
Honolulu, Hawaii

#### **Michael G. Stewart, MD, MPH**

Weill Cornell Medical College  
New York, New York

#### **Christian L. Stallworth, MD**

University of Texas Health Science Center  
San Antonio, Texas

The American Academy of Otolaryngology—Head and Neck Surgery Foundation’s education initiatives are aimed at increasing the quality of patient outcomes through knowledgeable, competent, and professional physicians. The goals of education are to provide activities and services for practicing otolaryngologists, physicians-in-training, and non-otolaryngologist health professionals.

The Foundation’s AcademyU® serves as the primary resource for otolaryngology-head and neck activities and events. These include an online library of expert-developed learning courses, learning platforms, and e-books, as well as Patient Management Perspectives in Otolaryngology and the Home Study Course. In addition, the AAO-HNSF Annual Meeting & OTO EXPO is the world’s largest gathering of otolaryngologists, offering a variety of education seminars, courses, and posters. Many of the Foundation’s activities are available for *AMA PRA Category 1 Credit*™.

Visit the Academy’s Web site, [www.entnet.org](http://www.entnet.org), to find out how AcademyU® can assist you and your practice through quality professional development opportunities.



**AMERICAN ACADEMY OF  
OTOLARYNGOLOGY—  
HEAD AND NECK SURGERY**

**F O U N D A T I O N**

**American Academy of Otolaryngology—Head and Neck  
Surgery Foundation**

**1650 Diagonal Road  
Alexandria, VA 22314-2857 USA**

**T / 1.703.836.4444**

**F / 1.703.683.5100**

**[www.entnet.org](http://www.entnet.org)**