

Resident Manual of Trauma to the Face, Head, and Neck

First Edition



AMERICAN ACADEMY OF
OTOLARYNGOLOGY-
HEAD AND NECK SURGERY

F O U N D A T I O N

©2012 All materials in this eBook are copyrighted by the American Academy of Otolaryngology—Head and Neck Surgery Foundation, 1650 Diagonal Road, Alexandria, VA 22314-2857, and are strictly prohibited to be used for any purpose without prior express written authorizations from the American Academy of Otolaryngology—Head and Neck Surgery Foundation. All rights reserved.

For more information, visit our website at www.entnet.org.

eBook Format: First Edition 2012.

ISBN: 978-0-615-64912-2

Preface

The surgical care of trauma to the face, head, and neck that is an integral part of the modern practice of otolaryngology–head and neck surgery has its origins in the early formation of the specialty over 100 years ago. Initially a combined specialty of eye, ear, nose, and throat (EENT), these early practitioners began to understand the inter-relationships between neurological, osseous, and vascular pathology due to traumatic injuries. It also was very helpful to be able to treat eye as well as facial and neck trauma at that time.

Over the past century technological advances have revolutionized the diagnosis and treatment of trauma to the face, head, and neck—angiography, operating microscope, sophisticated bone drills, endoscopy, safer anesthesia, engineered instrumentation, and reconstructive materials, to name a few. As a resident physician in this specialty, you are aided in the care of trauma patients by these advances, for which we owe a great deal to our colleagues who have preceded us. Additionally, it has only been in the last 30–40 years that the separation of ophthalmology and otolaryngology has become complete, although there remains a strong tradition of clinical collegiality.

As with other surgical disciplines, significant advances in facial, head, and neck trauma care have occurred as a result of military conflict, where large numbers of combat-wounded patients require ingenuity, inspiration, and clinical experimentation to devise better ways to repair and reconstruct severe wounds. In good part, many of these same advances can be applied to the treatment of other, more civilian pathologies, including the conduct of head and neck oncologic surgery, facial plastic and reconstructive surgery, and otologic surgery. We are indebted to a great many otolaryngologists, such as Dr. John Conley's skills from World War II, who brought such surgical advances from previous wars back to our discipline to better care for patients in the civilian population. Many of the authors of this manual have served in Iraq and/or Afghanistan in a combat surgeon role, and their experiences are being passed on to you.

So why develop a manual for resident physicians on the urgent and emergent care of traumatic injuries to the face, head, and neck? Usually the first responders to an academic medical center emergency department for evaluation of trauma patients with face, head, and neck injuries will be the otolaryngology–head and neck surgery residents. Because there is often a need for urgent evaluation and treatment—bleeding and

airway obstruction—there is often little time for the resident to peruse a reference or comprehensive textbook on such trauma. Thus, a simple, concise, and easily accessible source of diagnostic and therapeutic guidelines for the examining/treating resident was felt to be an important tool, both educationally and clinically.

This reference guide for residents was developed by a task force of the American Academy of Otolaryngology—Head and Neck Surgery (AAO-HNS) Committee on Trauma. AAO-HNS recently established this standing committee to support the continued tradition of otolaryngology-head and neck surgery in the care of trauma patients. An electronic, Portable Document Format (PDF), suitable for downloading to a smart phone, was chosen for this manual to facilitate its practical use by the resident physician in the emergency department and preoperative area.

It should be used as a quick-reference tool in the evaluation of a trauma patient and in the planning of the surgical repair and/or reconstruction. This manual supplements, but does not replace, more comprehensive bodies of literature in the field. Use this manual well and often in the care of your patients.

G. Richard Holt, MD, MSE, MPH, MABE

Editor and Chair

Task Force on Resident Trauma Manual

Joseph A. Brennan, MD, Colonel, MC, USAF

Chair

AAO-HNS Committee on Trauma

Acknowledgments

This quick reference guide for resident physicians in trauma management reflects the efforts of many individuals in the American Academy of Otolaryngology—Head and Neck Surgery and a special task force of the AAO-HNS Committee on Trauma.

The editors would like to thank all of the authors who generously gave their time and expertise to compose excellent chapters for this Resident Manual in the face of busy clinical and academic responsibilities and under a very narrow timeframe of production. These authors, experts in the care of patients who have sustained trauma to the face, head, and neck, have produced practical chapters that will guide resident physicians in their assessment and management of such trauma. The authors have a wide range of clinical expertise in trauma management, gained through community and military experience.

A very special appreciation is extended to Audrey Shively, MSHSE, MCHES, CCMEP, Director, Education, of the AAO-HNS Foundation, for her unwavering efforts on behalf of this project, and her competent and patient management of the mechanics of the Resident Manual's production. Additionally, this manual could not have been produced without the expert copyediting and design of diverse educational chapters into a cohesive, concise, and practical format by Joan O'Callaghan, Director, Communications Collective, of Bethesda, Maryland.

The editors also wish to acknowledge the unwavering support and encouragement from: Rodney P. Lusk, MD, President; David R. Nielsen, MD, Executive Vice President and CEO; Sonya Malekzadeh, MD, Coordinator for Education; and Mary Pat Cornett, CAE, CMP, Senior Director, Education and Meetings, of the AAO-HNS/F. We also appreciate the administrative support of Rudy Anderson as AAO-HNS/F Staff Liaison for the Trauma Committee.

Since it takes a group of dedicated professionals to produce an educational and clinical manual such as this, all have shared in the effort, and each individual's contribution has been outstanding.

G. Richard Holt, MD, MSE, MPH, MABE
Editor and Chair
Task Force on Resident Trauma Manual

Joseph A. Brennan, MD, Colonel, MC, USAF
Chair
AAO-HNS Committee on Trauma

Resident Trauma Manual Authors

Joseph A. Brennan, MD, Colonel, MC, USAF

Chair, AAO-HNS Committee on Trauma
Chief, Department of Surgery
San Antonio Military Medical Center
Fort Sam Houston, Texas

G. Richard Holt, MD, MSE, MPH, MABE

Chair, Task Force on Resident Trauma Manual
Professor Emeritus, Department of Otolaryngology-Head and Neck Surgery
University of Texas Health Science Center
San Antonio, Texas

Matthew P. Connor, MD, Captain, MC, USAF

Resident Physician, Department of Otolaryngology-Head and Neck Surgery
San Antonio Uniformed Services Health Education Consortium
Fort Sam Houston, Texas

Paul J. Donald, MD

Professor and Vice Chair, Department of Otolaryngology
University of California-Davis Medical Center
Sacramento, California

Vincent D. Eusterman, MD, DDS

Director, Otolaryngology-Head and Neck Surgery
Denver Health Medical Center
Denver, Colorado

David K. Hayes, MD, Colonel, MC, USA

Chief of Clinical Operations, US Army Southern Regional Medical Command
San Antonio Military Medical Center
Fort Sam Houston, Texas

Robert M. Kellman, MD

Professor and Chair, Department of Otolaryngology and Communication Sciences
State University of New York Upstate Medical Center
Syracuse, New York

John M. Morehead, MD

Associate Professor and Program Director
Department of Otolaryngology-Head and Neck Surgery
University of Texas Health Science Center
San Antonio, Texas

Mark D. Packer, MD, Colonel (P), MC, FS, USAF

Director, DOD Hearing Center of Excellence
Chief, Neurotology, Cranial Base Surgery
San Antonio Military Medical Center
Fort Sam Houston, Texas

Whitney A. Pafford, MD

Resident Physician, Division of Otolaryngology
New York University School of Medicine
New York, New York

Mitchell Jay Ramsey, MD, Lt Colonel, MC, USA

Chief Otology/Neurotology
Landstuhl Kaiserlautern Army Medical Center
Germany

Nathan L. Salinas, MD, Captain, MC, USA

Chief, Department of Otolaryngology
Bassett Army Community Hospital
Ft. Wainwright, Alaska

Joseph C. Sniezek, MD, Colonel, MC, USA

Otolaryngology Consultant to the Surgeon General of the Army
Tripler Army Medical Center
Honolulu, Hawaii

Christian L. Stallworth, MD

Assistant Professor, Facial Plastic and Reconstructive Surgery
Department of Otolaryngology-Head and Neck Surgery
University of Texas Health Science Center
San Antonio, Texas

Matthew Scott Stevens, MD

Resident Physician, Department of Otolaryngology-Head and Neck
Surgery
University of Texas Health Science Center
San Antonio, Texas

Richard W. Thomas, MD, DDS, Major General, MC, USA

Otolaryngologist-Head and Neck Surgeon
Commanding General, Western Region Medical Command
Joint Base Lewis-McChord, Washington

Chapter 3: Upper Facial Trauma

Paul J. Donald, MD

G. Richard Holt, MD, MSE, MPH, MABE

I. Frontal Sinus and Anterior Skull Base Trauma

A. INTRODUCTION

The implementation of the shoulder harness seat belt in motor vehicles has resulted in a much lower incidence of frontal sinus fractures. Because of the thick bone of the anterior wall of the sinus as well as its curved convexity, this first barrier to the effects of cranial trauma resists fracture. Considerable force—up to 1600 foot pounds of impact—is required to fracture the anterior wall.¹ This is almost twice as much as it takes to fracture the parasymphyseal area of the mandible and 50 percent more than is required to fracture the malar eminence of the zygoma. In contrast, the posterior sinus wall and floor are often paper-thin.

The sinus has a mid-line septum that divides it into two halves. The drainage connection to the anterior aspect of the middle meatus of the lateral nasal wall begins as a funnel-shaped structure at the anterior medial extremity of the insertion of the mid-line septum in the frontal sinus floor. The connection is actually a foramen in 22.7 percent of patients and a duct in 77.3 percent.²

The frontal sinus floor has an area of common wall with the orbital roof, superiomedially, and the posterior wall forms the anterior wall of the anterior cranial fossa. The posterior wall has a central spine that projects intracranially, upon which lies the superior sagittal sinus. This venous sinus begins as a superior extension of the dorsal nasal vein of the nose as it penetrates the foramen caecum. The sinus volume increases as it courses over the convexity of the brain (Figure 3.1).

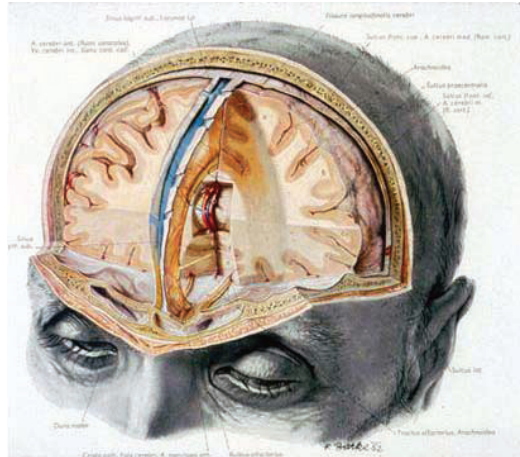
The frontal sinus mucosa has a peculiar characteristic of forming cystic structures when injured. These *mucocelles* have a tendency to erode bone probably as an osteoclastic response to the pressure exerted by the cyst.³ If they become secondarily infected, they are called *pyocelles*.

Very often the patients presenting with a fracture of the frontal sinus are victims of violent crime, gunshot wounds, or industrial accidents. They commonly have multiple other, more immediately life-threatening injuries, so the sinus injury is often overlooked. Appropriate treatment of these fractures is essential, because of the potential for the formation of a frontal sinus mucocele or pyocele. With the proximity of the

CHAPTER 3: Upper Facial Trauma

Figure 3.1

Superior sagittal sinus.



posterior sinus wall to the anterior cranial fossa, these pathological entities can lead to the life-threatening complications of meningitis and brain abscess.

B. CLASSIFICATION

Some form of classification is necessary to describe the site and severity of injury, thus creating a meaningful treatment algorithm. First, the fractures should be classified according to site. As shown in Table 3.1, fractures can be further described according to their type. The classification system breaks down to a degree, because often multiple walls are fractured and some fractures are linear while others are displaced. The treatment plan should include addressing each individual site and each individual type of fracture.

Table 3.1. Classification of Frontal Sinus Fractures according to Site and Type

Step 1: Fracture Site Classification	Step 2: Fracture Type Classification
Anterior wall	Linear
Posterior wall	Displaced
Floor	Compound
Corner	Comminuted
Through-and-through	
Frontonasal duct	

C. PRESENTATION

Since the patients have been struck with a good deal of force, many present in the emergency room in an unconscious state. The patient is emergently assessed, as outlined in Chapter 1. In the course of investigating for any central injury, a fractured frontal sinus may be apparent, but is often overlooked by virtue of the emergency stabilization and rapid evaluation required for a badly injured patient. The patient often has had an unconscious period and suffers headache. The infraorbital nerve may have been traumatized during the traumatic event, and the patient may complain of forehead numbness. There may be epistaxis, and the blood may be mixed with cerebrospinal fluid (CSF). Fractures involving the anterior wall may produce deformity.

1. Anterior Wall Fractures

Linear fractures of the anterior wall are often overlooked, but even if detected there would be no mandate to treat them. They may present with a subgaleal hematoma that resembles a depressed fracture because of its raised and irregular outline. Conversely, if the fracture is depressed, it will appear as a distinct depression in the area of fracture. However, if the patient is seen sometime after the occurrence of the injury, the depression may fill with blood, and the displaced area will be effaced.

Compound fractures are by definition in continuity with a forehead laceration. These fractures are often comminuted, and depressed bone fragments are seen in the depths of the cutaneous wound. Blood, CSF, and even brain may be seen coming through the laceration.

2. Posterior Wall Fractures

Isolated posterior wall fractures are very uncommon. If present, they are often part of a calvarial vault fracture. There are no presenting differentiating symptoms. The dilemma regarding treatment centers on distinguishing between a linear-only fracture versus a displaced fracture. Only a fine-cut computed tomography (CT) scan taken in the axial and sagittal planes will give enough definition to clearly establish or rule out displacement. When the physician is in doubt, the fracture should be treated.

A clear sign of a displaced posterior wall fracture is the presence of CSF rhinorrhea. If mixed with blood, the CSF leak can be identified by looking for the "halo sign." A drop of nasal drainage is allowed to fall on a surgical towel. If the halo spreading from the central blood clot is more than double the width of the clot, then this is a sign of a CSF leak and thus an anterior dural tear.

3. Frontonasal Duct Fractures

Fractures of the frontonasal duct have no particularly distinguishing clinical diagnostic features and are usually picked up on a CT scan. Though the actual fracture may not be seen, an opacified frontal sinus that does not clear in 2 weeks raises a strong suspicion of disruption of the duct. The duct is often fractured as part of a Le Fort III maxillary fracture.

If at 2 weeks the sinus does not clear, a test can be done to establish patency of the duct. A small trephine hole in the floor of the sinus is made through a small incision in or just below the brow. The sinus is irrigated through the trephine with a saline solution containing cocaine or epinephrine. A solution containing methylene blue is instilled in the sinus, and the appearance of the dye in the middle meatus of the nose is observed with a sinus endoscope. The appearance of the dye indicates duct patency; the dye's absence is an indication for surgery.

4. Corner Fractures

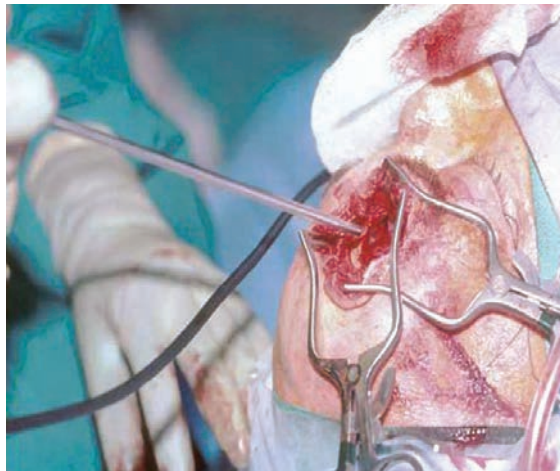
A corner fracture is usually not displaced. The anterior wall, floor, and posterior wall are fractured, and the corner fracture is normally in continuity with a more extensive fracture to the frontal bone. Corner fractures usually require no treatment.

5. Through-and-Through Fractures

The through-and-through fracture is the most serious of all frontal sinus fractures. It is a compound comminuted fracture involving the anterior and posterior walls, entering the anterior cranial fossa (Figure 3.2). The skin is torn—often extensively, the dura is ripped, and the frontal lobes

Figure 3.2

Endoscopic inspection of the frontonasal duct. View through fractured anterior wall of trephine.



are lacerated and contused. The patients are usually the victims of polytrauma. Approximately 50 percent of patients die at the scene of the injury or in the first 24 hours of hospitalization.

Characteristically the head and neck surgeon does not meet the patients until they arrive in the operating room at the behest of the operating neurological surgeon, who is busy stopping intracerebral bleeding and debriding the wound. A bicoronal scalp incision has already been made, the fractured skull fragments have been removed, and the injury has been exposed. Although one might think that the frontal sinus fracture is the least of the patient's worries, in fact, if not managed properly and the patient survives the initial injury, it will sit as a ticking time bomb, forming a mucocele that eventually causes a brain abscess or meningitis.

D. MANAGEMENT

Many frontal sinus fractures come to the emergency room with fractures of multiple walls. However, each site presents unique problems that invoke a specific solution or a choice of solutions in order to appropriately address the injury. In fractures of multiple walls, the final treatment must address the idiosyncracies of each site.

1. Anterior Wall Fractures

Nondisplaced frontal sinus fractures do not require any surgical intervention. Displaced fractures should be reduced for two principal reasons. The most important is that if there is any entrapped mucosa between the edges of the fracture, there is the potential to develop a mucocele. The second reason is to prevent the inevitable deformity of a dent in the forehead that will result if the displaced fragment is not properly reduced.

If the fracture is compounded, it can sometimes be reduced through an overlying laceration. If the laceration is too small to effectively reduce the fracture, then additional exposure can be gained by extending the laceration horizontally along a natural crease line in the forehead skin. The two other incisions that can be used are the "gull-wing" or "butterfly" incision in a glabellar crease connected to the upper medial aspects of the eyebrows. This incision is best applied in patients with short sinuses or in bald men. The coronal scalp flap provides the best surgical exposure and is the most commonly used.

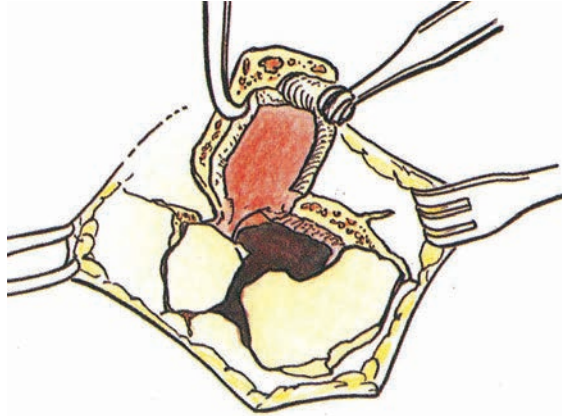
The fracture fragments are disimpacted with a stout bone hook and, as much as possible, the bone fragments are left with periosteum as a vascular pedicle. A mucosal strip adjacent to the fracture is incised and

CHAPTER 3: Upper Facial Trauma

removed, and a thin layer of the underlying bone is resected with a diamond bur (Figure 3.3). The fracture fragments are fixed in place with a series of miniplates and square plates.

Figure 3.3

Mucosa and bone are removed from the margins of the fracture fragments.



2. Posterior Wall Fractures

Management of posterior wall fractures is the most controversial of all the fracture sites. The major issue is whether the fragments are displaced. With the advent of fine-cut CT scanning, this dilemma is more easily resolved.

Linear fractures can be safely observed. The detection of displacement as well as an idea of the patency of the frontonasal duct can be determined by making a small trephine hole in the sinus floor through the upper lid and passing an angled telescope through the trephine hole. Posterior wall displacement as well as the presence of a CSF leak can be determined.

If any doubt concerning posterior wall displacement exists, frontal sinus exploration is indicated. This is usually done through a coronal scalp incision, then creating an osteoplastic bone flap of the anterior wall of the frontal sinus. A clear view of the interior of the sinus is obtained, and any disruption of the posterior wall is identified. If a CSF leak is seen, the limits of the anterior fossa dural rent are exposed by removing posterior wall bone. The dural tear is closed with interrupted sutures, and the area is reinforced with a patch of fascia lata or temporalis fascia (Figures 3.4 and 3.5).

If an area of bone greater than 2 centimeters in diameter is removed, the anticipated sinus drillout and obliteration with fat are abandoned, and a frontal sinus cranialization procedure is performed. If fat grafting

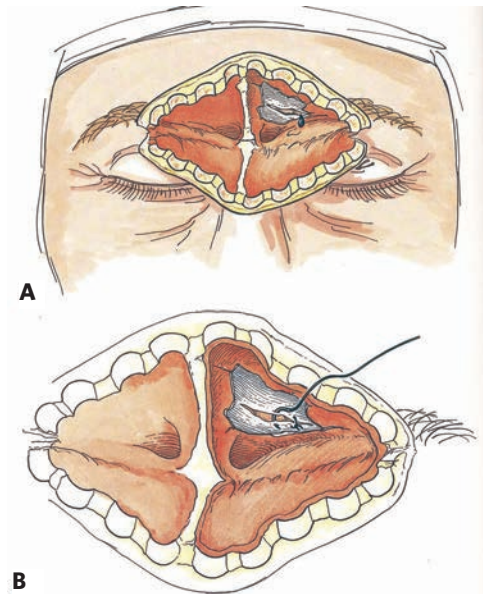


Figure 3.4

Suture of dural laceration in posterior wall frontal sinus with CSF leakage. (A) Dural laceration. (B) Fractured bone debrided until limits of dural rent are apparent; tear is sutured with interrupted sutures.

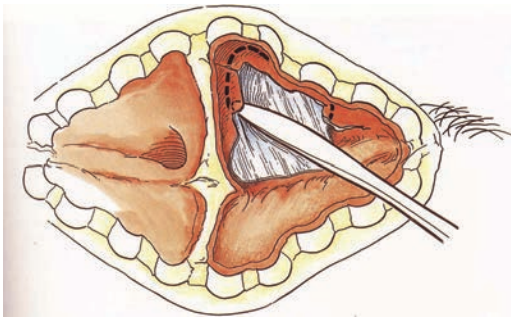


Figure 3.5

Fascia graft being tucked into position to stem CSF leak in a posterior wall fracture.

and obliteration of the sinus are preformed, then careful attention to complete removal of all mucosa is mandatory. The drilling of the bone of the interior of the sinus is essential to remove all remnants of mucosal lining prior to obliteration of the sinus cavity with a carefully harvested abdominal wall fat graft.

3. Frontonasal Duct Fractures

Fractures to the outflow tract from the frontal sinus are very difficult to diagnose. There are no idiosyncratic signs or symptoms that are manifested in these fractures. When suspected by retained fluid in the sinus after a 2-week period of observation or demonstration of such a fracture on the facial CT scan, the frontal sinus must be addressed.

CHAPTER 3: Upper Facial Trauma

The sinus can be managed either endoscopically or by an open operation. The reestablishment of ductal patency has thwarted frontal sinus surgeons for over 100 years.⁴ All methods of opening the frontal sinus floor to the nasal cavity have been attempted with varying degrees of success. Currently, the use of the Draf III endoscopic version of the Lothrop operation⁵ has become very popular. The two classic open techniques are the Lynch operation using the Sewell-Boyden flap to line the widely open tract, and the osteoplastic flap procedure with fat obliteration.

The Draf III uses classical fiberoptic endoscopic evaluation of swallowing (FESS) techniques to remove the frontal sinus floor, the superior part of the nasal septum and the so-called “beak” area of the anterior frontal sinus floor. Because the technique causes a minimum amount of trauma in the resection area, theoretically, the opening is more likely to stay open.

The Lynch operation uses a curvilinear incision starting in the medial brow, and courses through the so-called “nasojugal area,” half way between the medial canthus of the eye and the mid-line of the nasal dorsum. The ethmoid sinuses and the entire area of the frontonasal duct, as well as the floor of the frontal sinus, are removed. The Sewell-Boyden flap is constructed from the nasal septum medially or the lateral nasal wall anterior to the turbinates. The flap is then used to line the opening in the frontal sinus floor. The most reliable way to repair a duct fracture is to eliminate the frontal sinus entirely with the osteoplastic flap and fat obliteration procedure.

4. Through-and-Through Fractures

This devastating injury was formerly managed by the neurosurgeon by craniectomy, often discarding the skull fragments because of their contamination at the scene of the accident, and not cleansing them and restoration of the cranial vault because of the concern of brain swelling. The otolaryngologist classically did a Riedel ablation, with the two procedures leaving the patient with unprotected brain as well as a significant cosmetic defect.

In 1975, Donald and Bernstein⁶ and Derome and Merville⁷ described the cranialization procedure for these through-and-through fractures. The neurosurgeon controls the intracranial problems by stopping the intracranial bleeding, debriding necrotic brain, and providing a water-tight dural repair.

The otolaryngic procedure regarding the frontal sinus injury is made easy by virtue of the extensive craniotomy needed for controlling the intracranial injury. The initial step in the procedure is to ensure all the bony fragments from the anterior wall of the frontal sinus have been saved. These are divested of dirt and soaked in Betadine® until the end of the procedure. The posterior wall of the sinus is completely removed, so that the cavity of the frontal sinus is now in continuity with the anterior cranial fossa. This is begun with a double-action rongeur and is finished off with a cutting burr (Figure 3.6). The frontal sinus mucosa is now completely stripped out with an elevator from the floor and remaining anterior wall, such that the remaining sinus cavity is completely divested of mucosa. Total removal of all mucosal remnants of the sinus is ensured by removing 1–2 millimeters of bone with a cutting burr (Figure 3.7).

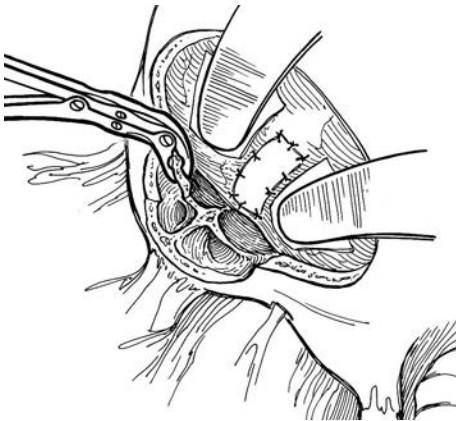


Figure 3.6

Cranialization procedure—Brain is debrided, dura is patched, and posterior wall remnants are removed with double-action rongeur.

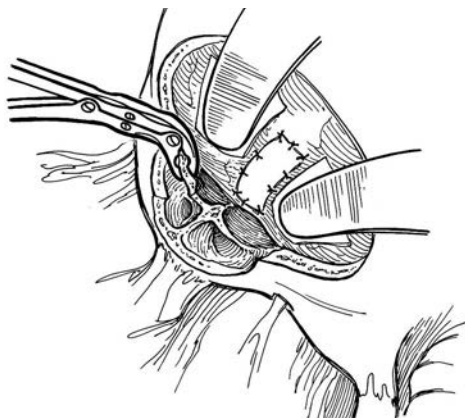


Figure 3.7

Cranialization procedure—Removal of the remaining posterior wall of the frontal sinus produces cranialization.

CHAPTER 3: Upper Facial Trauma

The frontonasal duct is eliminated by inverting the frontal sinus mucosa left in the funnel-shaped entrance to the duct upon itself, and then obliterating the duct with a block of temporalis muscle (Figure 3.8). The cleansed anterior wall fragments are similarly divested of all their mucosa with a cutting bur, and then fixed in place with square plates and miniplates (Figure 3.9). The scalp is closed and a light-pressure dressing is applied.

Figure 3.8

Cranialization procedure—The mucosa of the sinus is removed from the sinus lumen, the frontonasal duct mucosa is inverted on itself, and the frontonasal ducts are plugged with temporalis muscle.

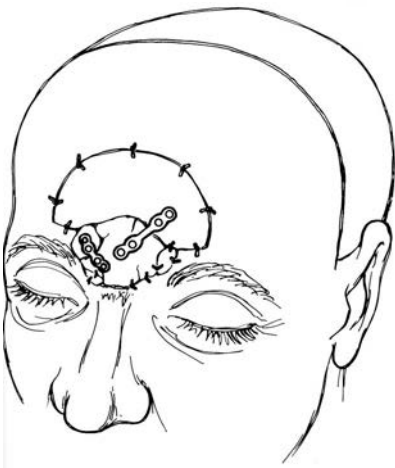
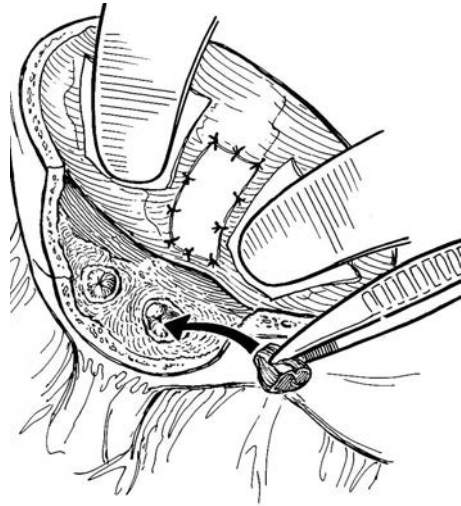


Figure 3.9

Cranialization procedure—Craniotomy returned with wire and fragments of the frontal sinus fixed with plates.

The dead space resulting from the enlargement of the anterior fossa rapidly fills with blood, but usually there is some degree of residual hydrocephalus. Early brain edema will add to the effacement of the space. The brain slowly advances into the space with time, as the dural graft stretches and the dead space is eliminated in about 3 months. The frontal sinus is thus eliminated as a potential source of infection, and the esthetic contour of the forehead is preserved (Figure 3.10).

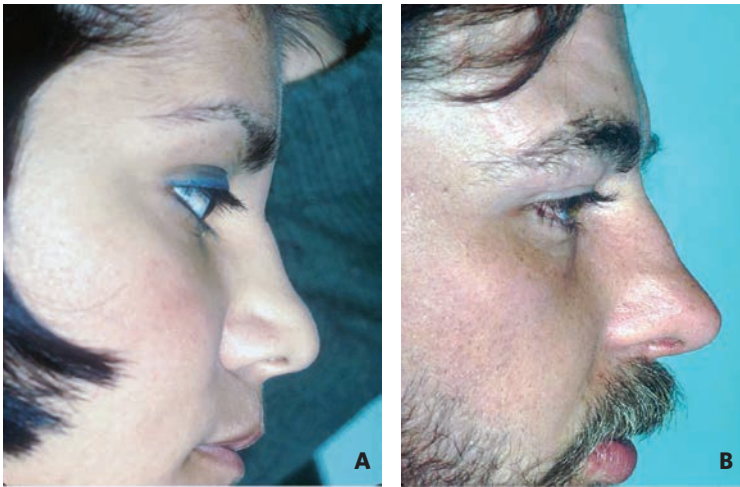


Figure 3.10

Two patients, (A) 2 years and (B) 4 years post-cranialization.

II. Naso-orbital-ethmoid Fractures

Fractures of the naso-orbital-ethmoid (NOE) region are typically due to blunt trauma injuries. Etiologies may range from motor vehicle accidents to falls and sports, but the force and focus of the blow determine the extent of the injuries to the structures located in this region of the face, including the orbital contents and the anterior skull base structures. The extent of the injuries, based on physical examination and imaging studies, will determine the urgency and type(s) of surgical interventions required. As with all facial injuries, a thorough knowledge of three-dimensional facial anatomy is a requirement, as is an understanding of the diagnostic tests and modalities utilized in diagnosing the injuries of NOE trauma. NOE fractures can be isolated, but are usually part of a panfacial set of fractures and injuries.

CHAPTER 3: Upper Facial Trauma

A. ANATOMIC STRUCTURES OF THE NOE COMPLEX

NOE fractures can involve damage to multiple important osseous, vascular, cranial nerve, and supporting structures located within the NOE complex, including:

- Nasal bones (Figure 3.11).
- Perpendicular plate of the ethmoid/septum.
- Nasal process of the frontal bone.
- Cribriform plate and olfactory nerve.
- Lamina papyracea, medial orbit, ethmoid sinus.
- Orbital fat, medial rectus muscle, superior oblique muscle with trochlea.
- Ethmoid arteries, ethmoid nerves.
- Medial canthal attachments (Figure 3.12).
- Lacrimal fossa, lacrimal sac, superior and inferior canaliculi, superior portion of the nasal-lacrimal duct (Figure 3.13).
- Nasal process of the maxilla and lateral-superior nasal wall.

Figure 3.11

NOE pertinent osteology—(1) nasal process of frontal bone; (2) nasal bones; (3) nasal process of maxilla; (4) lacrimal bone; (5) lamina papyracea; (6) lesser wing of sphenoid bone.

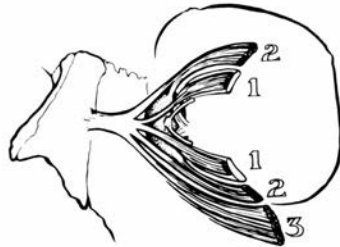
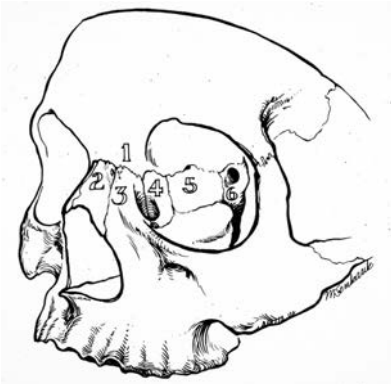
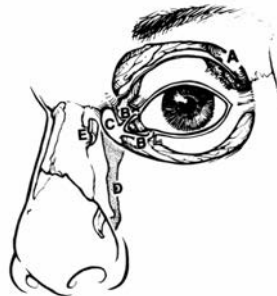
Figure 3.12

Anterior and posterior slips of the medial canthal tendon surrounding the lacrimal sac—(1) pretarsal orbicularis muscle; (2) preseptal orbicularis muscle; (3) preorbital orbicularis muscle.

Figure 3.13

Nasal lacrimal system anatomy—(A) lacrimal gland; (B) superior and inferior canaliculi; (C) lacrimal sac; (D) nasolacrimal duct; (E) reflected anterior slip of medial canthal tendon.



B. INDICATIONS OF INJURY TO THE NOE COMPLEX STRUCTURES

In general, the subjective symptoms and objective signs of injuries to the NOE complex will reflect the pathology evidenced by the specific structures that are injured.

1. Symptoms (Subjective)

The subjective symptoms of injuries to the NOE complex include the following:

- Diplopia.
- Nasal stuffiness.
- Epistaxis.
- Visual disturbances.
- Pain.
- Dizziness, vertigo.
- Anosmia.

2. Signs (Objective)

a. Traumatic Telecanthus

The average interpupillary distance is 60–62 millimeters (mm), which corresponds to an intercanthal distance of approximately 30–31 mm. The diagnosis of traumatic telecanthus requires a measurement in excess of those normative values (Figures 3.14 and 3.15). The pathology can be either unilateral or bilateral, with the former more difficult to measure.

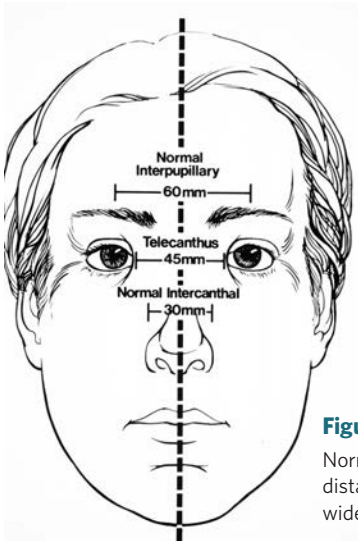


Figure 3.14

Normal interpupillary and intercanthal distances, and traumatic telecanthus widening.

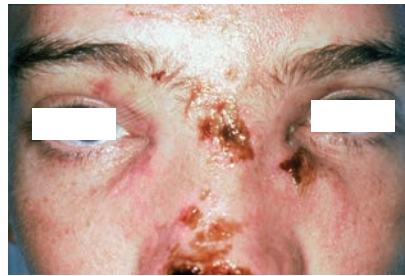

Figure 3.15

Patient demonstrating traumatic telecanthus with splaying of the NOE complex.

CHAPTER 3: Upper Facial Trauma

b. Diplopia

Double vision elicited on extraocular motion in the cardinal positions of gaze can be due to injuries to the medial rectus muscle, superior oblique muscle and/or trochlear slip, oculomotor nerve, trochlear nerve, and entrapment of medial orbital structures into a fracture of the lamina papyracea. Nerve injury is usually a neuropraxia, so if forced duction tests are normal, observation is warranted.

c. Nasal Stuffiness

Nasal stuffiness occurs with blood in the nasal cavity; septal hematoma (which is less likely with injuries of the bony perpendicular plate of the septum than the cartilaginous septum); compression of the upper nasal passages, with infracturing of the nasal bones; and generalized mucosal edema.

d. Epistaxis

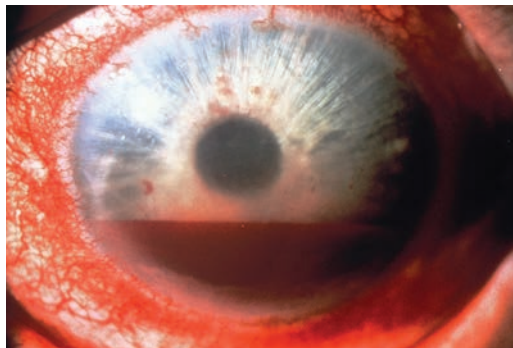Epistaxis is quite common with NOE fractures. It usually represents the disruption of the nasal mucoperiosteum caused by the blunt trauma or shearing forces and displaced bony fractures. Severe epistaxis may indicate disruption of the ethmoid arteries and/or the sphenopalatine arteries; the latter is less likely, due to the more inferior location of the sphenopalatine arteries in the nasal cavity.

e. Visual Disturbances

Visual disturbances are common with NOE fractures. They are often due to orbital edema, periocular swelling, and injury to the medial orbital muscles and nerves. Non-diplopia signs include a dilated pupil or Marcus-Gunn pupil, indicating injury to the optic nerve. The cornea may be disrupted, abraded, or lacerated, and hyphema (Figure 3.16) is very common with blunt mid-facial trauma. A dislocated ocular lens is rare,

Figure 3.16

Hyphema of the globe is seen as layered blood in the anterior chamber.



but possible (Figure 3.17). Rupture of the globe is also a rare, but devastating, injury.

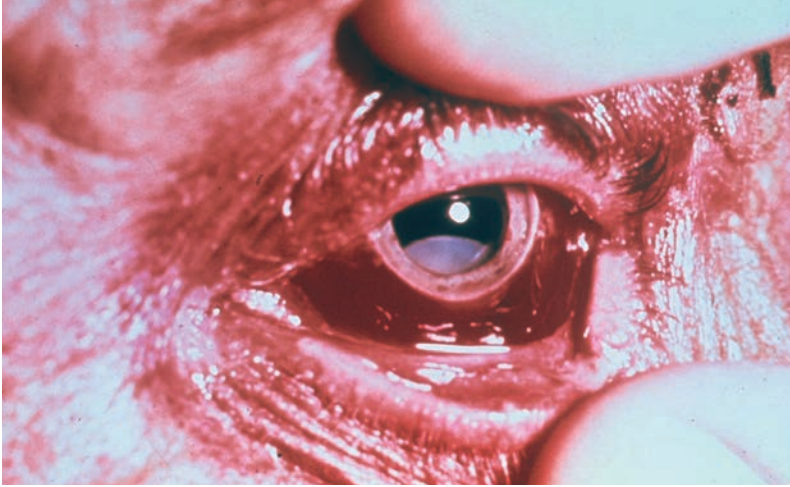


Figure 3.17

Dislocated lens seen displaced to inferior portion of anterior chamber of the globe.

f. Imbalance

Imbalance may be present in patients with NOE injuries, primarily in patients with serious trauma to the face that can cause a concussion, anterior skull base contusion, cerebral edema, or injury to the medial longitudinal fasciculus. Contrecoup injuries to the brainstem and vestibular/cerebellar pathways may have occurred; these signs are ominous for more serious intracranial pathology. Nystagmus may be a feature of contrecoup trauma.

g. Anosmia

Anosmia is another worrisome sign. If the patient fails to perceive the smell of common scents, such as soap or alcohol, further investigation is warranted. The cause may simply be an accumulation of blood, mucus, and swollen nasal membranes, but could also be due to a disruption of the olfactory nerve at the level of the cribriform plate. If this injury is suspected, the patient should be tested for CSF rhinorrhea, using filter paper in the front-leaning-head position or collected and tested for beta-2 transferrin.

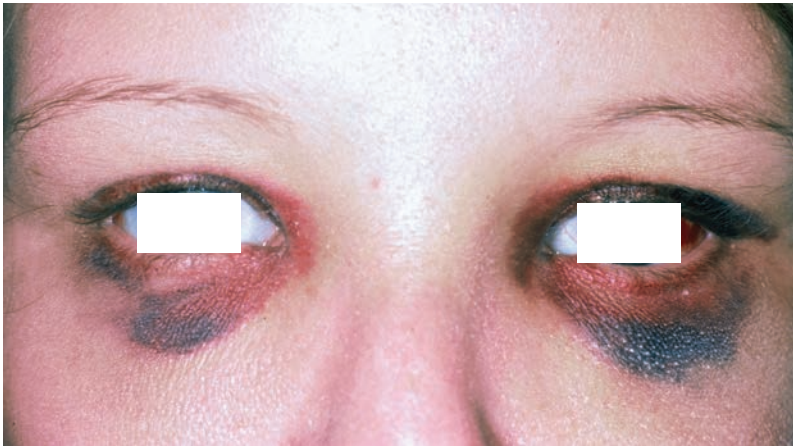
CHAPTER 3: Upper Facial Trauma

h. Periorbital Ecchymosis

Periorbital ecchymosis (“raccoon eyes”) is a common indicator of ruptured blood vessels—usually the ethmoid arteries and/or the angular artery and vein near the medial canthus (Figure 3.18). It can also be suggestive of a basilar skull fracture, which must be ruled out through diagnostic imaging.

Figure 3.18

Bilateral periorbital ecchymoses.



i. Retrobulbar Hematoma

Retrobulbar hematoma is a very serious condition, in which periglobal blood vessels have been ruptured and blood accumulates around or within the muscular cone. The patient will complain of pain, decreasing vision, and pressure, and may have nausea and vomiting. There will be obvious proptosis and a firm globe to gentle palpation, compared to the normal side.

This is a true emergency. Ophthalmologic consultation is mandatory. However, owing to the laxity that generally occurs with a lateral splaying of the medial canthal tendons, there is a natural release to the intraorbital pressure caused by the expanding hematoma. Nevertheless, this will not last long, and intervention should be undertaken as soon as diagnosed.

j. Epiphora

Epiphora is usually due to tissue edema surrounding the medial eyelids. However, fractures and soft tissue injuries involving the lacrimal

drainage system will produce epiphora, which requires further evaluation with lacrimal probing at the time of the surgical repair.

C. CLASSIFICATION OF MEDIAL CANTHAL TENDON INJURIES

Medial canthal tendon injuries are classified according to three types:

- **Type I:** Single-fragment bone segment with intact canthal tendon insertions (Figure 3.19).
- **Type II:** Comminuted central bone segment with fractures remaining external to the medial canthal tendon insertion (Figure 3.20).
- **Type III:** Comminuted single fragment with fractures extending into bone bearing the canthal insertion.

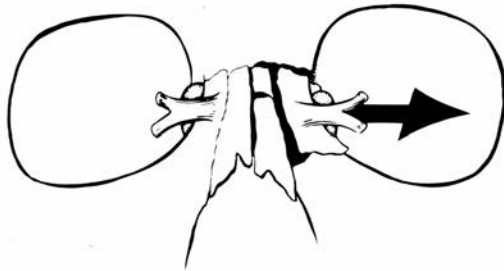


Figure 3.19

Type I medial canthal region fracture, unilateral.

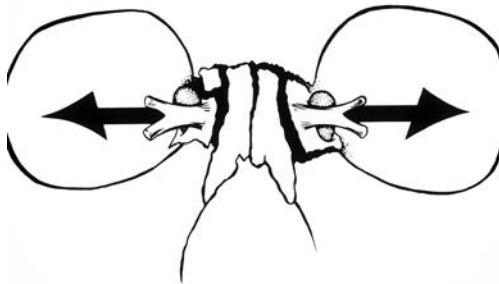


Figure 3.20

Type II medial canthal region comminuted fracture, right medial orbit.

The injury type can be identified on imaging studies and confirmed at surgical exploration and repair.

Though uncommon, blunt trauma can also result in a rupture of the anterior and/or posterior insertions of the canthal slips near their insertion on the lacrimal fossa. It would be seen in the lax eyelid, without evidence of distracted lacrimal fossa fractures.

D. LACRIMAL SYSTEM INJURIES

Laceration of the medial eyelids with discontinuity of the lacrimal canaliculi will be seen in vertical lacerations medial to the puncta. Deep

CHAPTER 3: Upper Facial Trauma

horizontal lacerations at the medial canthus can also disrupt the canaliculi but are less common.

Fracture(s) that involve the lacrimal fossa can rupture the lacrimal sac or avulse the common canaliculus from the lacrimal sac. This may only be identified by inserting a lacrimal probe into the system via the upper and/or lower puncta and noting a failure of the probe to pass easily into the lacrimal sac.

The floor of the lacrimal fossa contains the opening to the superior portion of the lacrimal duct. Fractures involving this region can be subtle. Unless identified on imaging or suspected from the location of the fractures, they can be overlooked, leading to persistent epiphora.

Identifying patency of the nasolacrimal system after NOE injuries usually necessitates performing primary and secondary Jones dye tests.

1. Primary Jones Dye Test

a. Test Procedure

- Instill one drop of fluorescein in the inferior cul-de-sac of the lower eyelid
- Insert a cotton pledget minimally soaked in a topical anesthetic, such as 2 percent lidocaine beneath the inferior turbinate.
- After 5 minutes, remove the pledget and examine for fluorescein.

b. Interpreting Test Results

- If fluorescein is present, then this is a positive primary Jones dye test, indicating that the lacrimal drainage system is patent.
- If fluorescein is not present, this is a negative primary Jones dye test, and further testing is required to determine the level of obstruction.

2. Secondary Jones Dye Test

a. Test Procedure

- Place a clean cotton pledget beneath the inferior turbinate.
- Flush the fluorescein from the cul-de-sac with saline.
- Irrigate the lacrimal sac via the inferior canaliculus using a special blunt canalicular needle and syringe.

b. Interpreting Test Results

- If fluorescein is identified on the fresh pledget, then this is a positive secondary Jones dye test, indicating a functional obstruction in the nasolacrimal duct.
- If no dye is present on the pledget, but saline is observed, then this is a negative secondary Jones dye test, indicating pathology at the lacrimal punctum or canaliculus.

- If no saline is observed after irrigation, there is a complete blockage of the nasolacrimal system at some level, which should be obvious from the extent of the traumatic pathology.

E. ISOLATED ORBITAL FRACTURES

Typically, orbital fractures in NOE injuries are isolated to the region of the lamina papyracea and inferior-medial orbit. While medial orbital fractures can result in entrapment of periosteum, fat, and ocular muscle, it is not common because of the lack of gravitational force and because the ethmoid cells provide an additional support to the lamina. When entrapment does occur, it must be differentiated from a neuropraxia of the oculomotor nerve to the medial rectus by forced duction testing.

F. DIAGNOSTIC EVALUATIONS

1. Full-Body Trauma Assessment

Like most patients with facial trauma, it is usually necessary for the trauma team to clear the patient from more serious injuries before the full evaluation and decision-making process on the facial trauma can take place. This includes the full-body trauma assessment, particularly of the circulation, airway, breathing, and neuro status, as well as the remainder of the bodily assessment. It is helpful for the otolaryngology resident to be present for this total body trauma assessment, as positive findings will impact the evaluation and treatment of facial fractures. Additionally, after the primary and secondary assessments, the otolaryngology resident will be able to focus specifically on a detailed head and neck examination.

2. Head and Neck Examination

Particularly pertinent to NOE injuries, the head and neck examination should closely assess neurological status, nasal airway, vision (including pupillary examination and range of motion), CSF leak, epistaxis, nasal airway patency, and eyelid tension. Eyelid tension, when tested with the “bowstring test,” may demonstrate a laxity of the medial canthal tendon when the eyelid is grasped by eyelashes and pulled laterally. A normal attachment of the medial canthal tendon will demonstrate a firm resistance to distraction, while a disrupted attachment will feel lax. Since isolated NOE fractures are not common, but more often are a part of panfacial fractures, the entire facial skeleton must be adequately evaluated.

3. Ophthalmological Evaluation

Any trauma at or around the orbit justifies an ophthalmological evaluation, preferably before any surgical procedure is planned. An

CHAPTER 3: Upper Facial Trauma

undiagnosed ocular or periocular injury could further jeopardize vision through incomplete evaluation and premature surgery. In particular, the presence of a hyphema in the anterior chamber, dislocated lens, corneal or scleral laceration, or retinal injury will require postponement of the surgical procedure until the eye is cleared by the ophthalmologist.

4. Inspection of the Nasal Interior

Inspection of the nasal interior, particularly the superior and superior-posterior aspects, should be performed with a rigid or flexible nasal scope after suctioning and decongestion. It is important to identify any areas of obvious hematoma, tearing or rents of the mucosa, and intranasally exposed bone. Additionally, after decongestion (preferably with cotton pledgets), the patient's sense of smell can be tested with a common scent or a scratch-and-sniff test. Care should be taken during the examination to avoid the immediate area of the cribriform plate.

5. Interpupillary and Intercanthal Distance Measurements

The interpupillary and intercanthal distances should be measured to determine if traumatic telecanthus is present (see section II.B.2.a, above). If the intercanthal distance is significantly widened, and not thought to be just soft tissue edema or hematoma, there is a good chance that the lacrimal drainage system has also been disrupted.

6. Imaging Studies

Imaging studies are clearly indicated in patients with NOE injuries. A head CT scan may have already been performed by the trauma or neuro team. Nevertheless, it is important to assess the NOE complex and anterior base of the skull well with fine cuts. If the head and neck examination raises a suspicion of additional facial injuries, then a complete facial bone series would be in order. Both soft tissue and bone windows for the CT scan of the face and anterior skull base will be helpful to identify injuries to the orbit, medial canthal region, cribriform plate region, floor of the frontal sinus (outflow), and periorbital structures. Additionally, the integrity of the lacrimal fossa and nasolacrimal duct can be assessed.

7. Forced Duction Testing

Forced duction testing after application of topical ophthalmic anesthetic will be very helpful in differentiating true entrapment of medial orbital structures from neuropraxia and muscle edema and contusion. This test is usually performed preoperatively to ascertain whether a surgical procedure to reduce the entrapped tissues will be required. After application of topical anesthesia (tetracaine hydrochloride 0.5 percent ophthalmic solution), which takes effect usually within 15 seconds, the

region of the attachment of the medial rectus muscle to the sclera is grasped with a fine-toothed ophthalmic forceps (Figure 3.21). The globe is then rotated laterally to determine whether there is resistance to, or

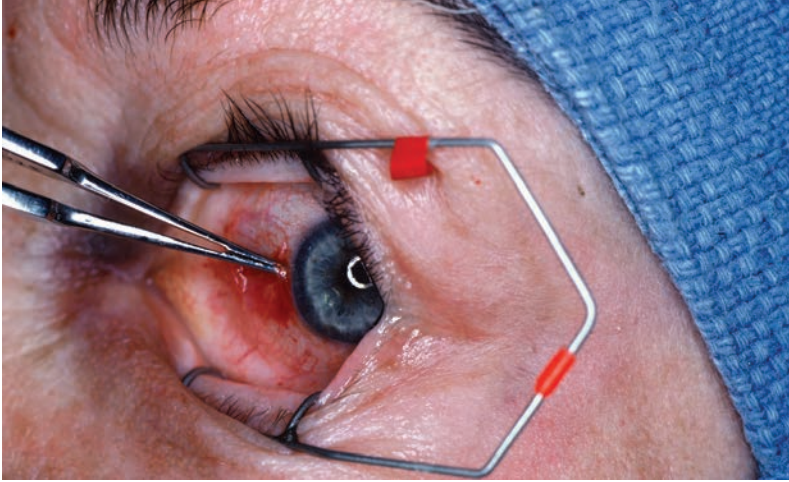


Figure 3.21

In forced duction testing, the area of the insertion of the medial rectus muscle to the sclera is grasped with a fine-toothed forceps and rotated laterally.

limitation of, rotation. If there is resistance or limitation, in comparison to the uninjured side, entrapment of the muscle is presumed. If patients have difficulty keeping their eyelids open, then a wire eyelid speculum (retractor) can be used. In combination with imaging evidence of entrapment, the forced duction test is indication for medial orbital exploration.

8. Plain Radiographs of the Face

Plain radiographs of the face are rarely helpful, unless no sophisticated imaging system is available at the site of the patient's initial evaluation. A complete head and neck examination will be of more benefit than plain radiographs in developing a differential diagnosis of the patient's injuries. However, if the CT scanner is not available, then a Caldwell view of the facial bones is better than no imaging as a screen for disruption of the NOE complex.

9. Digital Photographs

Finally, with the patient's permission, if the resident and site have the capability, digital photographs should be taken and stored in a secure place according to the Health Insurance Portability and Accountability

CHAPTER 3: Upper Facial Trauma

Act of 1996 (HIPAA) regulations. These photographs are invaluable for planning the patient's subsequent secondary reconstruction, if needed, and for teaching and educational purposes. Each hospital facility generally has guidelines and rules for operative photography; typically hospitals ban using cell phone photography. A dedicated patient photography camera should be used. Using digital photography has multiple benefits, including planning the surgical procedure with the attending otolaryngologist, documenting injuries for possible subsequent legal proceedings (assault and battery), planning follow-on reconstructive procedures, and using the images for medical education.

G. SURGICAL MANAGEMENT

1. Indications for Surgery

- Compressed NOE complex.
- Traumatic telecanthus (widened NOE complex), unilateral or bilateral.
- Persistent epistaxis, despite local hemostatic measures.
- Medial orbital fracture with entrapment demonstrated on forced duction testing.
- Fracture(s) seen on imaging studies of the floor of the frontal sinus, which could block outflow.
- Fractures of the NOE involving the medial canthal tendons.
- Disruption of the lacrimal fossa and superior nasolacrimal duct.
- Obvious injury to the region of the lacrimal canaliculi.
- Evidence of a developing retrobulbar hematoma, which requires urgent ophthalmologic intervention.
- CSF rhinorrhea due to a fracture of the cribriform plate or posterior wall of the inferior frontal sinus seen on imaging studies.

2. Timing of Surgical Procedures

Fortunately, with NOE complex fractures, there is usually sufficient time before repair to adequately assess the patient's injuries, initiate intravenous antibiotic therapy, observe the patient if there is any concern about CNS symptoms or signs, and properly prepare the operating room for the procedures. This means that most NOE fracture patients will not need to be operated on immediately, but may wait up to 48 hours, if needed, for the best possible approach. Only conditions such as retrobulbar hematoma, unrelenting nasal bleeding, or a perforated globe will require urgent surgery.

3. Surgical Exposure Options

Because most central facial fractures, such as NOE fractures, usually have nasal bleeding as a general component, the patient may have

swallowed a good deal of blood. This should be taken into consideration, as well as how long ago the patient ate and drank, when scheduling a reconstructive surgical procedure. If there is serious bleeding that will require intraoperative packing or clipping/cautery of an ethmoid or sphenopalatine artery, the patient may have to be intubated awake, followed by oral-gastric tube aspiration of stomach contents.

a. Primary Objectives of the Surgical Repair/Reconstruction of the NOE Complex

- Stop nasal bleeding through compression and/or clipping/cautery of vessels as needed.
- Reduce the compressed and widened NOE bones and splint or fixate them into proper position. Reduce any fracture edges that may be involving the cribriform plate.
- Re-establish normal intercanthal distance and maintain it in proper position for healing, usually by internal fixation.
- Re-establish continuity to the nasolacrimal drainage system through closure of lacerations and internal stenting.
- Reduce medial orbital entrapped tissues, if present, while protecting the globe.
- Explore and repair frontal sinus floor and/or posterior sinus wall fractures as required.
- Re-attach the trochlea of the superior oblique muscle if it has been disrupted from its normal osseous/periosteal attachment.
- Re-establish a normal frontal and profile appearance to the NOE complex region.
- Repair any lacerations with a fine plastic closure, especially those that may be used for exposure of the fractures.
- Repair CSF leak at the anterior skull base, if conservative measures and time have not led to closure.

b. Multiple Surgical Approaches

There are multiple surgical approaches to reconstruct the NOE complex fractures, depending on the extent of the injuries and the structures involved.

i. Lacerations

If one or more lacerations are located in the NOE complex, it may be possible to expose the fractures and associated injured structures through these lacerations. Often, the lacerations are not well placed and may need to be extended or entirely not utilized for exposure. A fine-plastic closure of the lacerations, whether used for exposure or not, will be necessary. It is usually best to defer plastic closure of the

CHAPTER 3: Upper Facial Trauma

lacerations to the end of the operation, to prevent inadvertent dehiscence during repair of the bony fractures.

ii. Transconjunctival Approach

The transconjunctival approach can be utilized for isolated medial wall orbital blowout fractures with entrapment of a small amount of orbital fat or medial rectus muscle. The incision usually is placed posterior to the caruncle, and has very limited exposure to other sites of the NOE complex. However, if a medial orbital fracture is found to extend to the inferior orbital wall, this incision may be extended to expose that area.

iii. Transcaruncular Approach

A transcaruncular approach is similar to the transconjunctival approach, except that the incision is placed anterior to the caruncle, which is elevated with the soft tissue flap. The medial orbital periosteum is incised just posterior to the posterior lacrimal crest, and the dissection carefully proceeds back to the posterior ethmoid artery. It provides a slightly better visualization of the medial orbit, but is insufficient to provide exposure for repair of more extensive fractures of the complex.

iv. Extended Medial Canthal/Lateral Nasal Approach

An extended medial canthal/lateral nasal approach is often utilized to reduce and fixate the NOE complex fractures and to reconform the medial canthal tendons to their proper position. The incision is usually gull-wing shaped, placed approximately 8–10 mm from the inner palpebral angle, extending superiorly and inferiorly for approximately 15–20 mm (Figure 3.22). The periosteum can be elevated laterally, exposing the lacrimal fossa, medial orbit (lamina papyracea), and

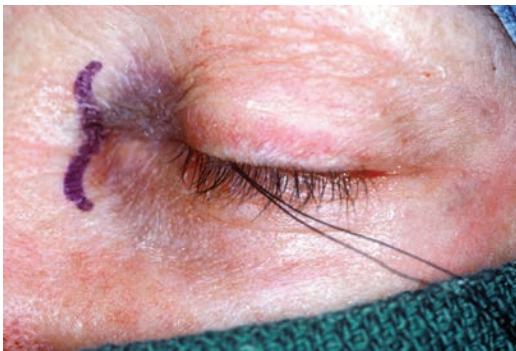

Figure 3.22 (right)

Gull-wing medial canthus incision in patient. Silk suture is around the body of the medial rectus muscle for traction in dissection for entrapment.

ethmoid arteries (Figures 3.23 and 3.24). The exposure is sufficient to reduce medial orbit entrapments and fixate the intercanthal distance to the proper width (Figures 3.25 and 3.26). The incision can be extended superiorly (as with a Lynch incision) to expose the region of the trochlear slip, if that structure needs repair, or can be reattached to the superior-medial orbital wall. If the incision is extended much beyond 1 centimeter, it is wise to incorporate a small Z-plasty to reduce the risk of web formation in this concave anatomic area.

Figure 3.23

Medial canthal incisions to approach medial orbital fracture—double Z-plasty on the right, and gull-wing incision on the left.

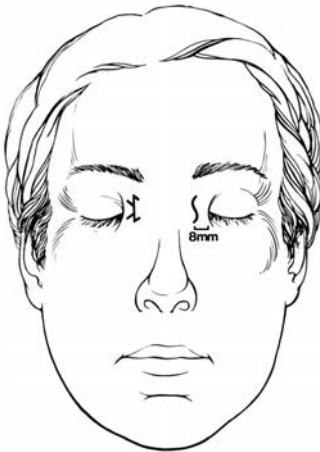


Figure 3.25

Traction on the medial rectus muscle to release entrapment in medial orbital fracture.

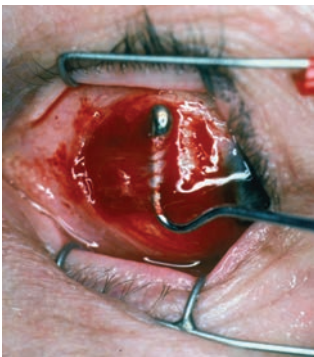


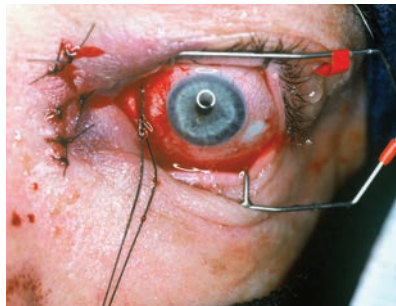
Figure 3.24

Exposure of the left medial orbital fracture for repair and release of entrapped orbital tissue, as viewed from patient's right side.

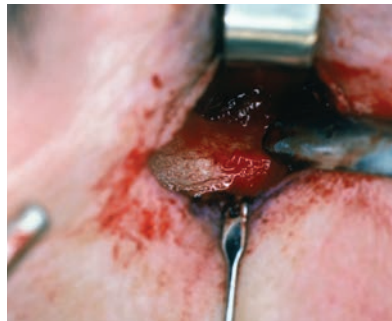

Figure 3.26 (left)

Completion of medial orbital repair and release of orbital contents.



CHAPTER 3: Upper Facial Trauma

v. Bifrontal (Coronal) Forehead Flap

For severe NOE fractures that involve the anterior skull base, nasal process of the frontal bone, inferior/anterior/posterior frontal sinus or that extend into the cribriform plate, it is usually necessary to approach the reconstruction through a bifrontal (coronal) forehead flap, elevating in the subperiosteal plane. This exposure will also allow for repair of an avulsed trochlea, and obliteration of the frontal sinus, if indicated.

4. Reconstructive Options

The reconstruction of NOE injuries usually involves the reduction and fixation of the nasal bones, medial orbit, nasolacrimal system, and medial canthal tendons, with the goals to obtain near-normal appearance and function, as well as to reduce immediate and late complications.

a. NOE Fracture Reduction

Reduction of the NOE fractures in the operating room is normally a simple maneuver of manually compressing the splayed fractures at the level of the medial canthi to obtain a more normal intercanthal distance, based on half of the patient's interpupillary distance. Often, this reduction sufficiently produces adequate NOE anterior/profile projection, and the bones maintain their position without internal fixation. Only an external nasal cast may be required in most patients. Typically, the nasal bones will also be fractured inferior to the NOE complex, so these need to be reduced properly, as well, as described in Chapter 4 of this Resident Manual. It is also helpful to have decongested the nasal mucosa with topical oxymetazoline hydrochloride (0.25 percent), with or without 4 percent lidocaine hydrochloride, prior to the closed reduction.

b. Nasal Bone Reduction

During the closed reduction process, if the nasal and ethmoid processes of the frontal and maxillary bones have also been compressed posteriorly, it might be necessary to insert the blades of an Asch forceps into the superior nasal region to assist with the anterior distraction of the fragments. If the cribriform plate has been fractured, great care must be exerted during proper insertion of the forceps and the gentle distraction process, so as not to further violate this critical area.

c. Techniques for Fracture Fixation

If the NOE fractures are unstable, requiring internal stabilization—particularly to maintain the proper intercanthal distance—then several fixation options are commonly used.

i. Internal Transnasal Wiring

Internal transnasal wiring can be applied after the medial canthal region has been exposed bilaterally. In the past, transnasal wiring was performed without necessarily exposing the bony fragments, with the wires tightened over skin buttons. This led to a high incidence of skin necrosis, so the preferred method currently is to use internal wiring.

Small holes are drilled adjacent to the anterior lacrimal crest and just superior to the posterior lacrimal crest, avoiding the lacrimal sac and common canaliculus. Stainless steel wire is then threaded through the holes, across the septum and back again to cerclage the NOE complex, tightening the wires after manual reduction to achieve the correct intercanthal distance. The wires will normally remain in place beneath the periosteum, unless they cause discomfort to the patient at a later date or become exposed.

ii. Low-Profile Miniplates

The more preferred method of fixating the NOE fractures is to apply low-profile miniplates to the fracture sites after reducing the fractures and achieving proper intercanthal distances. The area for plate attachment is small, so 2-4 hole plates are usually the surgeon's choice. The plates will be secured in place with short screws, and caution is taken not to drill the holes too deeply to jeopardize the region of the ethmoid fovea or the cribriform plate. Exposure is normally gained for plate application through either a gull-wing incision medial to the attachment of the medial canthi, or a coronal forehead approach. It is important to plan the exposure incision well away from the plate, to lessen the risk of plate exposure. The plates may be left in place, unless they cause discomfort to the patient in the future.

iii. Polymer Canalicular Tube

Reconstruction of a damaged lacrimal drainage system will likely require the insertion of a polymer canalicular tube (Figure 3.27).




Figure 3.27

Polymer canalicular tube stent for damaged lacrimal drainage system. Note the blunt metal tips for threading into canaliculi via the puncta.

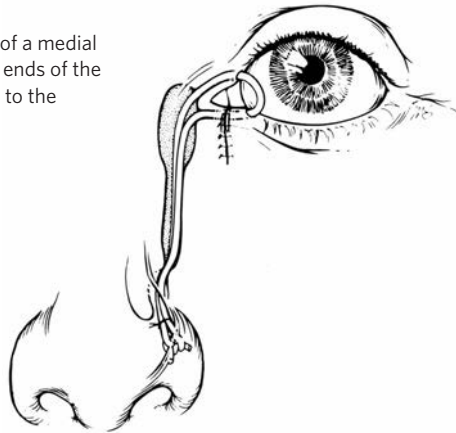
CHAPTER 3: Upper Facial Trauma

Each end will have a thin, blunt wire tip that can be inserted into the superior and inferior puncta, with the wires manipulated through the canaliculi into the lacrimal sac, and thence into the nasal cavity via the nasolacrimal duct and inferior meatus.

The wires are brought out the nares, cut free from the tubing, which is then tied into a series of knots and sutured inside the lateral nasal vestibule. This effectively creates a loop, with the loop portion connecting the two puncta, allowing the discontinuous lacrimal system to heal over the tubular stent, which can be left in place up to 6 weeks. If there are associated lacerations of the canaliculi from a vertical medial eyelid wound, then these can be repaired over the tubular stent with fine absorbable synthetic suture (Figure 3.28). If the reconstruction of the lacrimal system is unsuccessful, depending on the location of the blockage, an endoscopic dacryocystorhinostomy may be required in the future for unacceptable epiphora.

Figure 3.28

Lacrimal stent in place after repair of a medial canthal region laceration. Note the ends of the stent are tied together and sutured to the lateral nasal vestibule.



iv. Elevating the Periosteum and Identifying Entrapped Orbital Tissue

If there is a medial orbital wall fracture (lamina papyracea and ethmoid sinus complex), this area must be explored. Elevating the periosteum and identifying entrapped orbital tissue will normally be sufficient. It is important to recall that the anterior and posterior ethmoid arteries penetrate the lamina papyracea in mid-wall, and may need to be clipped or cauterized, preferably before they start bleeding. The optic foramen is located just behind the posterior ethmoid foramen, so care must be taken not to extend the exposure beyond this point in risk of damaging the optic nerve.

v. Self-Seal after Reduction of the Fractures

Most CSF leaks at the level of the cribriform plate will self-seal after reduction of the fractures. Consideration may also be given to placing the patient in the semi-upright position and inserting an epidural drain. For persistent leaks, an endoscopic approach to repair is usually successful.

H. PREVENTION AND MANAGEMENT OF COMPLICATIONS

1. Indications for Antibiotics

Indications for antibiotics include any fractures that violate the integrity of the nasal or sinus mucosa, cause a pathway from the sinuses to the orbit or intracranial contents, or are present in a CSF leak. Since clinicians disagree about the use of antibiotics in small CSF leaks, residents should discuss this subject with their attending otolaryngologists.

A broad-spectrum antibiotic should be chosen, which is effective against the usual nasal and sinus pathogens. Special consideration should be given to patients who have a history of chronic or recurrent sinusitis with respect to the potential presence of drug-resistant organisms.

Antibiotic coverage need not extend past 5–7 days, unless the wounds become infected or an acute ethmoid or frontal sinusitis is detected.

2. CSF Leaks

As discussed above in section II.B.2.g, most CSF leaks will spontaneously resolve after repair of the NOE fractures. However, it may be necessary to repair the defect with an endoscopic tissue patch, septal flap, or anterior cranial fossa approach to the cribriform plate region with a dural patch or pericranial flap. CSF rhinorrhea due to a posterior-inferior frontal sinus-displaced fracture may be treated by obliteration of osteoplastic frontal sinus fat.

3. Corneal Injuries

A corneal laceration as a result of the blunt trauma will normally be managed by the ophthalmologist, and could delay the repair of NOE injuries until the specialist is satisfied that the cornea is healing satisfactorily. Abrasions are less likely to delay the repairs, but the ophthalmologist will likely wish to protect the cornea from further, inadvertent injury during the surgical procedure. Typically this will be achieved by placing a corneal protector on the globe before the surgery and removing it at the end of the surgery. Even in the absence of any corneal

CHAPTER 3: Upper Facial Trauma

pathology, many surgeons prefer to apply a corneal protector for the security and safety of this tissue during fracture repair.

4. Lower Lid Abnormalities

Failure to adequately reconstitute the proper intercanthal distance through reduction and fixation of the bone to which the medial canthal tendons are attached can lead to lower eyelid laxity and ectropion. Depending on the severity of the ectropion, an additional lower lid shortening procedure may be required, with or without a medial canthal tendon tightening. Malposition of the medial canthus can also be a complication of poor repositioning of NOE fractures (Figure 3.29). Adequate time for healing and tissue firming should be allowed before recommending these procedures.

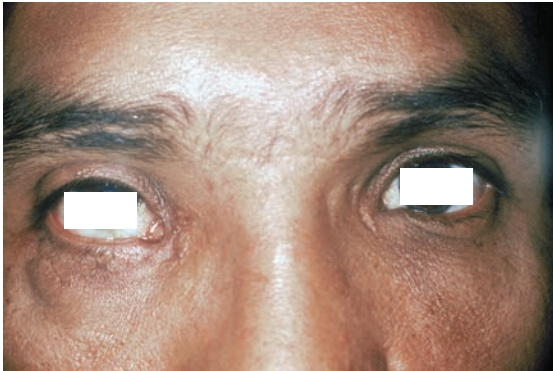


Figure 3.29

Malpositioned right medial canthus, with persistent right traumatic telecanthus and chronic epiphora due to eversion of the inferior punctum.

5. Persistent Telecanthus

One particularly common and troublesome complication is the inadequate reduction and fixation of the NOE fractures, leading to a persistently widened intercanthal distance and an unpleasant appearance to this area of the face. In a few patients, this could actually be a “pseudo-telecanthus,” where persistent soft tissue edema and scarring have given the appearance of a telecanthus.

A trial of gentle massage over time as well as consideration for steroid injections into the soft tissue (away from the canthal tendons) may be successful. If the telecanthus is due to inadequate narrowing of the NOE complex, then consideration can be given to the performance of osteotomies, reduction, and refixation. Because this procedure is difficult, the surgeon should have experience in its conduct.

6. Failure to Correct Medial Orbital Tissue Entrapment

Normally, exposing the medial orbital blowout fracture and releasing the tissue from entrapment will be sufficient to prevent subsequent fat

necrosis or persistent diplopia. However, for a large defect in the lamina papyracea, it may be helpful to insert a soft tissue graft, such as temporalis fascia “tucked” between the orbital periosteum and the defect, to prevent future internal prolapse. If entrapment persists after initial reduction, a repeat CT scan of the facial skeleton with soft tissue window may indicate the extent of tissue entrapment. A repeat exploration and repair may be indicated.

7. Persistent Diplopia

Diplopia that was present preoperatively due to entrapment may persist for several weeks to months post-repair, owing to persistent edema of the medial orbital structures and the contraction of scar tissue. If the diplopia persists, then inadequately reduced entrapment may be present (see section II.H.6, above), or there may be an undiagnosed neurological injury to the oculomotor nerve or trochlear nerve.

The patient should be evaluated by a neuro-ophthalmologist. Neuropraxia should clear within several months, but a more serious nerve injury may not recover, and ocular muscle surgery might be required. If it can be determined that the trochlear attachment of the superior oblique muscle tendon has been disrupted from its osseous connection, then exploration, in conjunction with an ophthalmologist, to reattach the trochlea to the superior-medial orbital wall, may be indicated. This can be accomplished through a Lynch-type incision.

8. Anosmia

If anosmia is present after the injury, it is likely due to either a cribriform plate fracture or a contrecoup injury to the olfactory tracts. It is highly unlikely that it will improve over time. Anosmia is typically an “all or none” recovery phenomenon. However, other less likely etiologies should be investigated—obstructive scarring in the superior nasal vault, foreign body reaction (wire or screws), excessive mucosal edema, fractured/dislocated septum, and nasal polyps.

9. Frontoethmoid Sinusitis

Owing to the potential extensive disruption of the ostia of the frontal and ethmoid sinuses with NOE fractures, sinus aeration and the development of a chronic sinusitis are not uncommon. Additionally, the lamellae of the ethmoid sinuses are typically crushed in the NOE fractures, which may well result in sequestration, infection, and mucopyocele. These conditions will be obvious on follow-up fine-cut CT scans and should be appropriately addressed medically and surgically.

CHAPTER 3: Upper Facial Trauma

The frontal sinus floor and immediate surrounding inferior portion is at high risk for injury in NOE fractures, which can result in trapped, inspissated mucus, and the development of a mucopyocele. Because of their proximity to the anterior cranial cavity, such infections can spread to the dura and intracranially, causing meningitis and frontal lobe abscess. If the frontal sinus is not obliterated, as indicated due to displaced posterior-inferior wall fractures, then frequent follow-up of the patient is important to identify the early formation of poor sinus drainage and pending serious complications.

III. Summary and Conclusion

A. FRONTAL SINUS AND ANTERIOR SKULL BASE TRAUMA

Frontal sinus fractures are uncommon, and the victims of these injuries are exposed to a significant traumatic impact. The fractures are often multiple, and a treatment algorithm that addresses each wall and type of fracture, such as that presented in this chapter, is recommended. An acute awareness of the potential complications of entrapped and damaged mucosa necessitates careful management of these injuries.

B. NOE FRACTURES

NOE fractures and associated injuries are usually due to blunt trauma, and are associated with other facial or head injuries.

The patient is initially evaluated by the trauma team and, when cleared, can be further evaluated by the otolaryngologist, often in consultation with the ophthalmologist. NOE trauma can involve the medial orbit, ethmoid vessels and nerves, cribriform plate, medial canthal region, nasolacrimal drainage system, ethmoid and frontal sinuses, perpendicular plate of the septum, anterior skull base, and nasal bones. Appropriate imaging studies are required after a thorough head and neck and neurological examination.

Complications can include traumatic telecanthus; visual disturbances, including diplopia; compression and splaying of the NOE bony complex; ethmoid artery bleeding; entrapped medial orbital contents; fractures of the sinus complexes, including the ostia; CSF rhinorrhea; anosmia; and discontinuity of the nasolacrimal drainage system.

Repair and reconstruction goals are to re-establish normal intercanthal distances and nasal root projection, release any entrapped medial orbital tissues, protect the globe and optic nerve, properly fixate the medial canthal tendons, stop bleeding, stop CSF leak, ensure a patent nasal airway, and address ethmoid and frontal sinus fractures.

Serious issues involving the orbital structures can best be managed in conjunction with the consultant ophthalmologist.

IV. References

1. Nahum AM. The biomechanics of maxillofacial trauma. *Clinical Plastic Surgery*. 1975;2:59.
2. Lang J. Paranasal sinuses. In: Lang J. *Clinical Anatomy of the Nose, Nasal Cavity and Paranasal Sinuses*. New York, NY: Thieme Medical Publishers, Inc.; 1989:63.
3. Fenton WH, Donald PJ, Carlton W. The pressure exerted by mucoceles in the frontal sinus. *Archives of Otolaryngology*. 1990;116:836-840.
4. Lawson W. Frontal sinus. In: Blitzer A, Lawson W, Friedman WH, eds. *Surgery of the Paranasal Sinuses*. Philadelphia, PA: WB Saunders; 1985:120-148.
5. Draf W. Endonasal micro-endoscopic frontal sinus surgery: The Fulda concept. *Operative Tech Otolaryngol Head Neck Surg*. 1991;2:234-240.
6. Donald PJ, Bernstein L. Compound frontal sinus injuries with intracranial penetration. *Laryngoscope*. 1978;88:225-232
7. Merville LC, Derome PJ. Concomittant dislocations of the face and skull. *J Maxillofac Surg*. 1978;6(1):2-14.

V. Recommended Reading

Holt GR, Holt JE. Incidence of eye injuries in facial fractures: An analysis of 727 cases. *Otolaryngol Head Neck Surg*. 1983;91:276-279.

Imahara SD, Hopper RA, Wang J, Rivara FP, Klein MB. Patterns and outcomes of pediatric facial fractures in the US: A survey of the National Trauma Data Bank. *J Am Coll Surg*. 2008;207(5):710-716.

Mazzoli RA, Ainbinder DJ, Hansen EA. Orbital trauma. Chapter 20 in: Thach AB, ed. *Ophthalmic Care of the Combat Casualty*. Fort Detrick, MD: U.S. Army Borden Institute; 2003. Accessed at: http://www.bordeninstitute.army.mil/published_volumes/ophthalmic/OPHch20.pdf.

Nguyen M, Koshy JC, Hollier LH Jr. Pearls of naso-orbital-ethmoid trauma management. *Semin Plast Surg*. 2010;24(4):383-388.

Vora NM, Fedok FG. Management of the central nasal support complex in naso-orbital ethmoid fractures. *Facial Plast Surg*. 2000;16(2):181-191.

The American Academy of Otolaryngology—Head and Neck Surgery Foundation’s education initiatives are aimed at increasing the quality of patient outcomes through knowledgeable, competent, and professional physicians. The goals of education are to provide activities and services for practicing otolaryngologists, physicians-in-training, and non-otolaryngologist health professionals.

The Foundation’s AcademyU® serves as the primary resource for otolaryngology-head and neck activities and events. These include an online library of expert-developed learning courses, learning platforms, and e-books, as well as Patient Management Perspectives in Otolaryngology and the Home Study Course. In addition, the AAO-HNSF Annual Meeting & OTO EXPO is the world’s largest gathering of otolaryngologists, offering a variety of education seminars, courses, and posters. Many of the Foundation’s activities are available for *AMA PRA Category 1 Credit*™.

Visit the Academy’s Web site, www.entnet.org, to find out how AcademyU® can assist you and your practice through quality professional development opportunities.



AMERICAN ACADEMY OF
OTOLARYNGOLOGY—
HEAD AND NECK SURGERY

F O U N D A T I O N

**American Academy of Otolaryngology—Head and Neck
Surgery Foundation**

**1650 Diagonal Road
Alexandria, VA 22314-2857 USA**

T / 1.703.836.4444

F / 1.703.683.5100

www.entnet.org